De fire væv
- funktionel anatomi
-
1 sem

1. sep 2025

AARHUS
UNIVERSITET
INSTITUT FOR ODONTOLOGI OG ORAL SUNDHED

HENRIK LØVSCHALL
LEKTOR, PHD, TANDLÆGE

VÆV

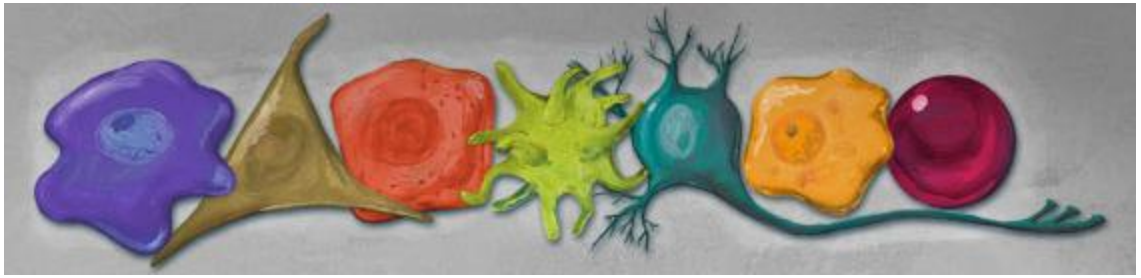

Anatomisk afsnit, TA
Henrik Løvschall

Væv

- Anatomi begynder med funktionel anatomi

- Organismen har fire store vævsgrupper: epitel, støttevæv, muskelvæv og nervevæv.

- Lidt viden om væv, gør det muligt at
  - forstå finere anatomiske strukturer som fx vævslag i kinden, læben, fordøjelsessystemet osv (mikroanatomi)
  - forstå funktion i hjerte, kar, nyre, lever osv (funktionel anatomi)

Kroppens organer er opbygget af 4 vævstyper

Inddeling:

- Epitel
- Støttevæv
- Muskelvæv
- Nervevæv

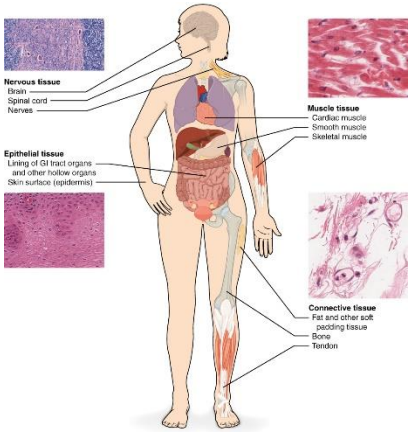

Regents of University of Michigan Medical School

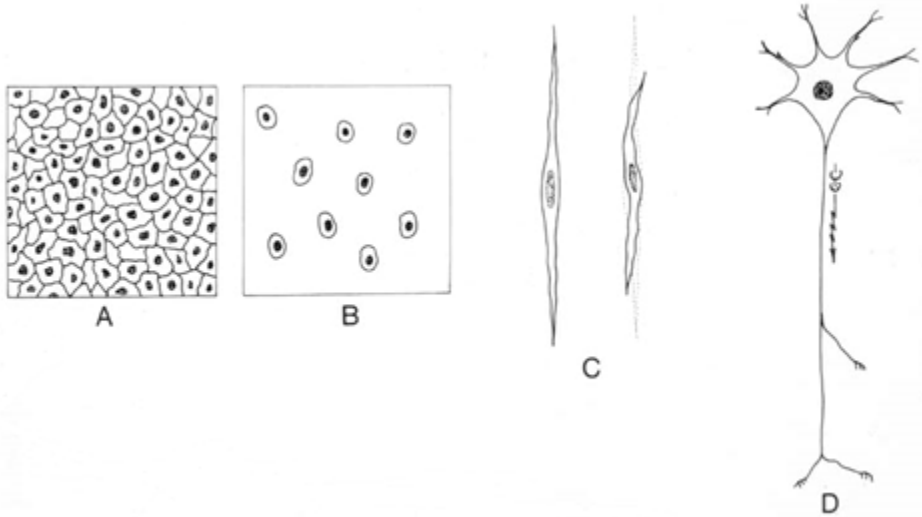

EPITEL

- tætlejrede celler
- forskellige celleformer

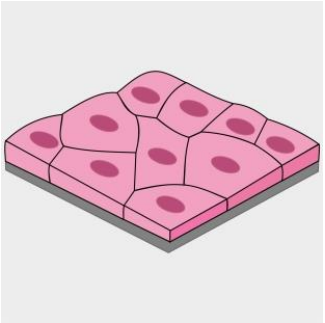

- beklæder overflader i et eller flere lag
- kan producerer sekret

Inddeling:

- dækepitel
- kirtelepitel

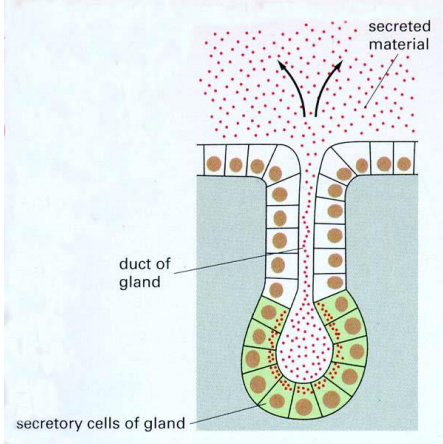

NERVEVÆV

- veludviklet ledningsevne

Inddeling:

- Neuroner
- Støttevæv

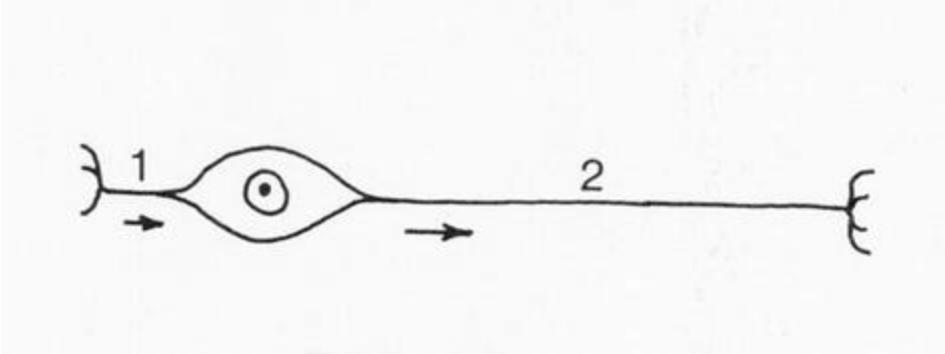

STØTTEVÆV

- få celler
- meget matrix/grundsubstans og fibriller

Inddeling:

- **b**indevæv
- **b**ruskvæv
- **b**envæv
- **b**lod og lymfe

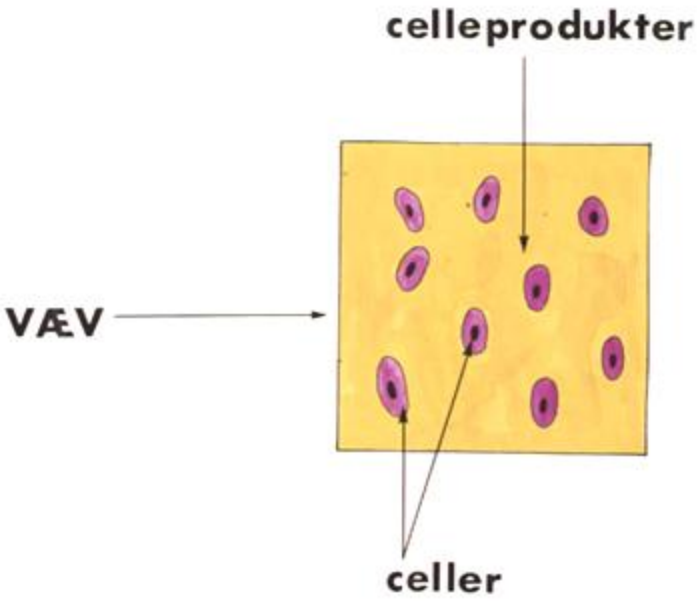

MUSKELVÆV

- evne til kontraktion

Inddeling:

- glat muskulatur
- tværstribet muskulatur
- hjertemuskulatur

Peer feedback øvelse

Inddel væv

- generelt i 4 hovedtyper
- støttevæv i 4 typer
- epitel i 2 hovedtyper

Peerfedback 2 og 2 - evt 3

Inddeling af vævstyper				
Nævn muskler i halsens 3 lag (3)				
Støttevæv (4 typer)				
Støttevæv (4 typer)				
Muskelvæv (3 typer)				
Epitel hovedtyper (2 typer)				

EPITEL
- vævslære

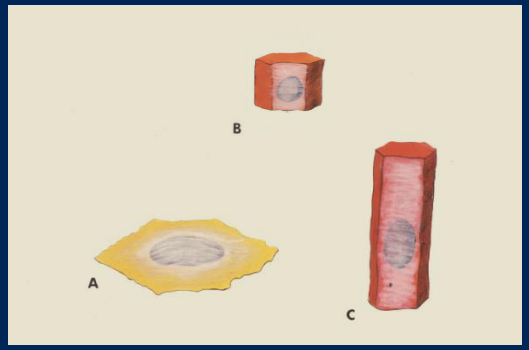

AARHUS
UNIVERSITET
INSTITUT FOR ODONTOLOGI OG ORAL SUNDHED

Dækepitel beskytter

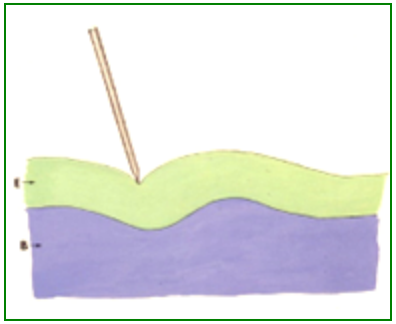

- Beskytter det underliggende bindevæv mod udefrakommende irritamenter

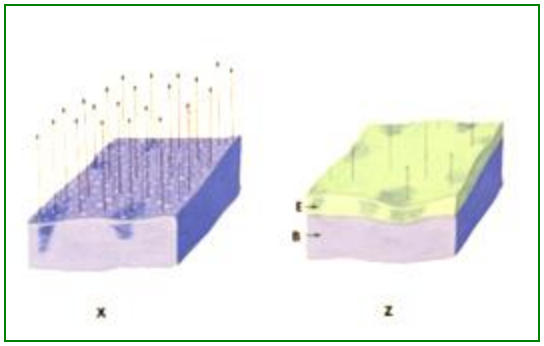

- Beskytter mod:
  - bakterier
  - mekaniske og termiske påvirkninger
  - væsketab

Dækepitel er på overflader

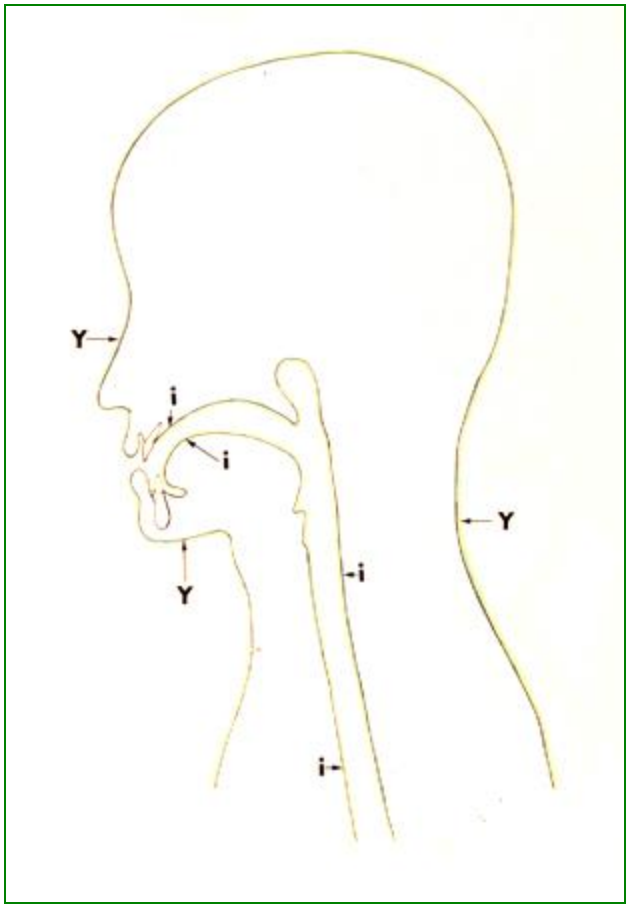

- Dækepitel beklæder og beskytter kroppens ydre og indre overflader
- Der er ingen sammenvoksning
  - fx i spiserøret
- NB: dækepitel mangler dog i ledhuler og seneskeder

Epitel kan absorbere væske og opløste stoffer

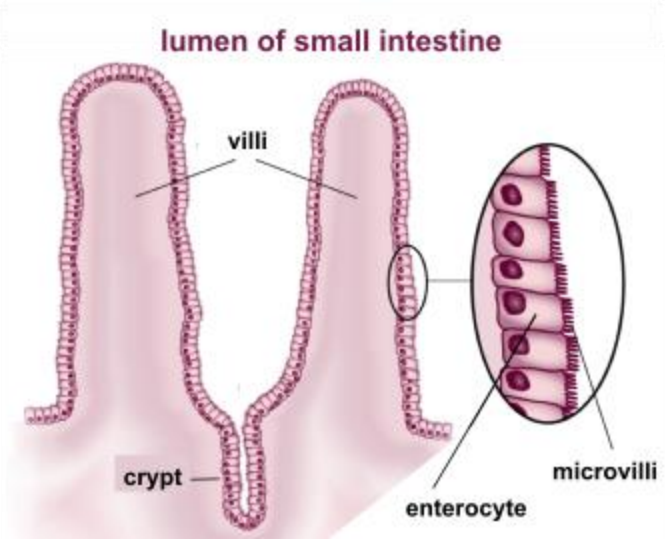

- tarmenes epitelbeklædning er særlig velegnet til absorption.

©

Smagsløg indeholder forskellige smagsceller og mange nervetråde

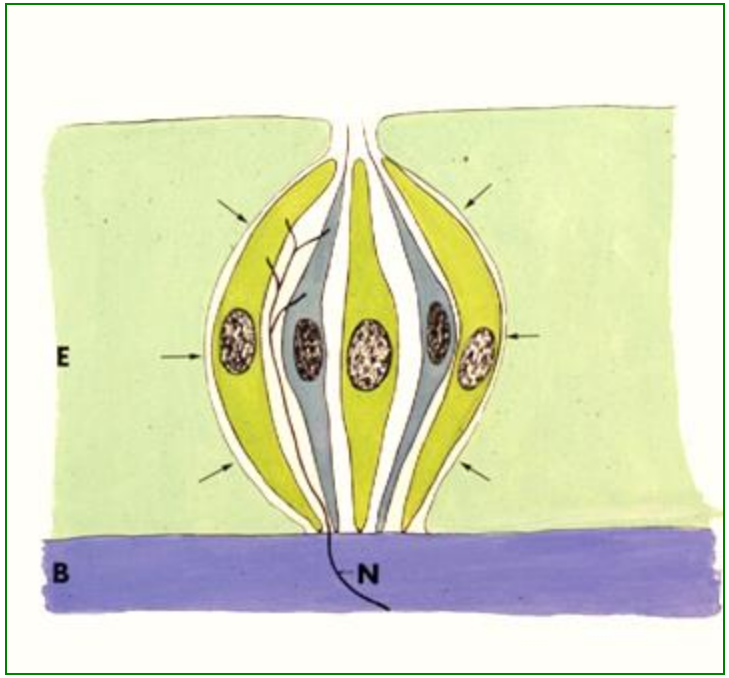

- smagsløg hvor (N) er en nervetråd, der løber op i smagsløget.

Bindevæv nedenunder

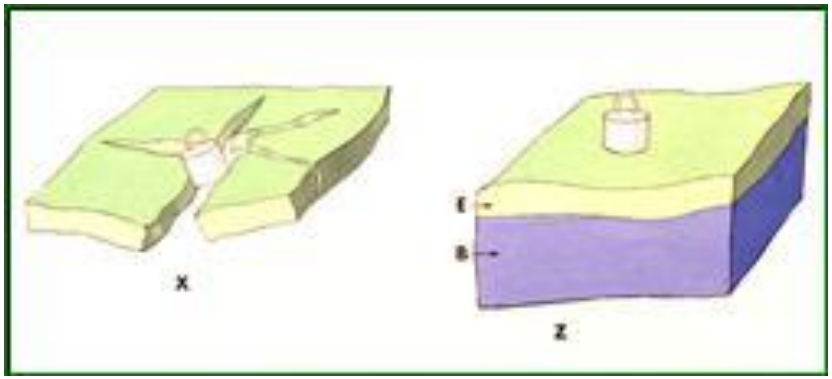

- Epitel kan ikke modstå tryk, medmindre der er bindevæv nedenunder

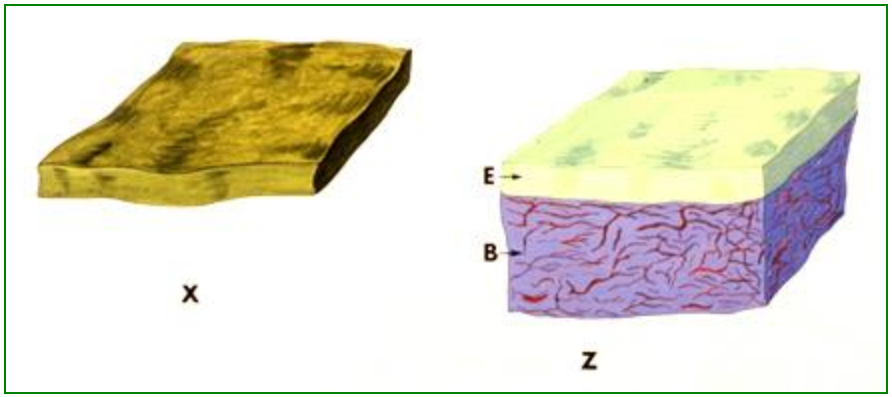

- bindevævet indeholder kar, der ernærer epitelet

Epitelceller hænger sammen

- i tætte lag på overflader,- som de beskytter

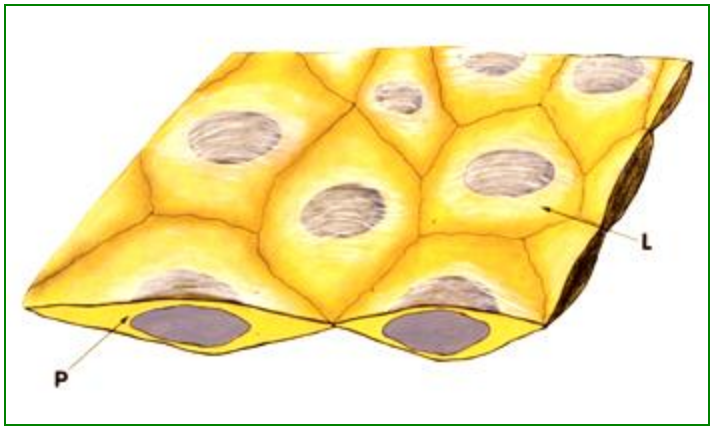

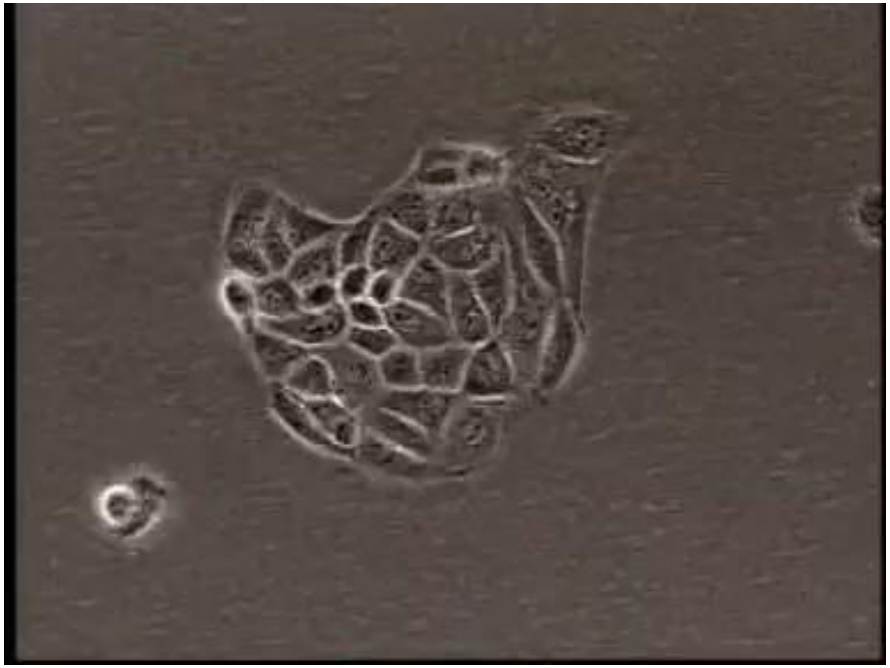

/Epitel hænger sammen pga stærke molekylære strukturer i cellemembran

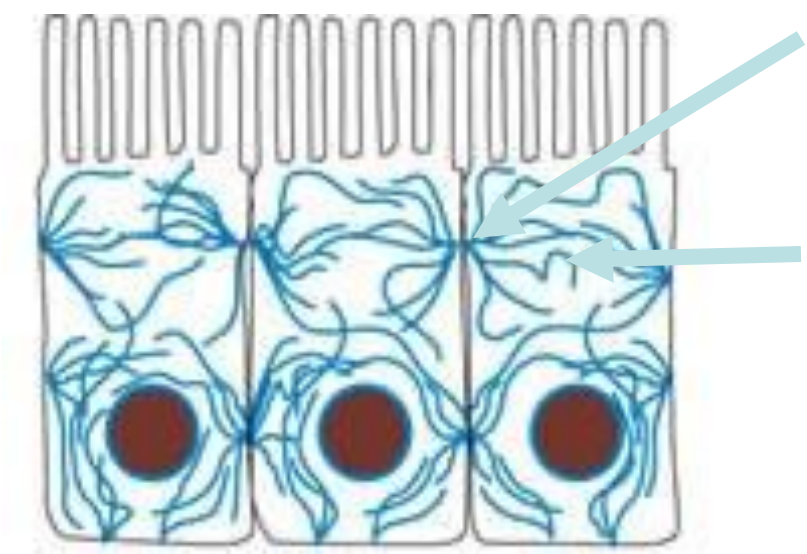

- forbindelser i mellem celler:
  - **desmosomer**
- forbindelser indad i cellen
  - til cytoskelettets **intermediære filamenter**

http://www.accessexcellence.org/AB/GG/cytoSkeleton.html

/Desmosom

- To **hemi-desmosomer** danner et desmosom, der binder to celler sammen

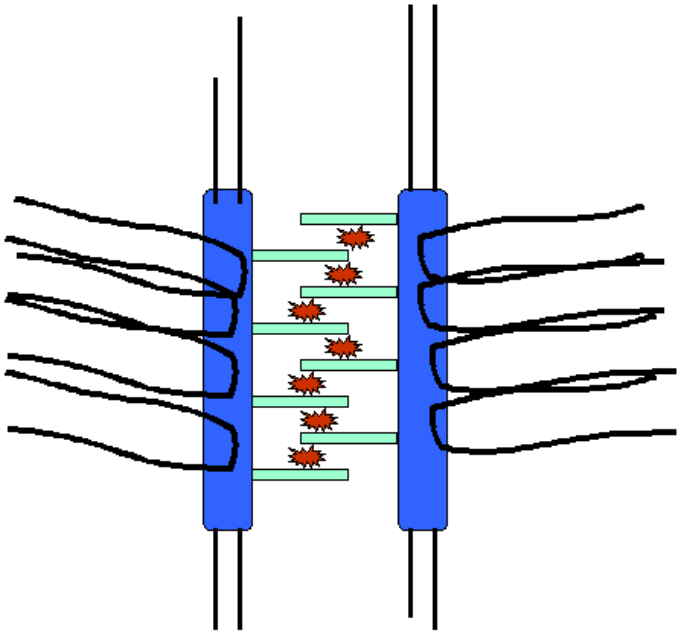

Intermediære filamenter

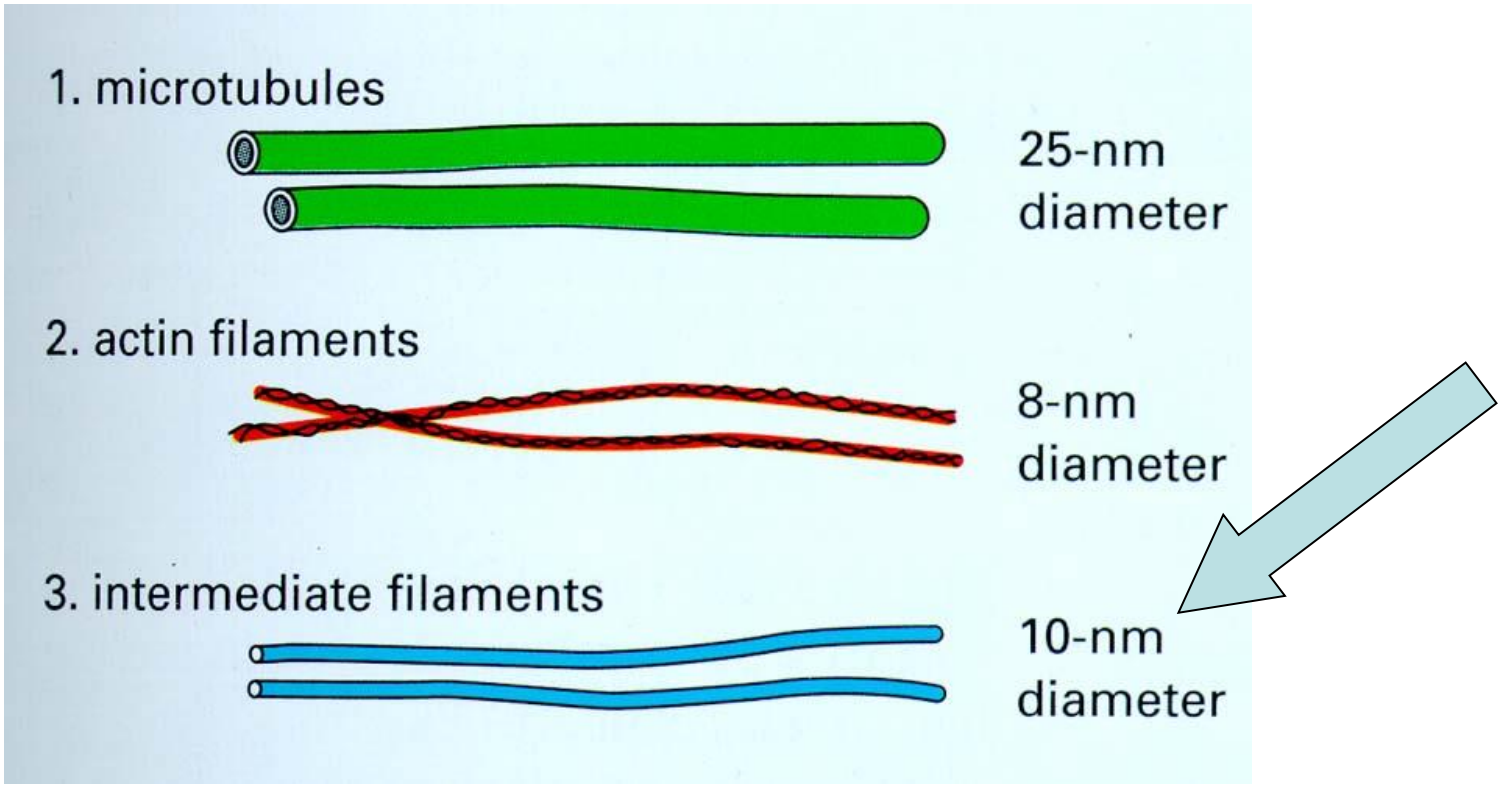

- Se evt ‘cellen – en introduktion’

Epitel har forskellige funktioner

- beskyttelse
- sekretion
- absorption
- sensitive bifunktioner

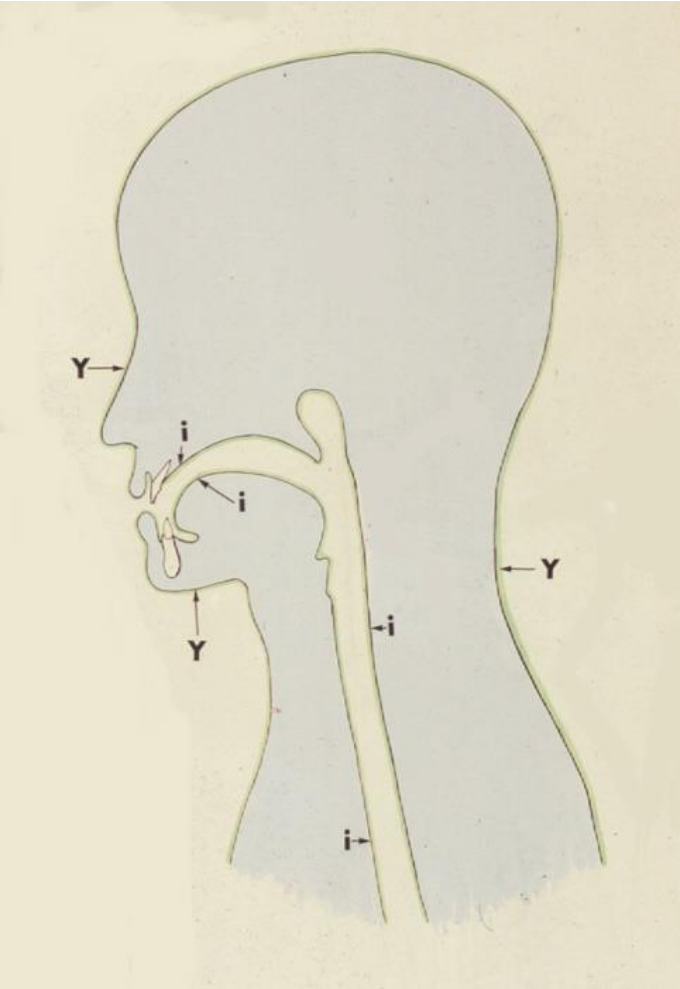

Epitelcellers form

A Pladeformet

B Kubisk

C Prismatisk

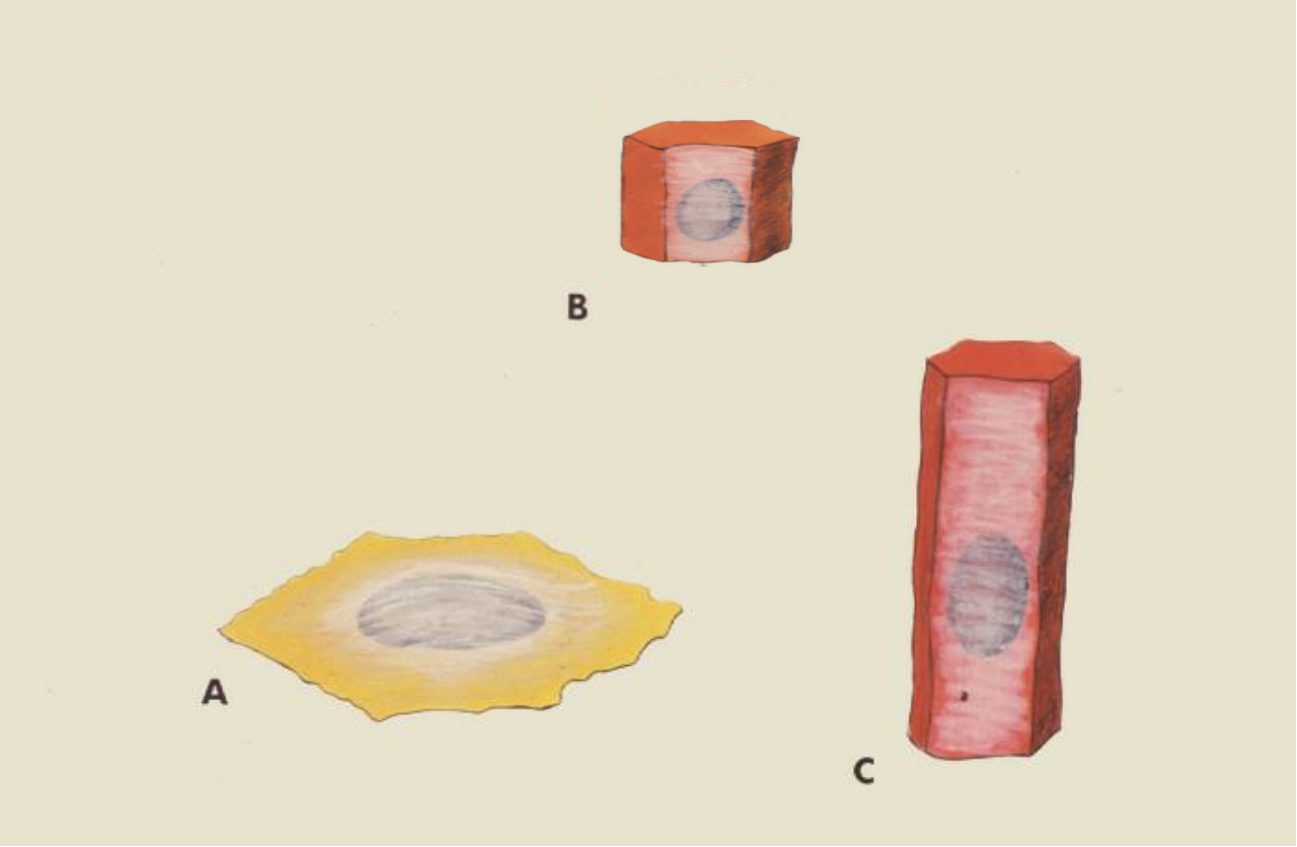

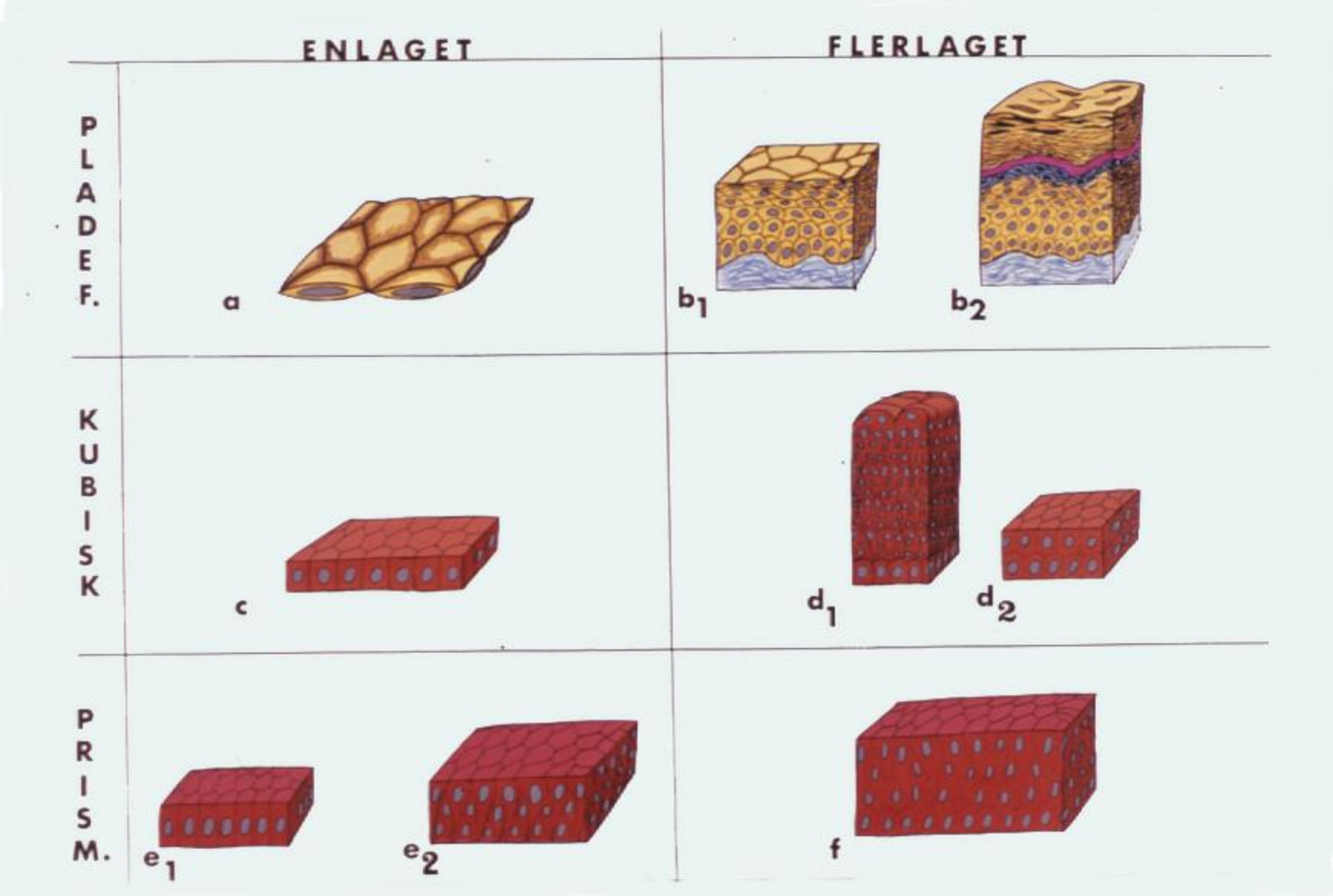
ENLAGET
FLERLAGET
PLADEF.
KUBISK
PRISM.
a
b1
b2
c
d1
d2
e1
e2
f

Flerlaget pladeepitel

- pladeformede i overfladen
- prismatiske/kubiske i dybere lag

uforhornet

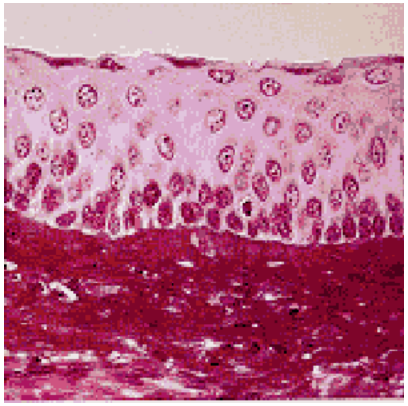

forhornet

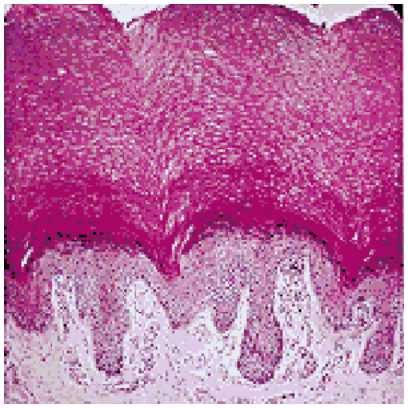

Enlaget pladeepitel

- flade celler med uregelmæssige kanter
- som fliser på et gulv
- **endotel**
  - blodkar
  - hjerte
  - lymfekar
- **mesotel**
  - i bughinden
  - andre serøse hinder

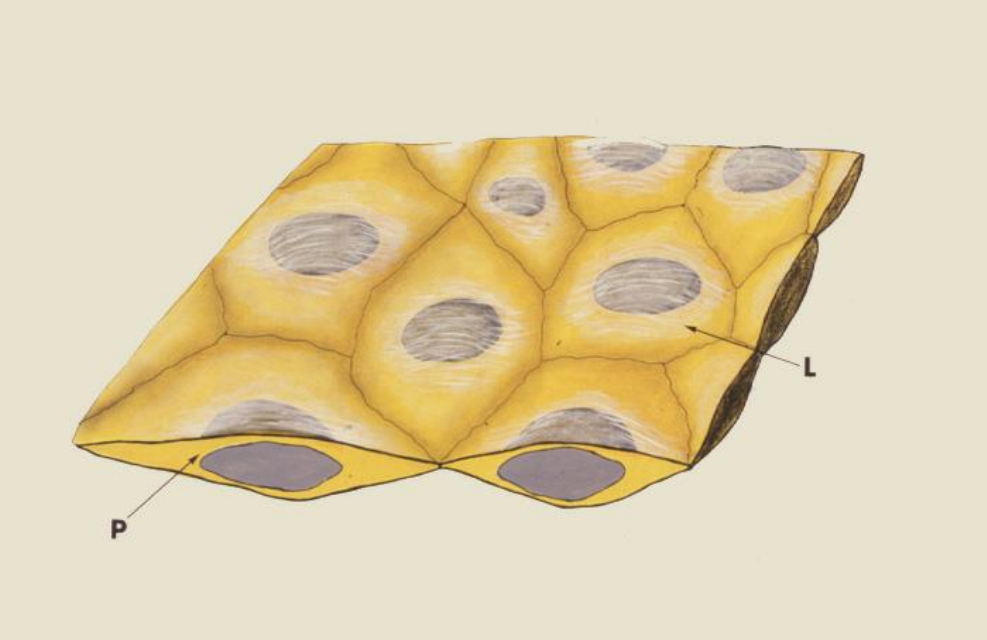

Alle epitelcellelag har en basalmembran

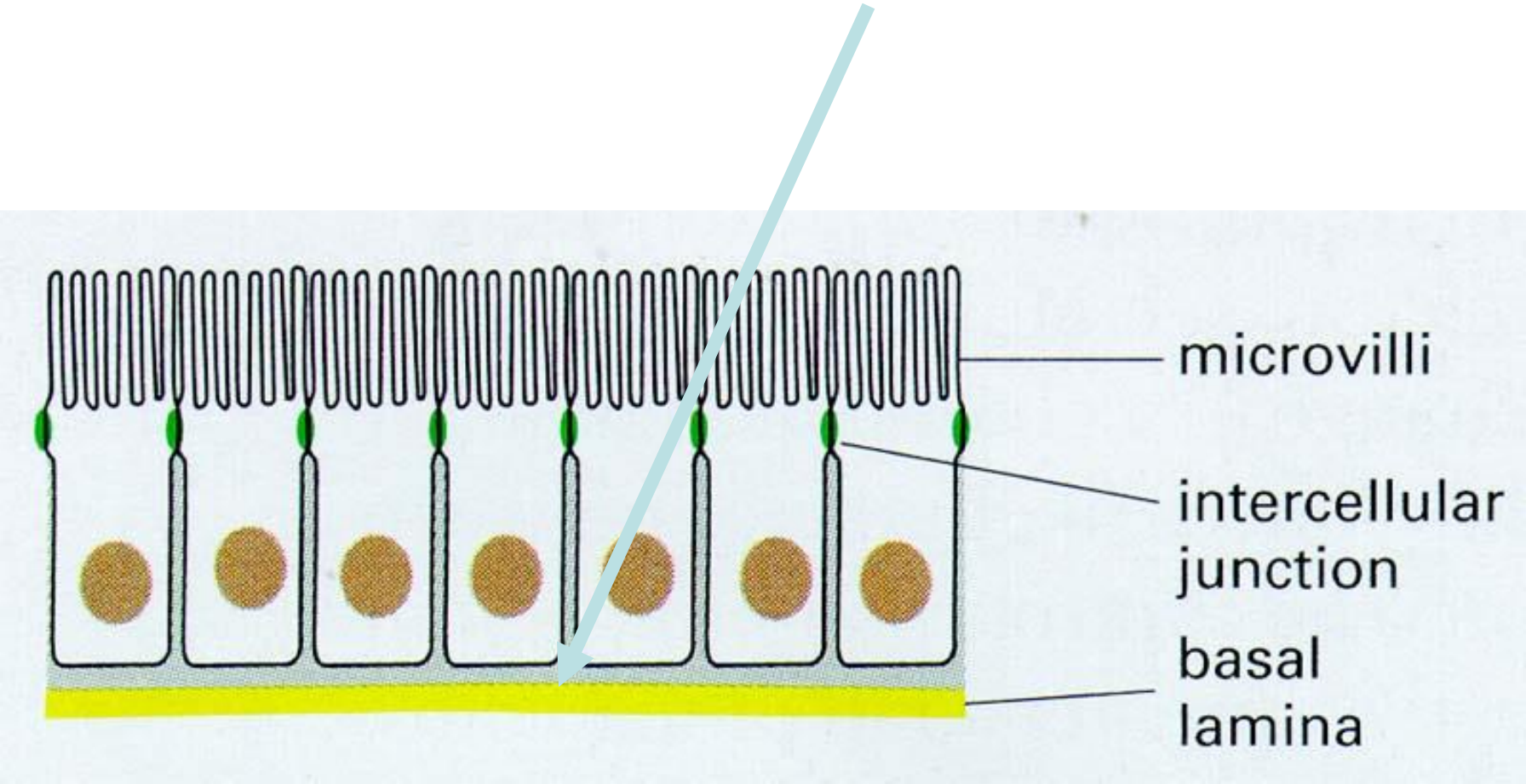

Flerlaget pladeepitel med forhorning

- cellerne deler sig og skubbes opad
- rest-keratin mv bliver ophobet

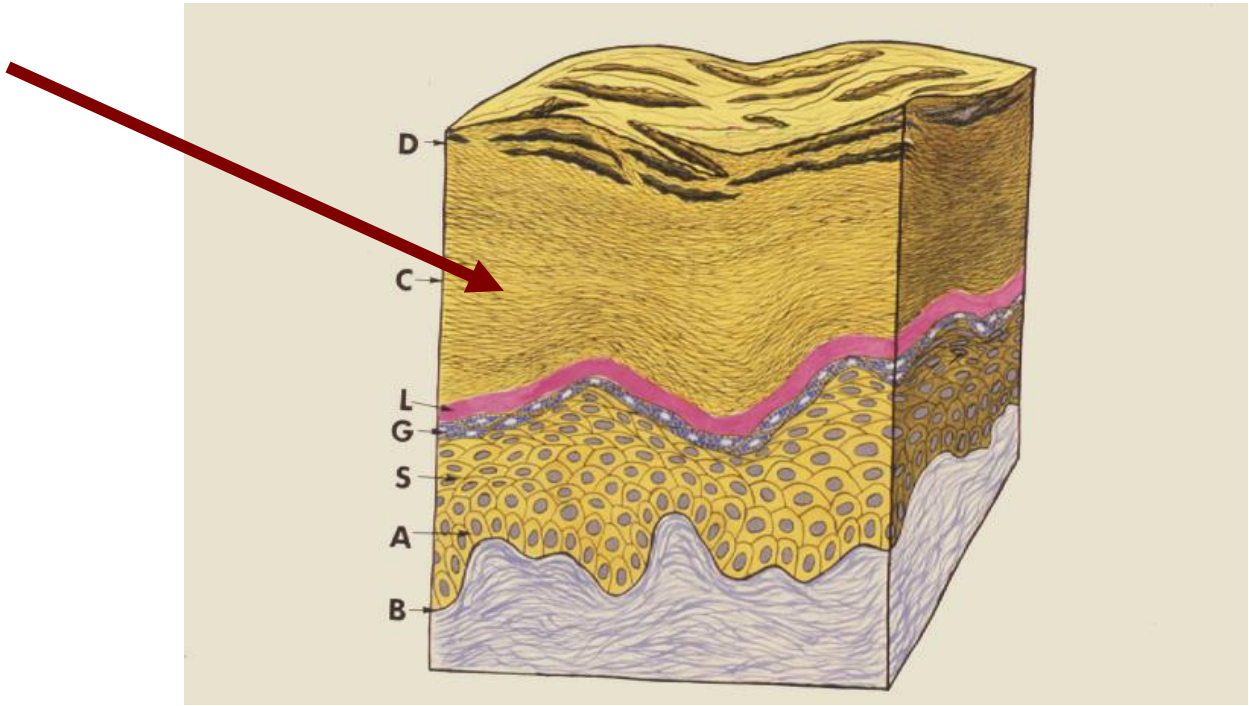

Flerlaget pladeepitel uden forhorning

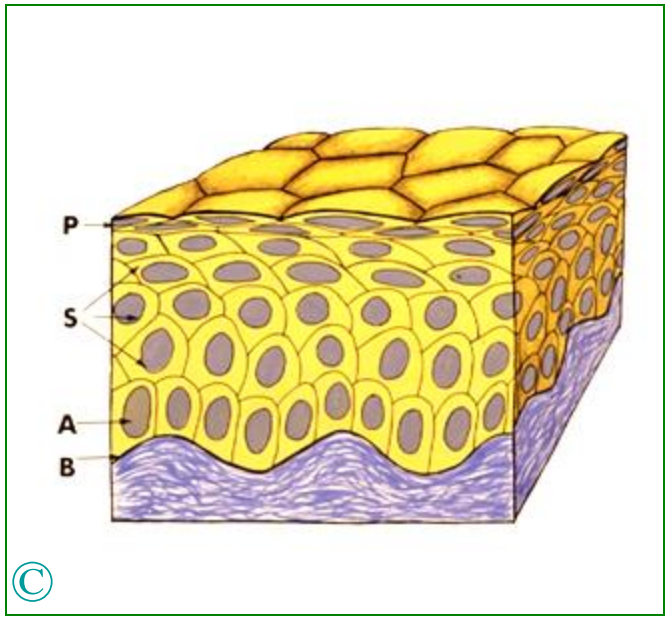

- findes fx i mundhulen, spiserøret og dele af svælget

Kubisk epitel

- enlaget terningelignende celler i kirtelgange (A)
- flerlaget <u>overgangsepitel</u> i urinblæren (B)

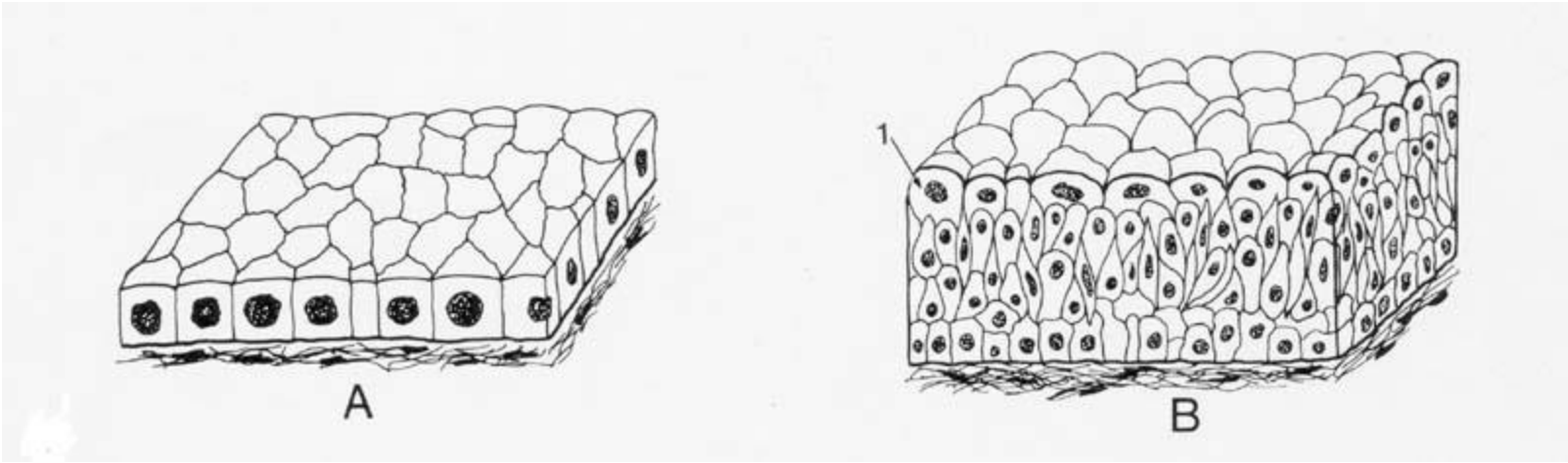

Prismatisk epitel

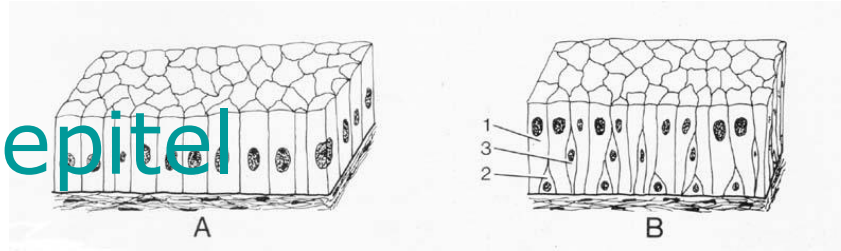

<u>A enlaget og enradet</u>

- højde større end bredde
- kerner ligger ud for hinanden

<u>B enlaget og flerradet</u>

- alle celler når basalmembranen
- celler har forskellige højde
- kernerække i forskellig højde

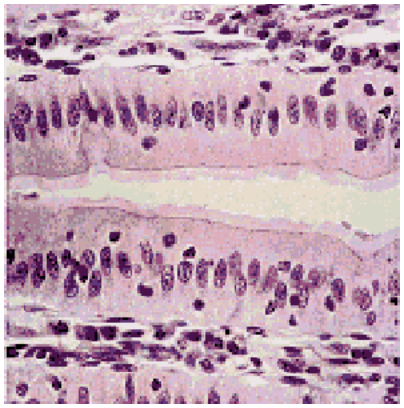

tyndtarmepitel

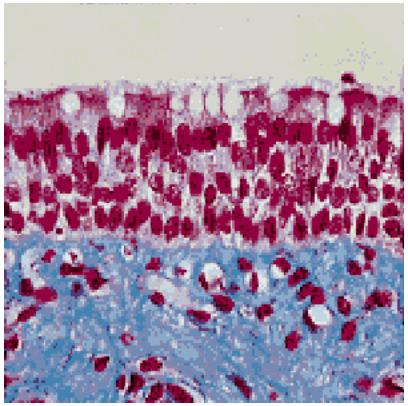

luftvejsepitel

Dækepitel - typer

Pladeepitel	
– enlaget	
– flerlaget	uforhornet/forhornet
Kubisk epitel	
– enlaget	
– flerlaget	overgangsepitel
Prismatisk epitel	
– enlaget	enradet/flerradet
– flerlaget	(sjældent)

Luftvejsepitel



- enlaget flerradet prismatisk epitel
- har også fimrehår (kinocilier), som er ansvarlige for transport henover overfladen

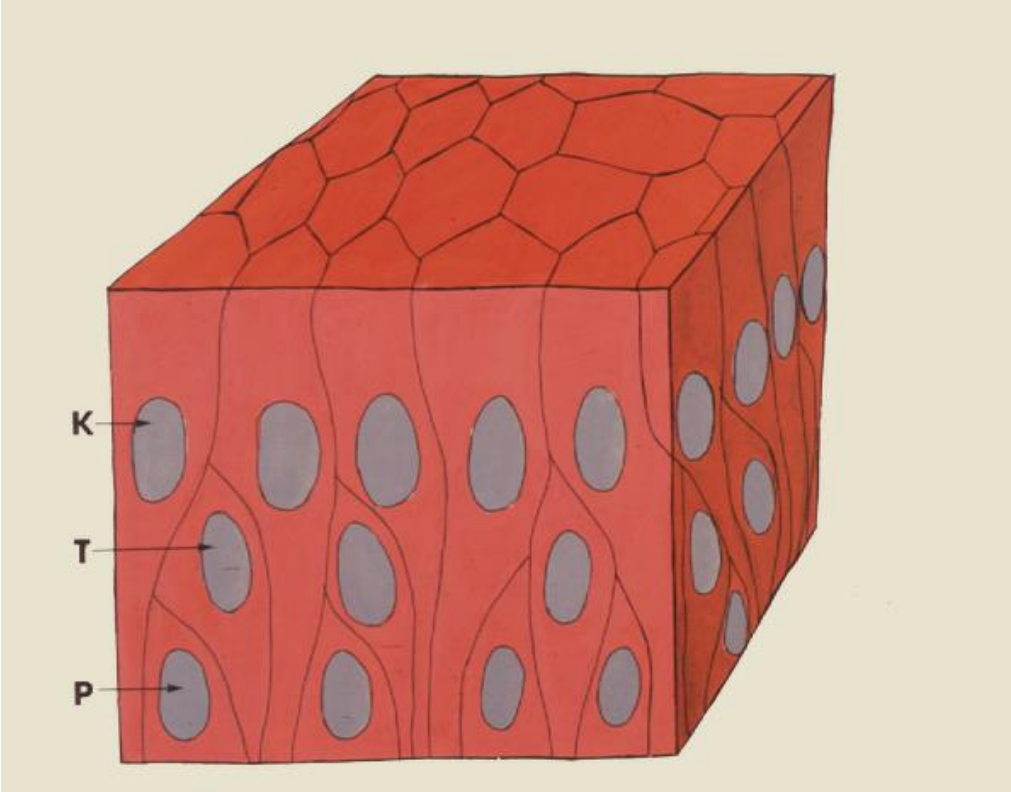

Cytoplasmaudløbere

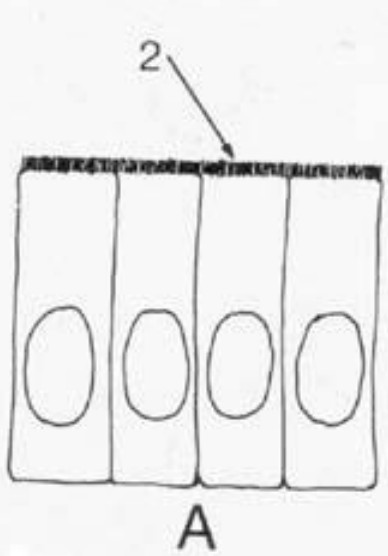

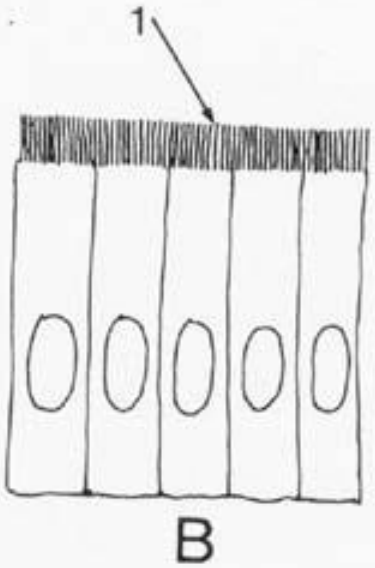

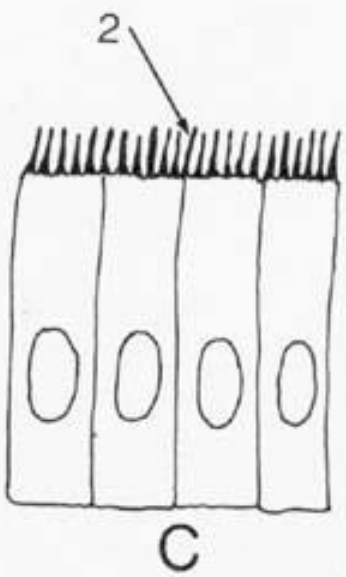

Mikrovilli (resorption) fx i tarm

Kinocilier (fimrehår) i luftveje

Stereocilier (udløber) i Cortiske organ

Smagsstift (”sansehår”) i smagsløg

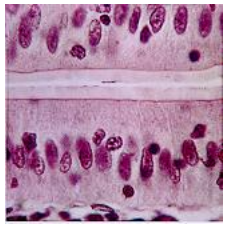

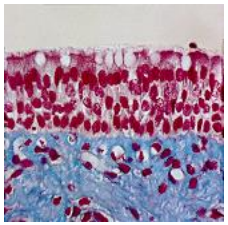

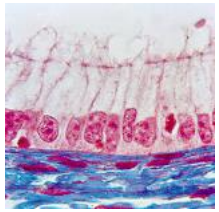

Væv
- peer feedback

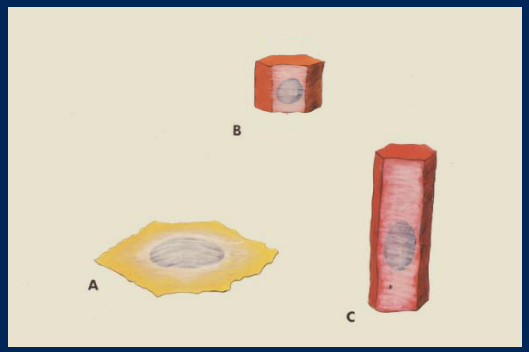

AARHUS
UNIVERSITET
INSTITUT FOR ODONTOLOGI OG ORAL SUNDHED

Peer feedback øvelse

Inddel væv

- epitel i 2 hovedtyper
- dækepitel i
  - antal lag
  - celleform
  - cytoplasmaudløbere / overflade

EPITEL:
•dækepitel
•kirtelepitel

KIRTELEPITEL

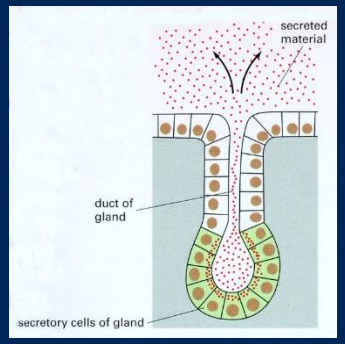

AARHUS UNIVERSITET
INSTITUT FOR ODONTOLOGI OG ORAL SUNDHED

HENRIK LØVSCHALL
LEKTOR, PHD, TANDLÆGE

Kirtelepitel

UDFØRSELSGANG

SEKRETORISKE CELLER

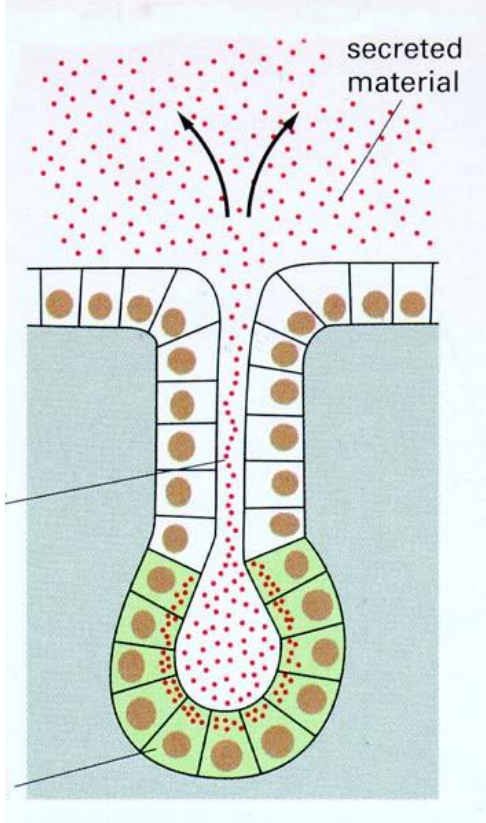

Kirteltyper

<u>Eksokrine</u>

– tømmes på overflade
(fx spytkirtler)

<u>Endokrine</u>

– tømmes i blodet
(fx hypofyse)

<u>Ekso- & endokrine</u>

– gør begge dele
(fx bugspytkirtel)

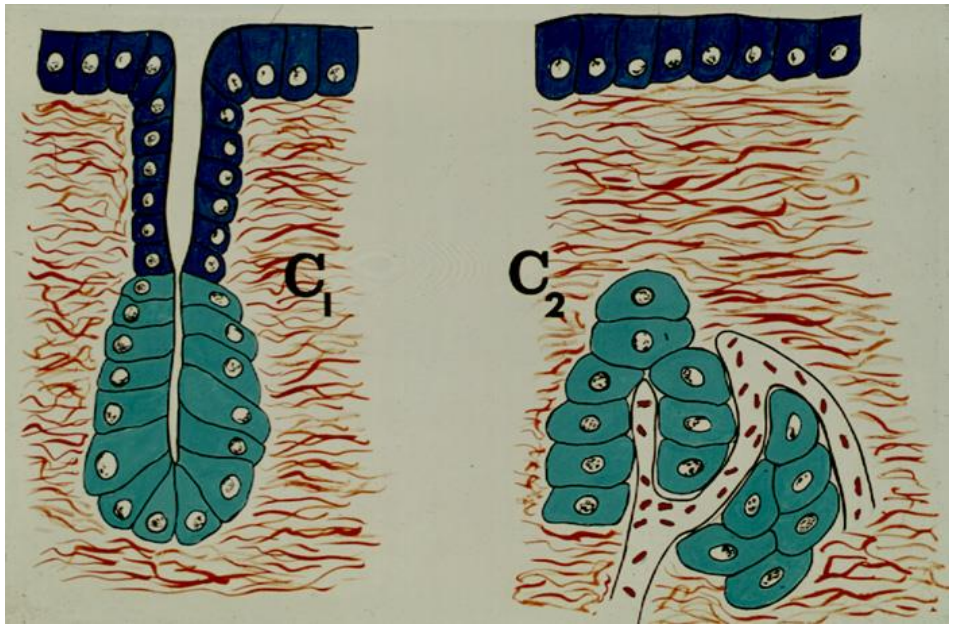

Endokrine kirtler

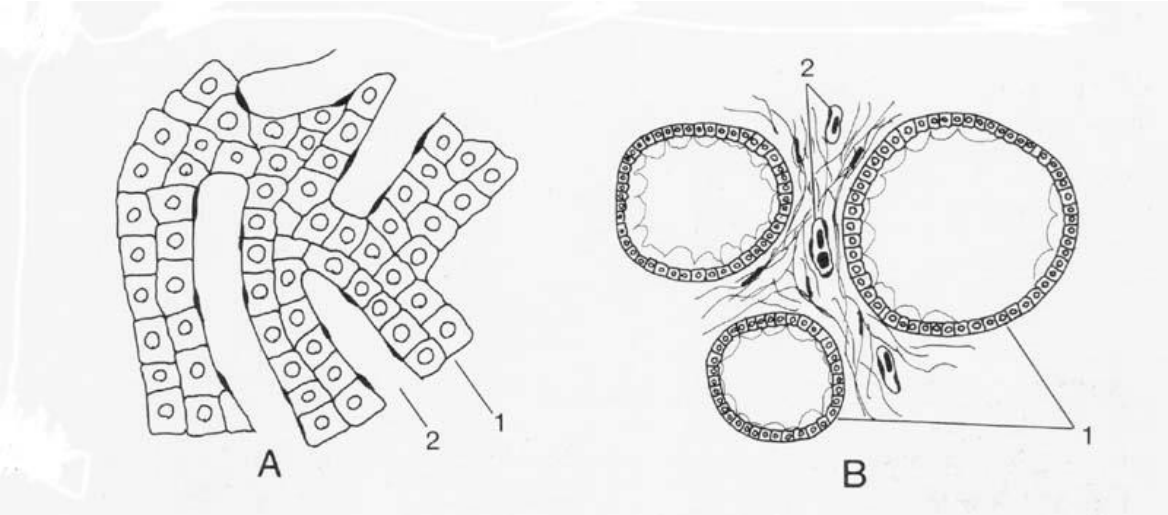

A trabekulære

endokrine kirtler danner epitelstrenge i et net med kapillærer

B follikulære

endokrine kirtler danner sække med sekret uden udførselsåbninger omgivet af bindevæv

Eksokrine kirtler

Unicellulære

– bægerceller)

(fx i luftveje og tarm)

Multicellulære

(resterende kirtler)

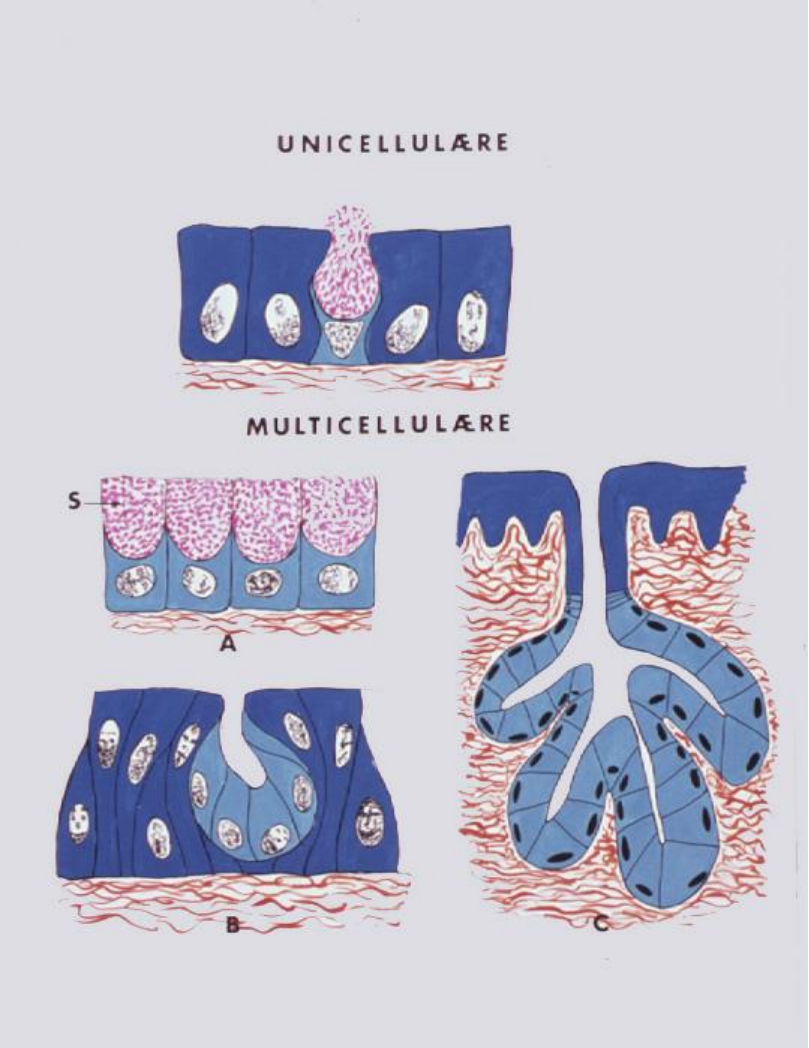

Endestykke (acinus)

- rør-formet — tubulært
- drue-formet — alveolært
- rør-drue-formet — tubulo-alveolært

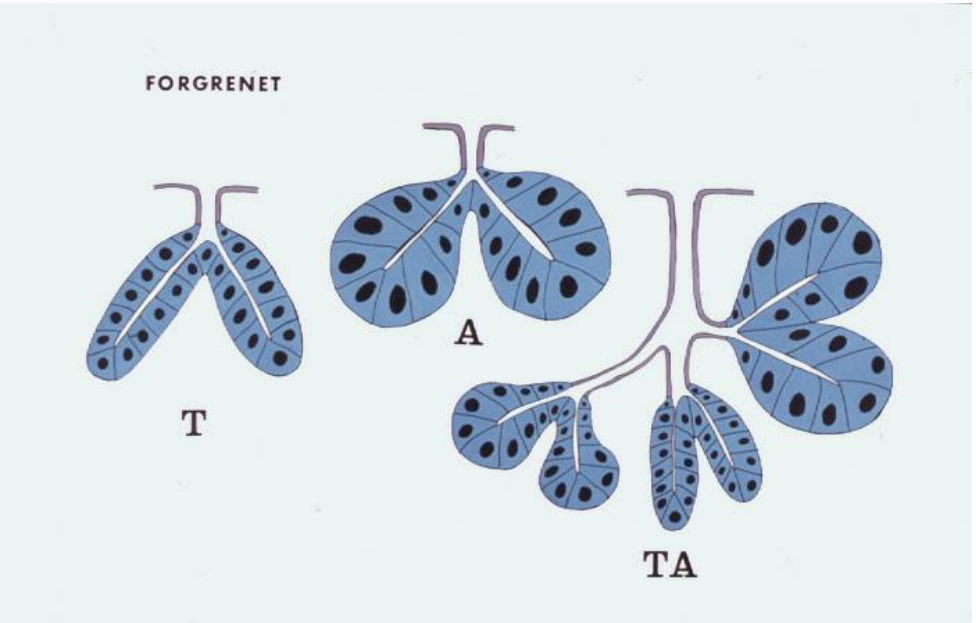

Lobulus

- enhed bestående af <u>udførselsgange</u>
- og tilhørende <u>endestykker</u>
- 1-20 mm

Sekretets art:

- serøst vandigt
- mucøst slimet

Endestykker:

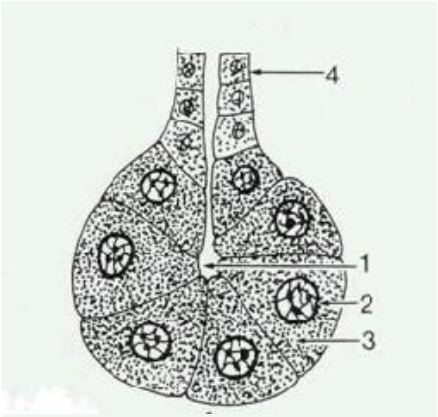

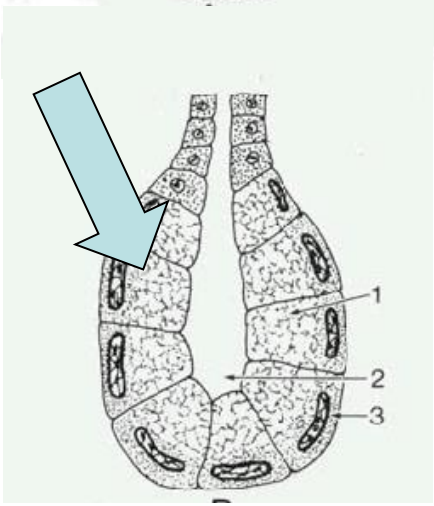

<u>Serøse</u>:

- runde kerner midt i cellerne
- lille lumen
- granuleret cytoplasma

<u>Mucøse</u>:

- flade kerner basalt i cellerne
- stort lumen
- lyst cytoplasma

Blandede endestykker

- serøse celler i lukket ende
- mucøse celler i åbne ende

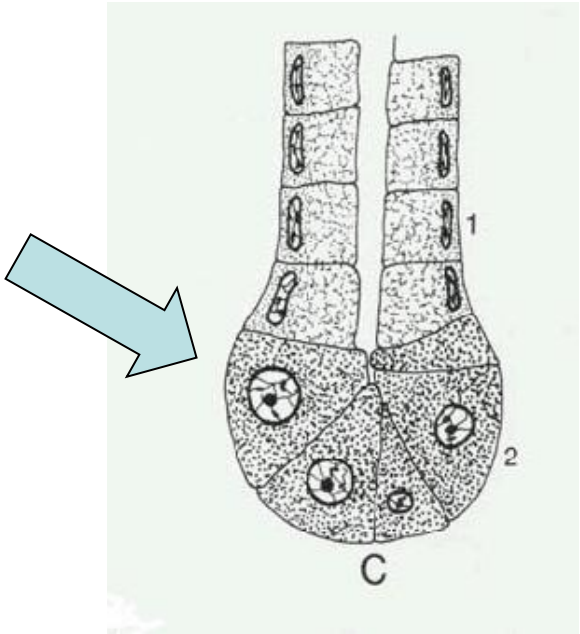

Sekretets art:

- <u>serøst</u> vandigt
- <u>mucøst</u> slimet
- <u>sero-mucøst</u> blandet

Peerfeedback 2 og 2 (evt 3)

Inddel kirtelepitel..				
TYPER				
Udførsel til overflade/ til blod (2)				
Antal celler (2)				
Sekretets art (2/3)				
Endestykke form (2/3)				
Endokrine kirtler (2 typer)				
..				
..				
..				

STØTTEVÆV
- vævslære

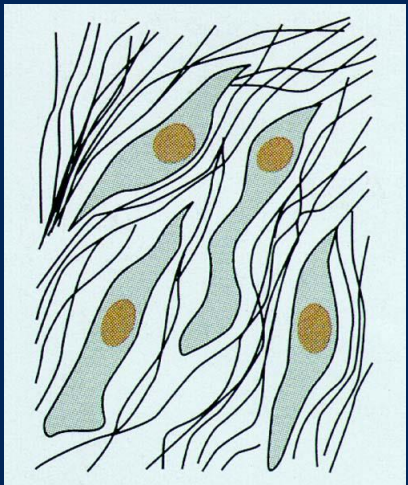

AARHUS
UNIVERSITET
INSTITUT FOR ODONTOLOGI OG ORAL SUNDHED

STØTTEVÆV

- få celler spreder sig
- danner fibriller og grundsubstans (matrix)

Inddeling:

- **b**indevæv
- **b**ruskvæv
- **b**envæv
- **b**lod og lymfe

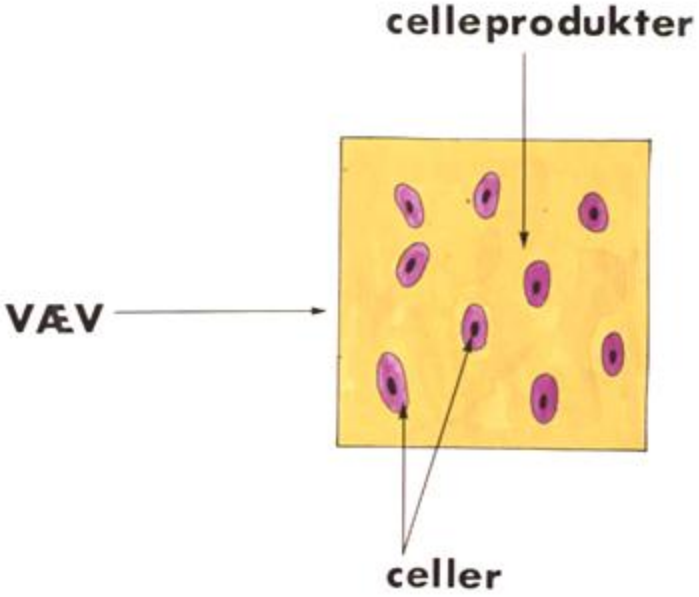

STØTTEVÆV

- celler kan bevæge sig
- og de spreder sig



http://www.cellimagelibrary.org/images/13162

STØTTEVÆV

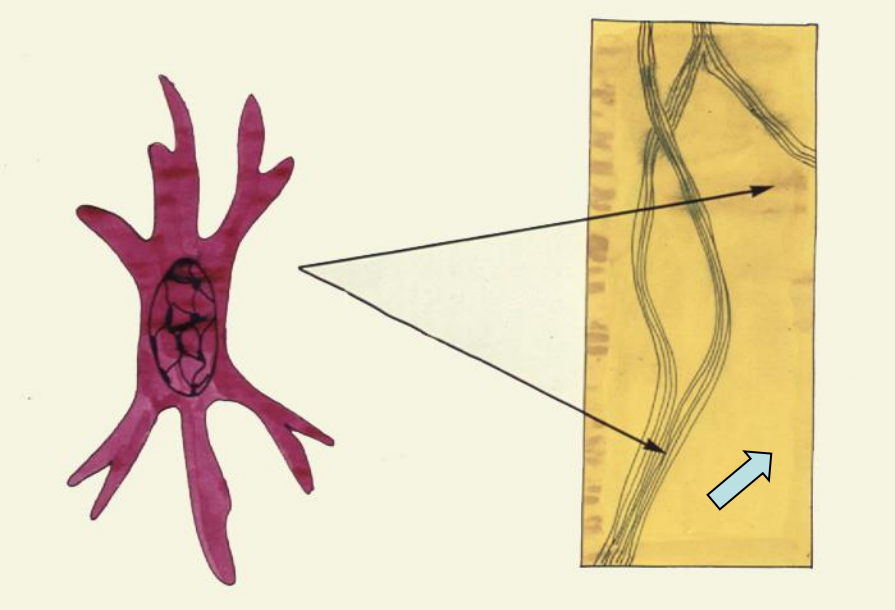

- celler i støttevæv danner:
  - fibriller (→)
  - grundsubstans (⇨)

} **matrix**

STØTTEVÆV

- **B**indevæv
- **B**ruskvæv
- **B**envæv
- **B**lod

4 x **B**

STØTTEVÆVS MATRIX

Bindevæv

- amorf grundsubstans er blød med fibriller

Bruskvæv

- amorf grundsubstans er fast med fibriller

Benvæv

- mineraliseret grundsubstans er meget fast med fibriller

Blod og lymfe

- amorf grundsubstans er flydende

BINDEVÆVSCELLER

fibroblaster

- danner fibriller
- amorf grundsubstans



BINDEVÆV



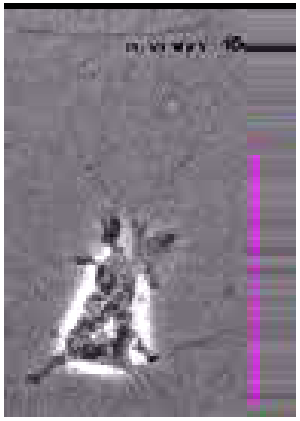

Matrix bliver dannet af celler i støttevæv, og den bidrager aktivt til udvikling, bevægelse og spredning af celler og væv såvel som deres stofskifte.

BINDEVÆVSCELLER

fibroblaster

- danner fibriller og
- amorf grundsubstans

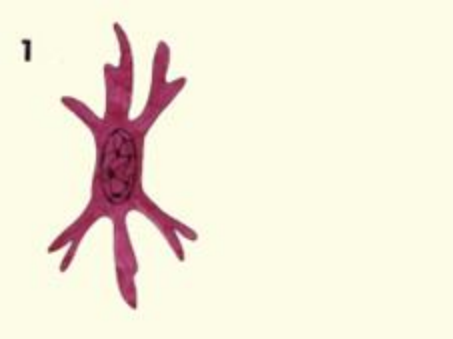

fedtceller

- kerne og cytoplasma ligger perifert
- indeholder stor fedtdråbe

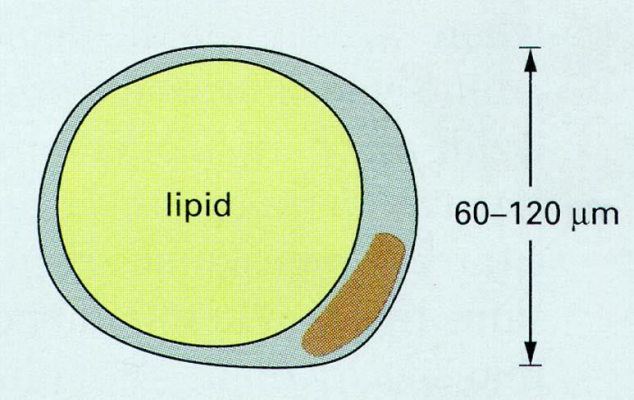

Mesenkym hvad er det?

fibroblaster

- danner fibriller og
- amorf grundsubstans

mesenkym

- er i støttevæv hos fostre
- er ikke specialiseret
- består af mange umodne/u-differentierede celler
- er 'mesenkymale stamceller'
- en del overlever i støttevæv hos voksne som 'voksen stamceller'

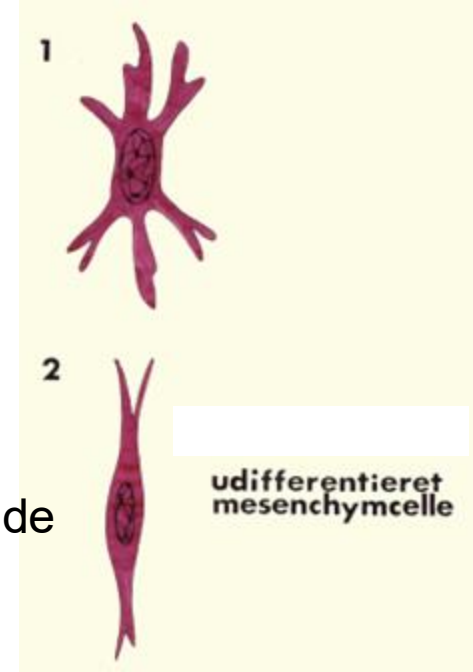

Mesenkym danner (en del) støttevæv

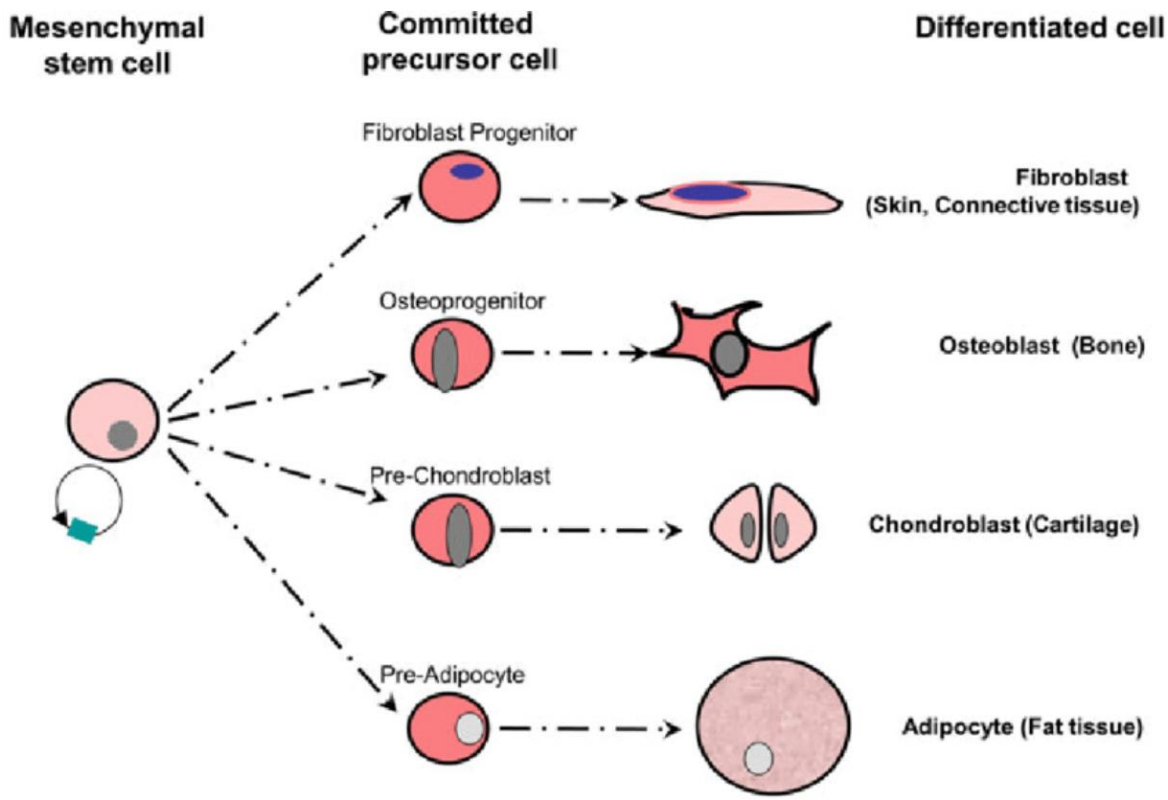

Cells of the connective tissue compartment derived from MSC

STØTTEVÆV

Bindevæv

Ben/Knoglevæv

Bruskvæv

+Fedtvæv

Lidt om stamceller..

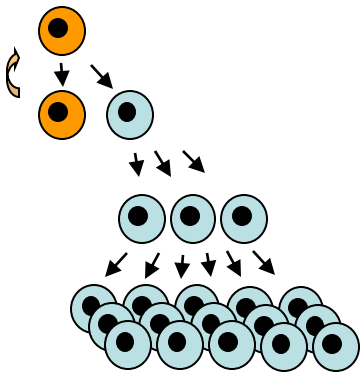

Stamceller

- er primitive celler
- er udifferentierede
- de kan danne 300 vævstyper

Embryonale stamceller

- fra den befrugtede ægcelle
- udvikler væv og organer i fosteret
- Antal celledelinger er ubegrænsede

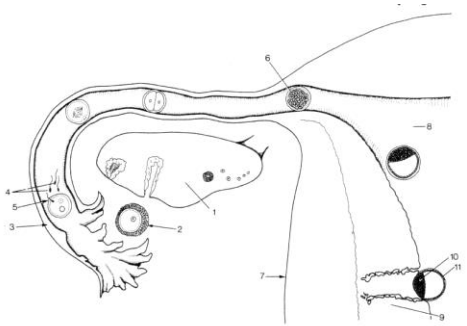

Voksne stamceller

- sidder i væv hos voksne
- ansvar for regeneration af vævsskade
- Evne til vævsregeneration er forskellig
- Antal celledelinger er begrænset

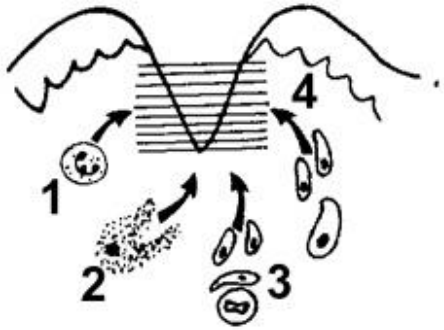

Peerfedback 2 og 2 - evt 3

Støttevæv				
Støttevæv (4)				
Hvordan er støttevævenes matrix (4)				
..				
..				
..				
..				

Støttevæv
- bindevæv
- bruskvæv
- benvæv
- blod

BINDEVÆV



AARHUS
UNIVERSITET
INSTITUT FOR ODONTOLOGI OG ORAL SUNDHED

BINDEVÆV

- indeholder også andre celler



BINDEVÆV
- indeholder også andre celler

- ‘stjerneformede’ celler med udløbere
  - fibroblaster
  - ‘mesenkymale stamceller
- runde
  - fedtceller



BINDEVÆV
- indeholder også andre celler

- ‘stjerneformede’ celler med udløbere
  - fibroblaster
  - ‘mesenkymale stamceller
  - makrofager
- runde
  - fedtceller
  - plasmacelle
  - mastcelle
  - lymfocyter
  - granulocyter

Hvide blodlegemer indgår i immun-reaktioner



FIBRILLER

Kollagene fibriller:

seje, bøjelige, uelastiske,

farveløse, i bundter

Elastiske fibriller:

elastiske, bøjelige

Reticulintråde:

tynde, umodne, kollagene fibriller

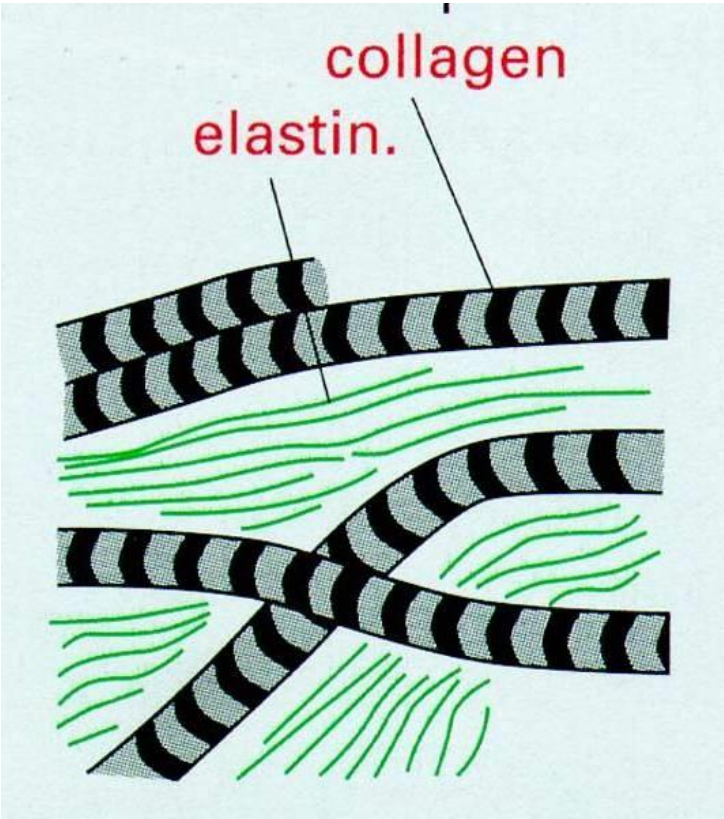

Grundsubstans

Det er en amorf gel-lignende substans der omgiver fibrene (fx kollagen/elastin) omkring cellerne (i den ekstracellulære matrix

Grundsubstans er primært sammensat af vand og store organiske molekyler, såsom protein, kulhydrat, fedt og mange proteoglycaner og glycoproteiner.

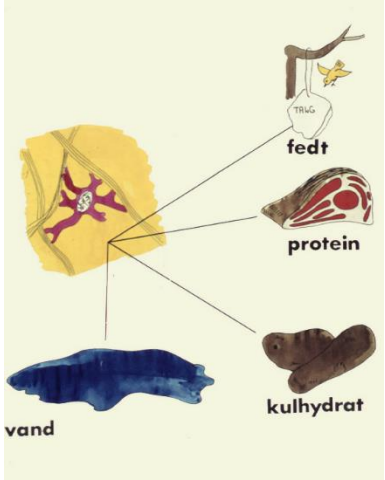

BINDEVÆVSTYPER

- **fibrillært bindevæv**

- **cellulært bindevæv**

BINDEVÆVSTYPER

- **fibrillært bindevæv**
  - **kollagent**
    - løst
    - fast
      - ***uorganiseret***
      - ***organiseret***
  - **elastisk**
- **cellulært bindevæv**
  - **retikulært**
    - løst finmasket

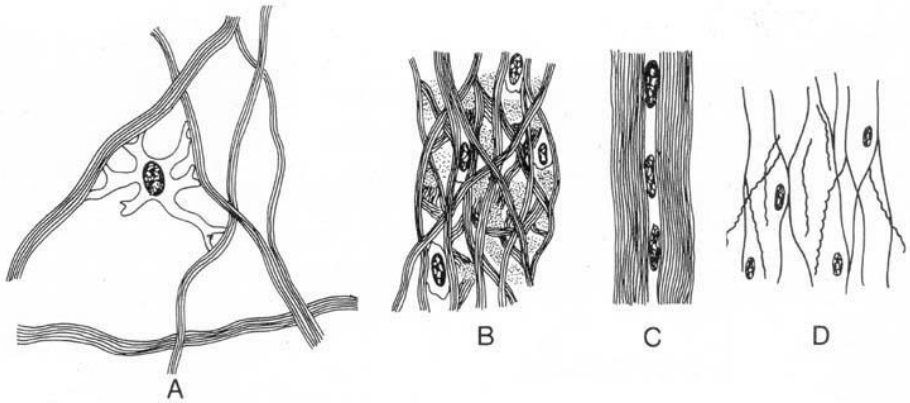

Fig. 17 – 20 bindevæv

fig. 17 fibrillært bindevæv
A kollagent løst bindevæv
B kollagent fast **uorganiseret** bindevæv
C kollagent fast **organiseret** bindevæv
D elastisk bindevæv

EKSEMPLER PÅ BINDEVÆV

- **fibrillært bindevæv**
  - **kollagent**
    - **løst**: kollagene fibriller har løs vævning fx tarmkrøs
    - **fast**: kollagene fibriller er tætliggende
      - *uorganiseret* fx læderhud og mundslimhinde
      - *organiseret* fx sener
  - **elastisk** fx arterier
- **cellulært bindevæv** fx lymfeknuder og fedtvæv

Peerfedback 2 og 2 - evt 3

Bindevæv				
Bindevævsfibriller(3)				
Bindevæv, hovedtyper(2)				

Fibrillært bindevæv (5)
 	
- kollagent
  - 1
  - 2
  - I
  - II
- elastisk
	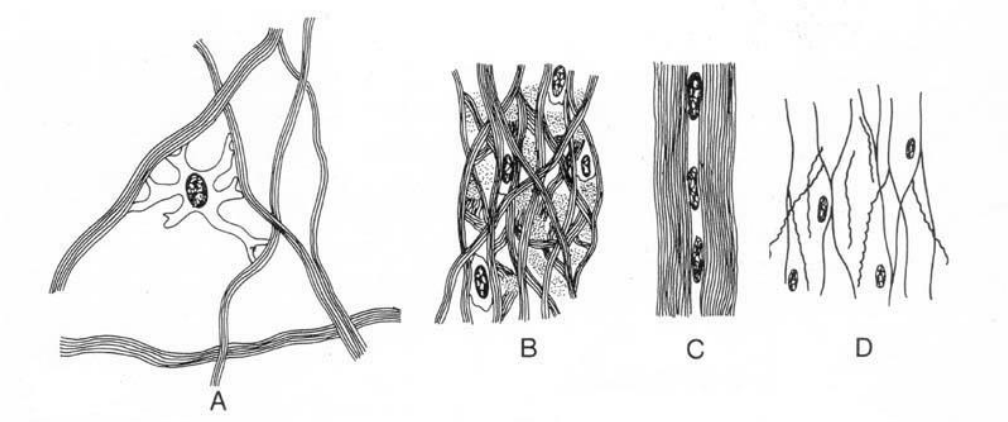			

..				
..				
..				
..				
..				
..				

Støttevæv
- bindevæv
- bruskvæv
- benvæv
- blod

BRUSKVÆV

AARHUS
UNIVERSITET
INSTITUT FOR ODONTOLOGI OG ORAL SUNDHED

BRUSKVÆV

- mangler kar
- ernæres fra:
  - periferi via bruskhinden (perichondrium)
    - som er et fibrillært tæt kollagent bindevæv
  - ledvæske (i ægte led)

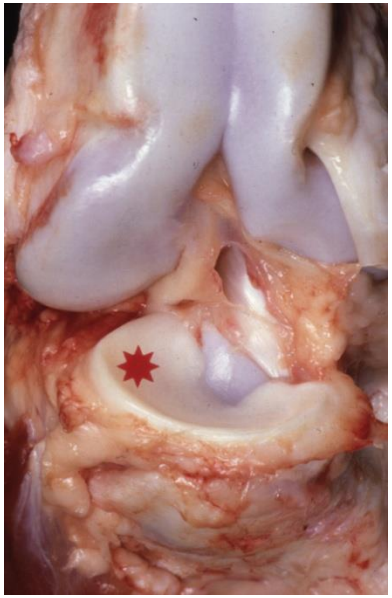

Støttevæv
- bindevæv
- bruskvæv
- benvæv
- blod

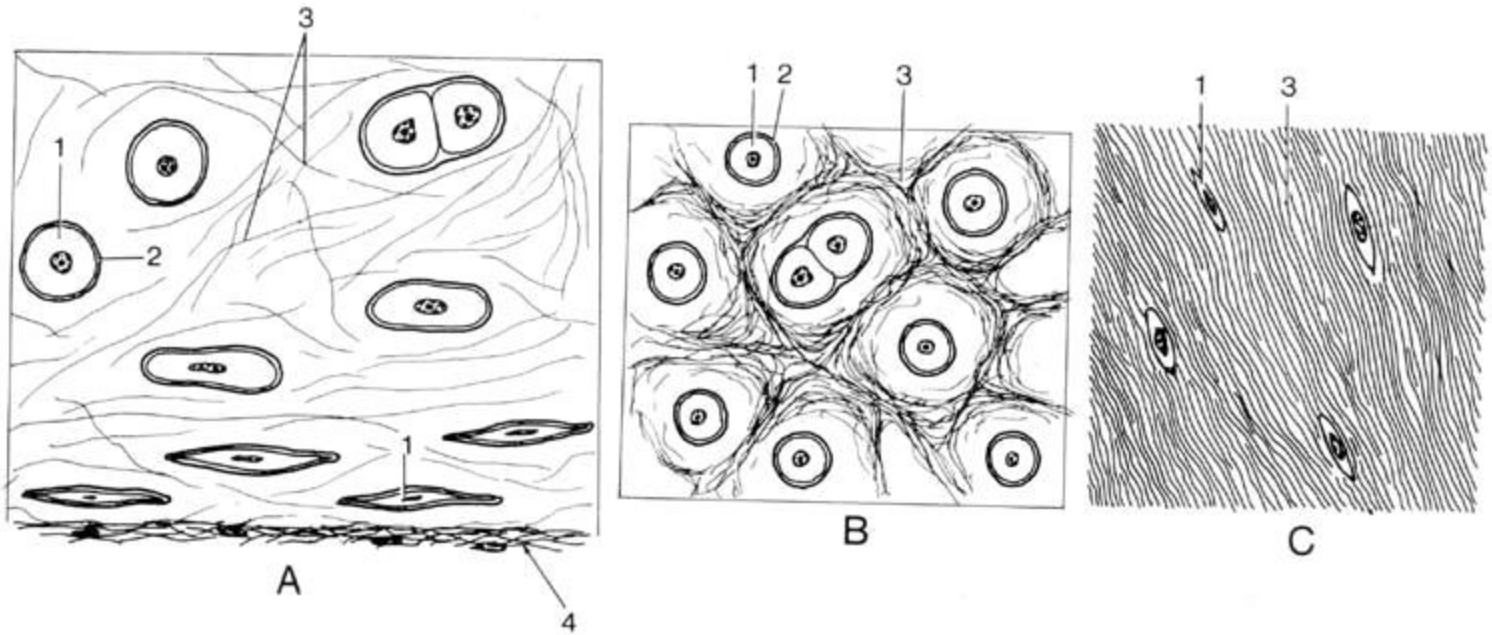

Hyalin brusk Elastisk brusk Fibrocartilago

Hyalin brusk

- blålighvid, bøjelig, elastisk
- ses fx i led, næse og ribben
- chondrocyter er indlejrede i matrixen
- amorf fast grundsubstans med kollagene fibriller

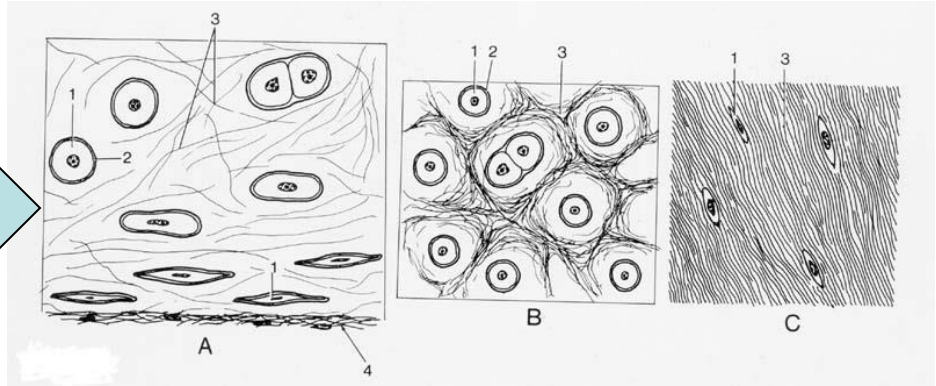

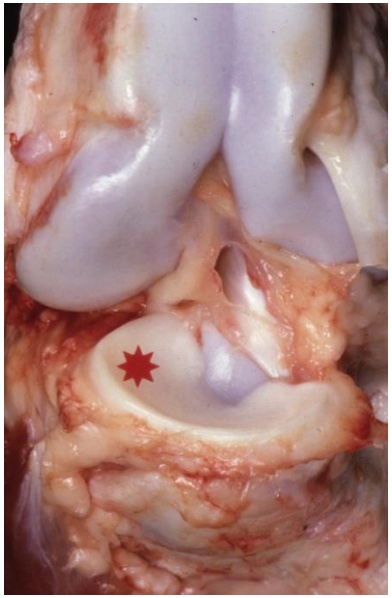

Elastisk brusk

- gullig, bøjelig og <u>meget elastisk</u>
- ellers som hyalin brusk
- men indeholder <u>elastiske fibriller</u>

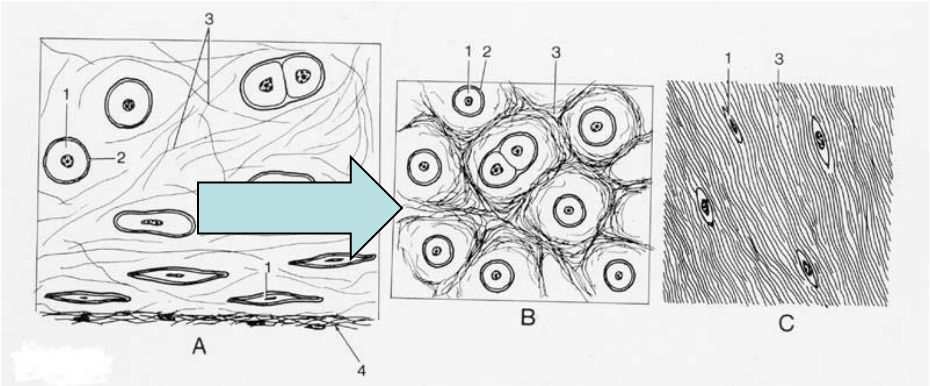

Fibrocartilago

- grålig-hvid, sej, bøjelig og <u>uelastisk</u>
- ses fx i kæbeleddets ledskive og knæleddets menisker
- indeholder <u>mange kollagene</u> fibriller

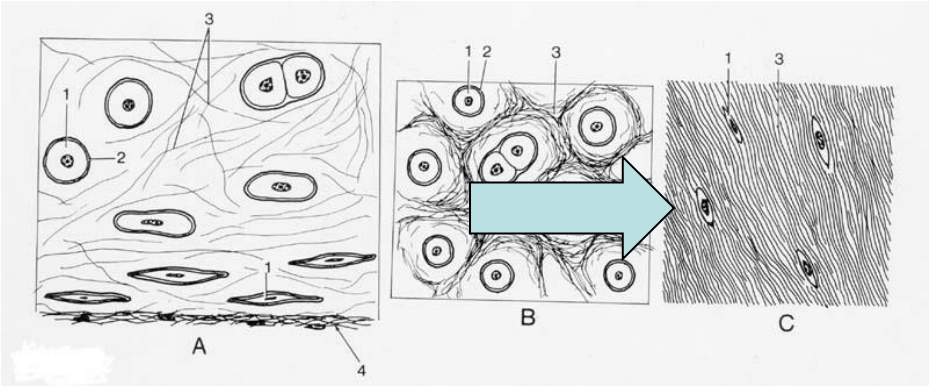

Bindevæv og brusk

→ Mentimeter

KNOGLEVÆV

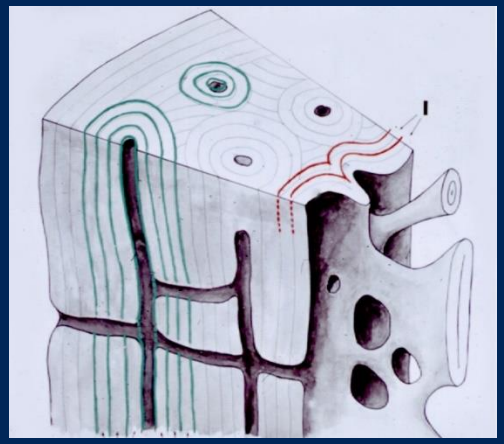

KNOGLEVÆV

- gulligt, hårdt og kun <u>delvist elastisk</u>
- ca 30% vand
- salte danner krystaller (hydroksylapatit der består af calcium, fosfat og hydroksyl-ioner)
- grundsubstans er <u>mineraliseret</u>
- knogle har en ‘mineraliseret matrix’

KNOGLEVÆV

- støtter og beskytter organer
- udspring og tilhæftning af muskler

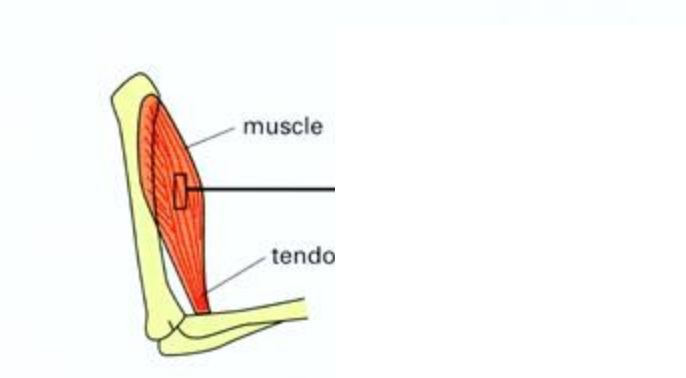

KNOGLEVÆV

- substantia compacta
  - ydre kompakt knoglemasse
- substantia spongiosa
  - knoglemarv og knoglebjælker (trabekler)

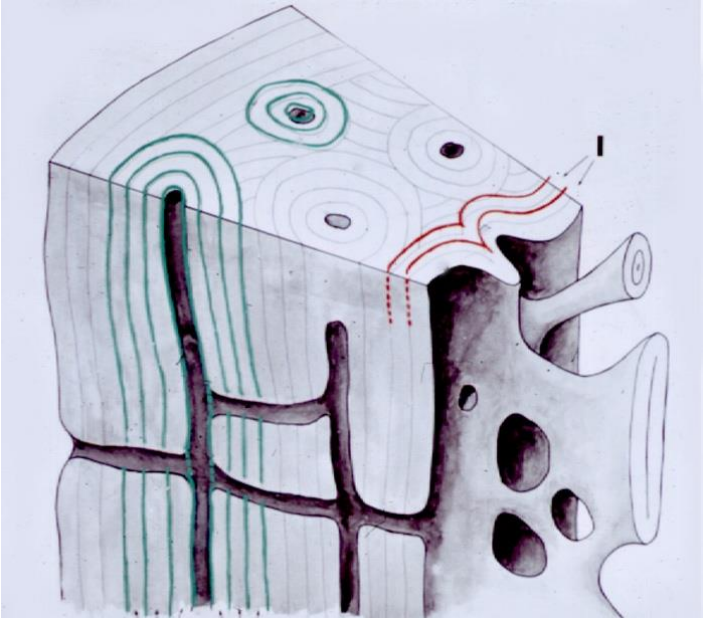

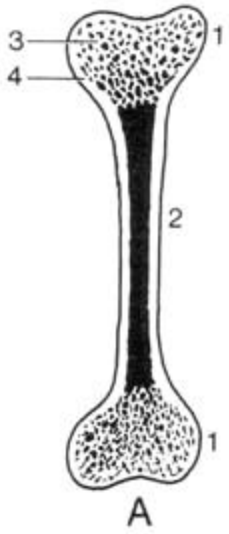

Vigtig forskel

- Knogle-nydannelse
  - celler differentierer og danner knogle

(modelering)

Vigtig forskel

- Knogle-<u>ny</u>dannelse
  - celler differentierer og danner knogle

(modelering)

- Knogle-<u>om</u>dannelse
  - celler nedbryder og gendanner knogle

(remodelering)

KNOGLE-NYDANNELSE

”OSTEOGENESE” på 2 måder:

- direkte i bindevæv
- eller udenpå brusk

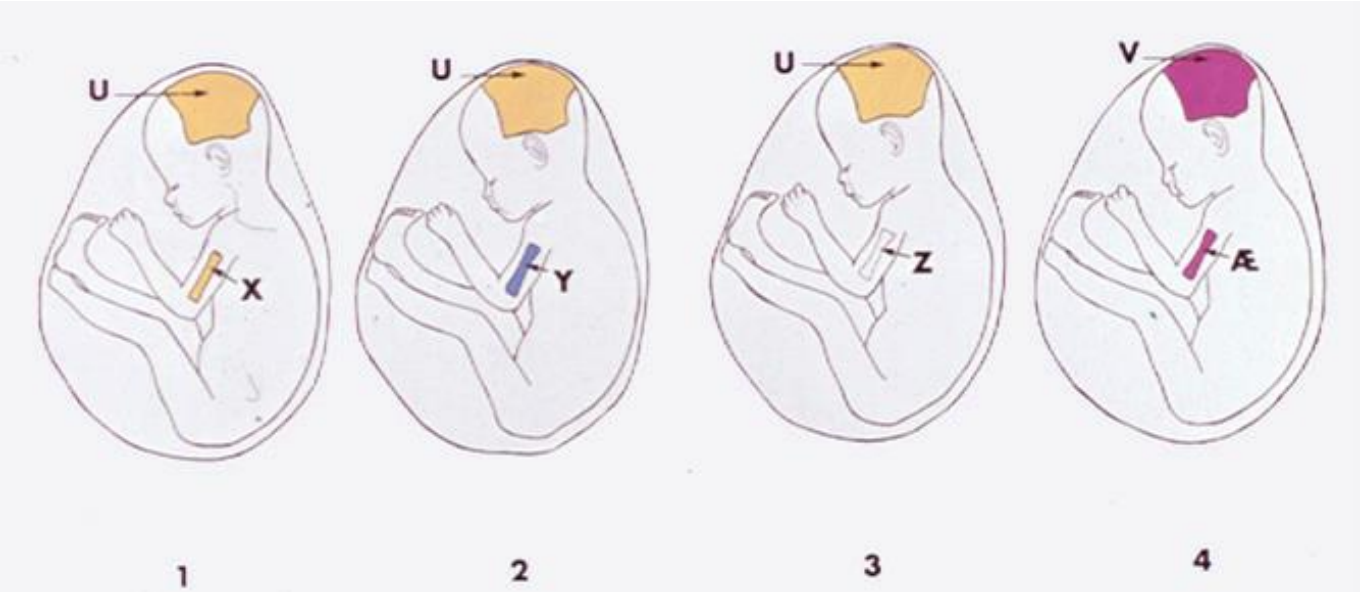

OSTEOGENESE

Desmal osteogenese

- bindevævspræformeret knogledannelse (u-v)

Chondral ostegenese

- bruskpræformeret knogledannelse (x-æ)

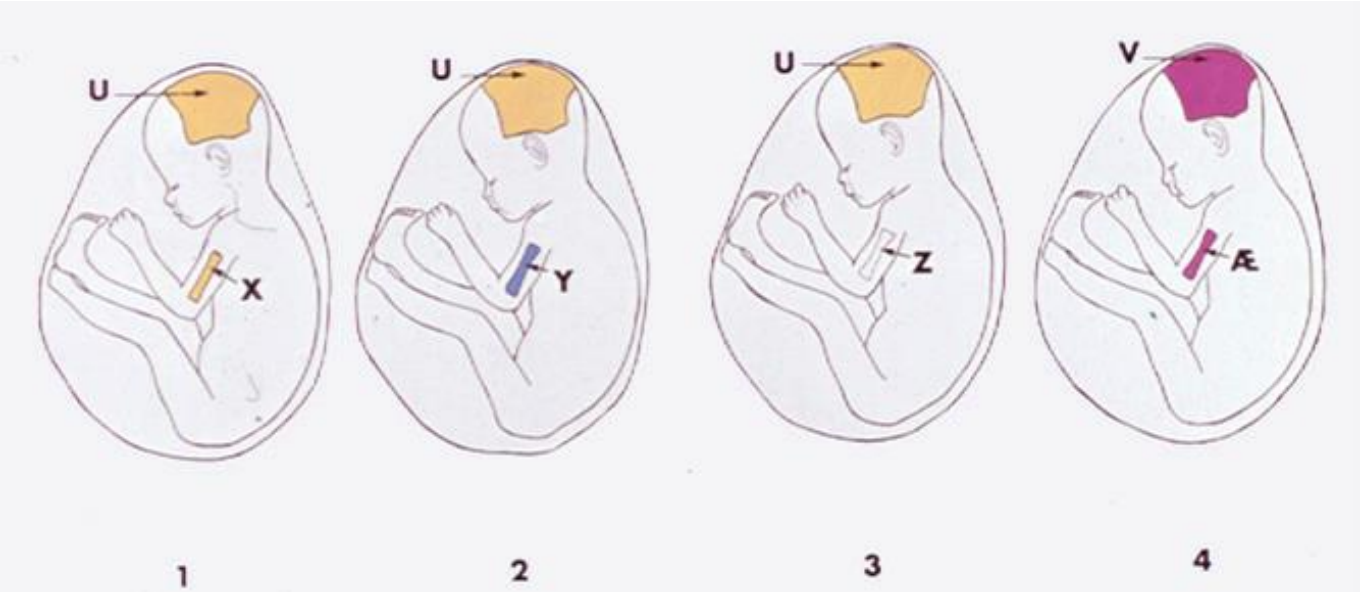

DESMAL OSTEOGENESE (a-e)

DESMAL OSTEOGENESE (a)

- Mesenchymale stamceller differentierer til osteoblaster



DESMAL OSTEOGENESE (b)

- Osteoblaster laver en fast grundsubstans (osteoidt væv) som de omgiver

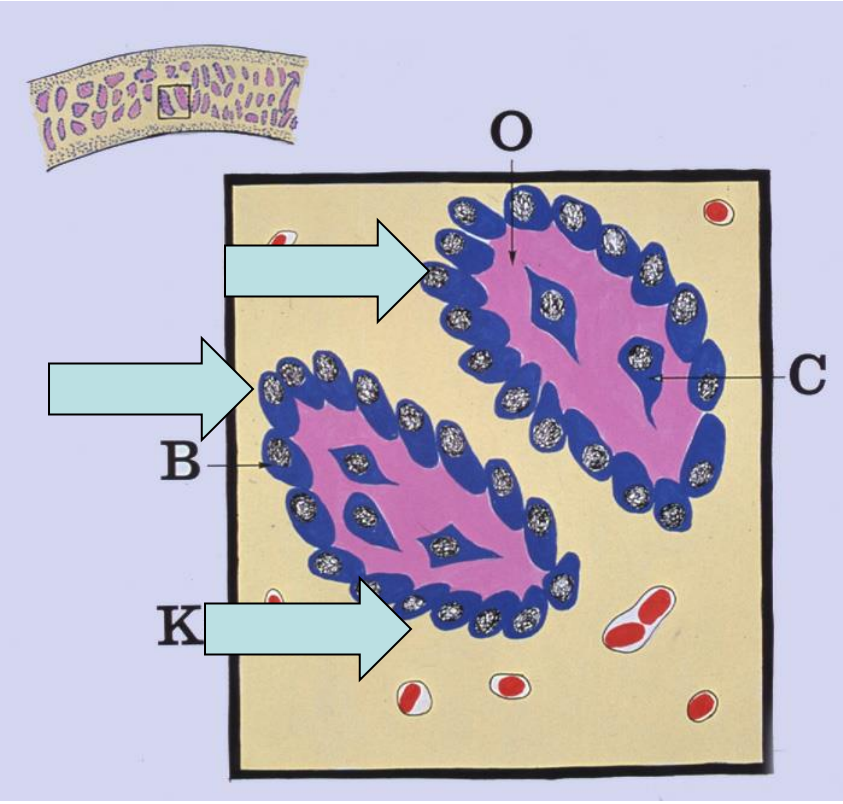

DESMAL OSTEOGENESE (c)

- Osteocytter indlejres

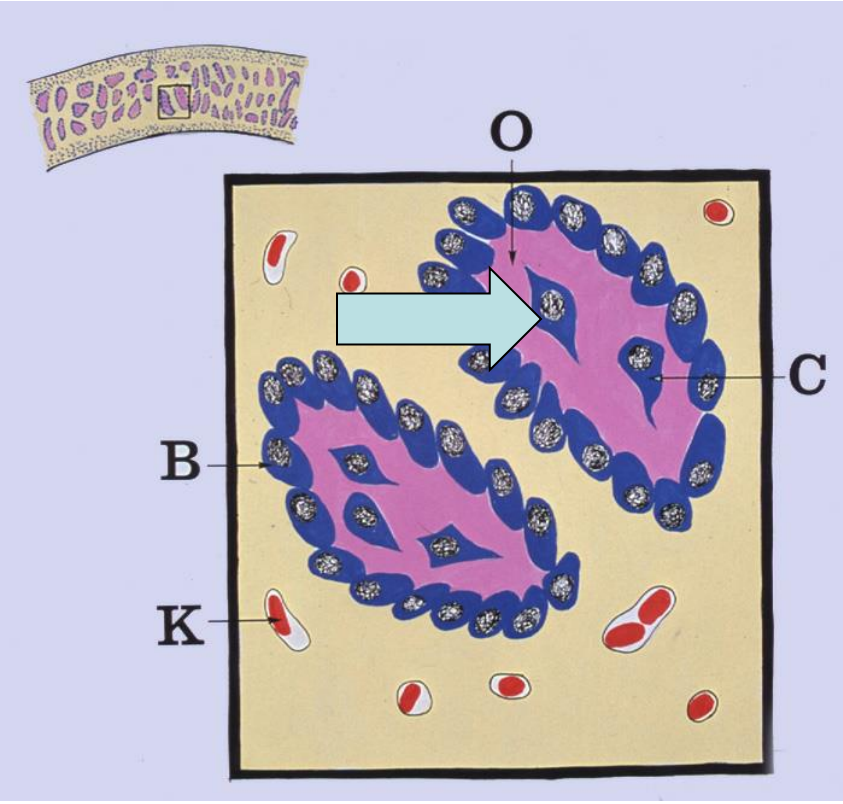

DESMAL OSTEOGENESE (d)

- Mineralsalte aflejres

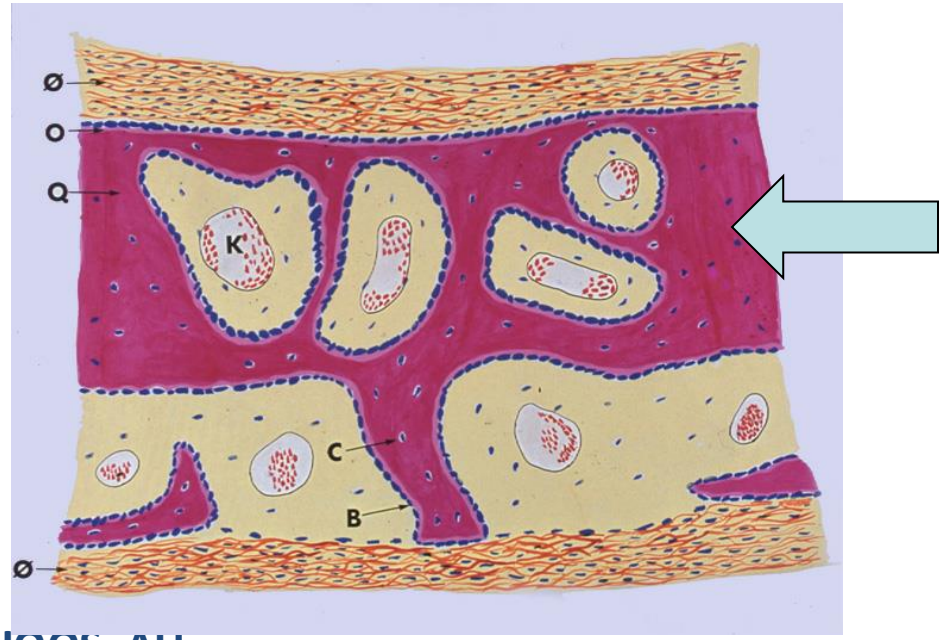

DESMAL OSTEOGENESE (e)

- Knogle er dannet

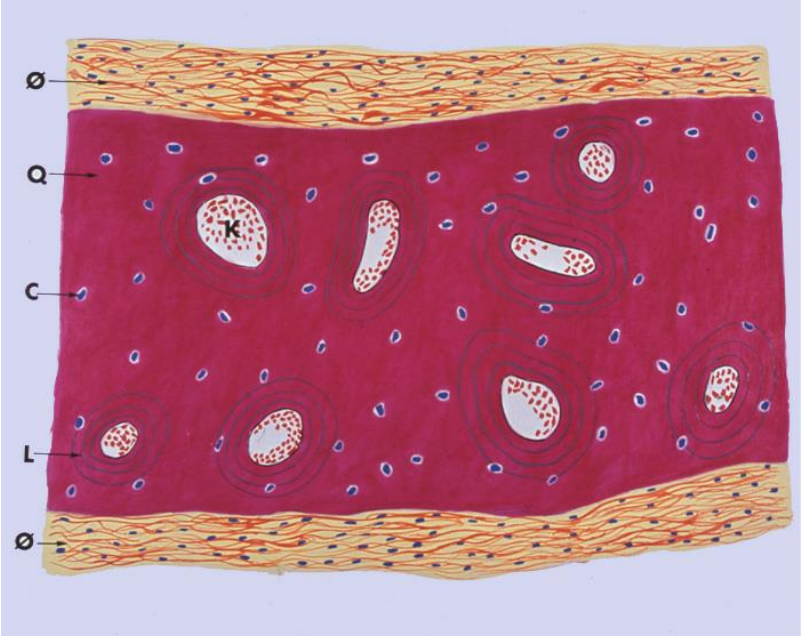

CHONDRAL OSTEOGENESE (a-i)

CHONDRAL OSTEOGENESE (a)

- Først udvikles en lille bruskmodel

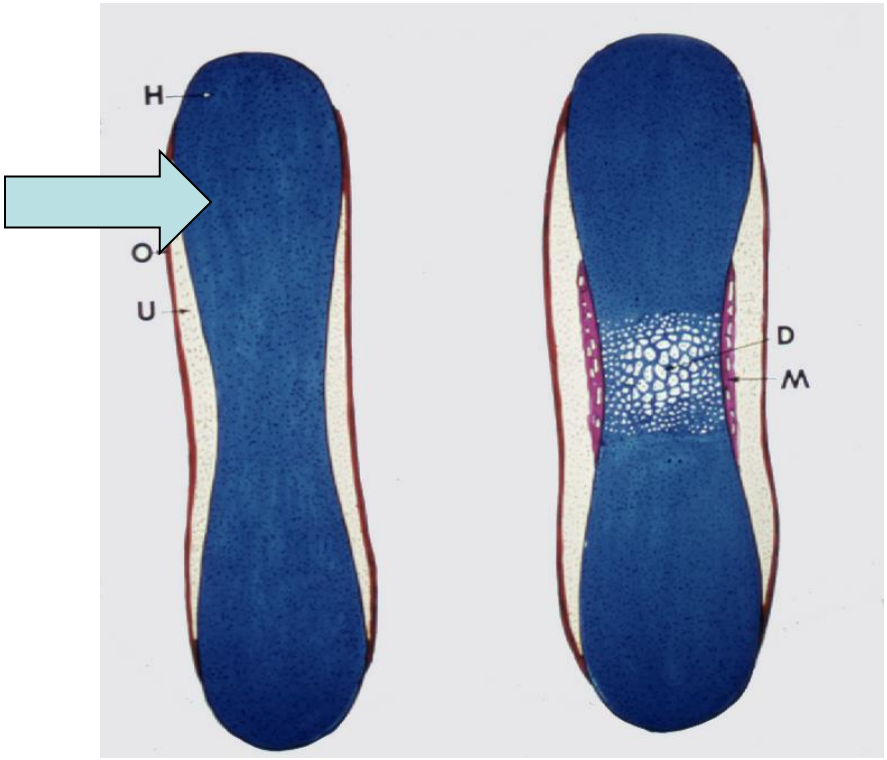

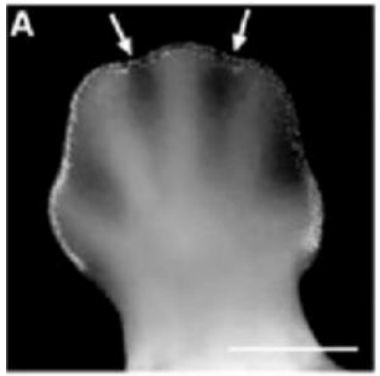

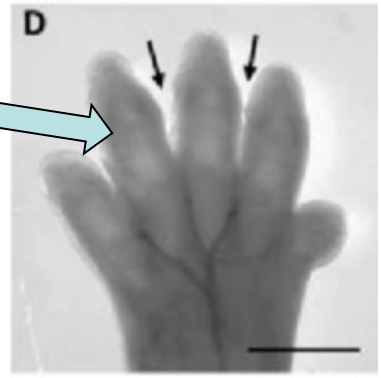

CHONDRAL OSTEOGENESE (b)

- Knogleceller lægger sig som en manchet

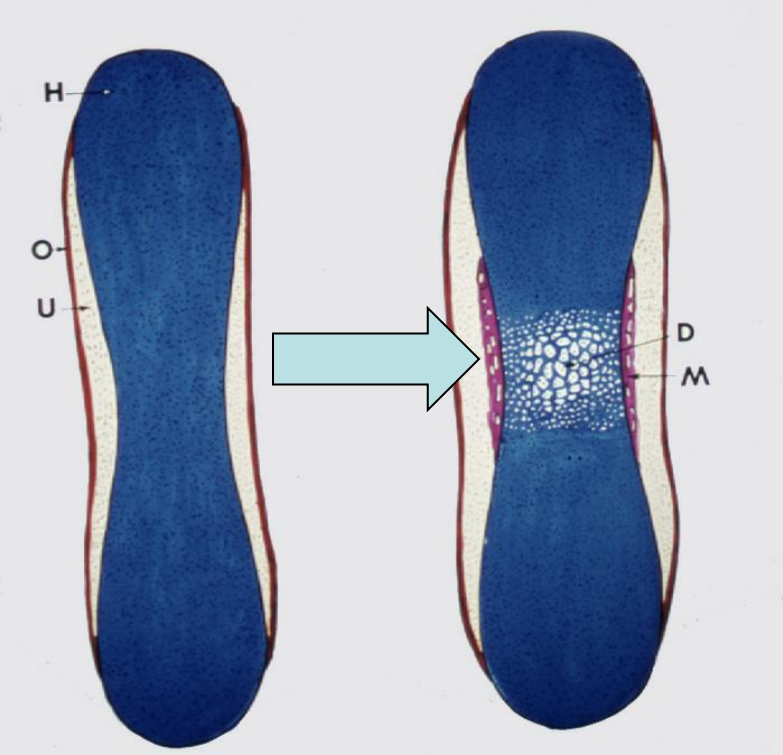

CHONDRAL OSTEOGENESE (c)

- Brusk <u>henfalder</u>
- Brusken omdannes ikke til knogle (NB)

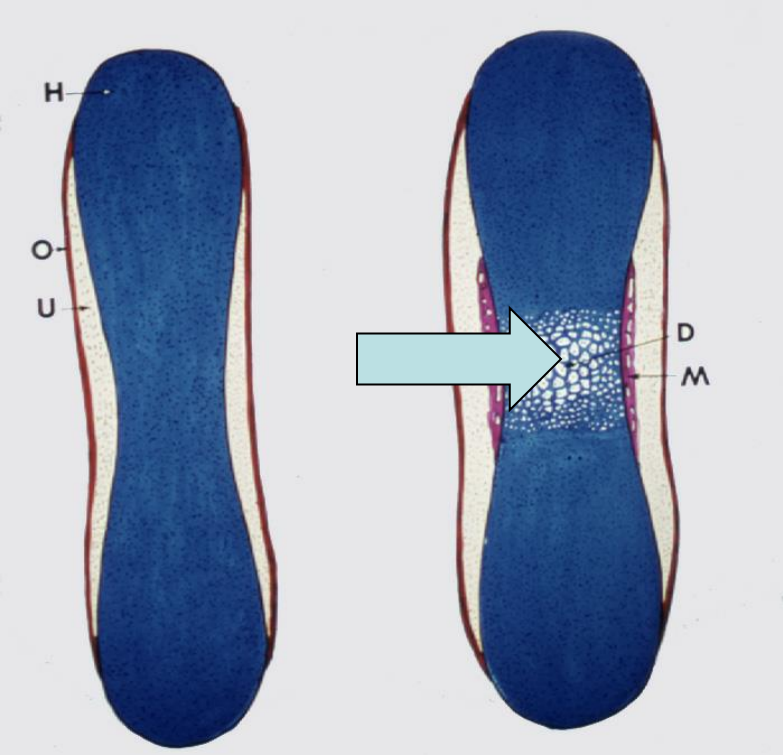

CHONDRAL OSTEOGENESE (d)

- Bruskceller efterlader huller
- <u>Bindevæv (med kar og mesenkymale stamceller) vokser ind</u>

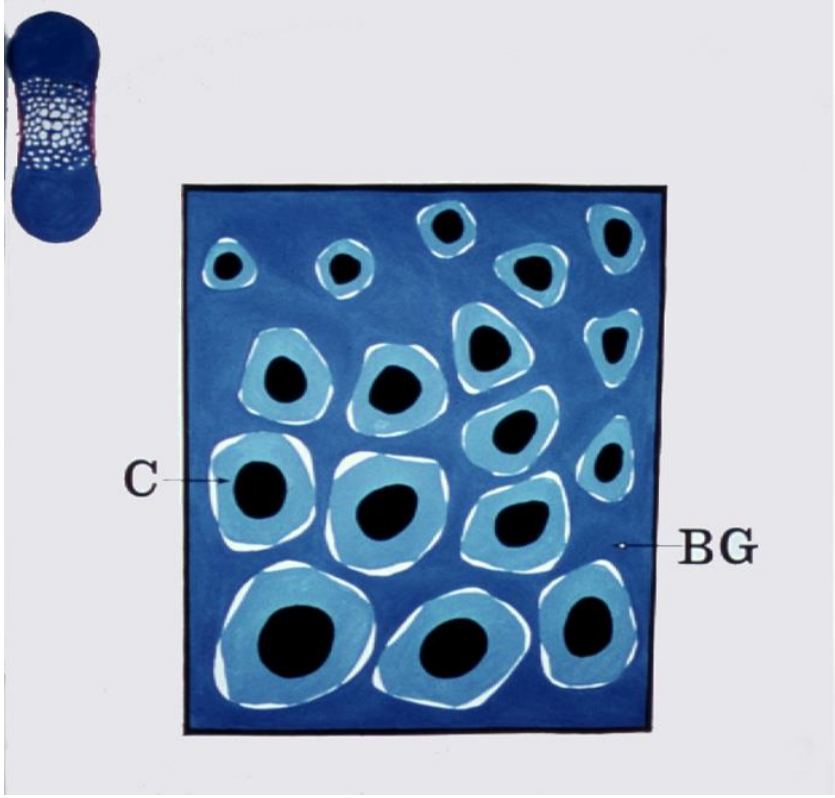

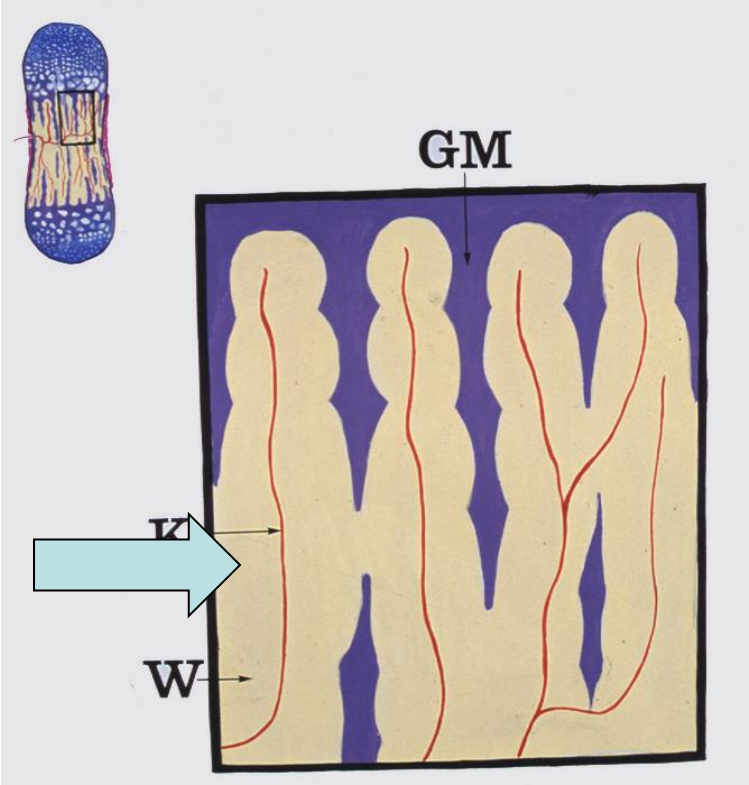

CHONDRAL OSTEOGENESE (e)

- Hullerne bliver invaderet af bindevæv (mesenkym)

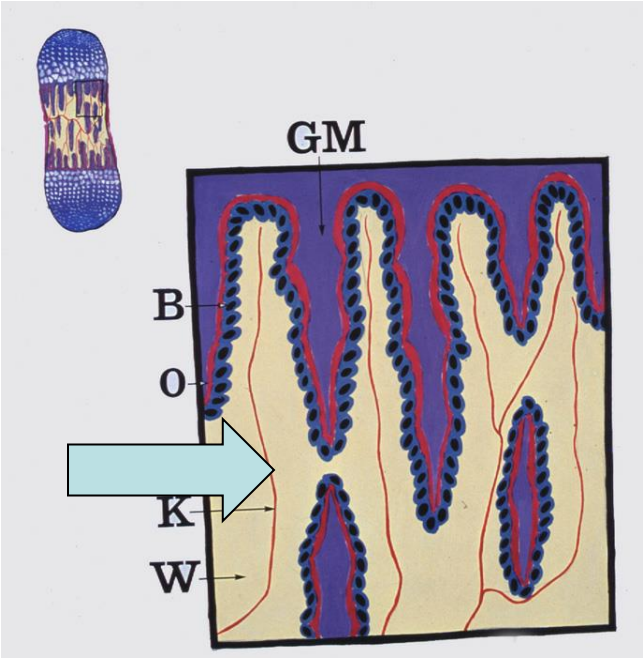

CHONDRAL OSTEOGENESE (f)

- Stamceller i bindevævet (mesenchym) differentierer til <u>osteoblaster</u>

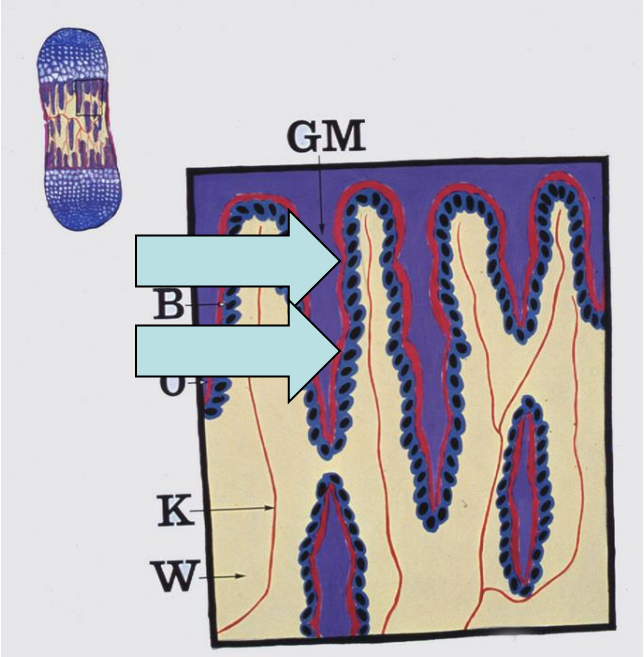

CHONDRAL OSTEOGENESE (g)

- Osteoblaster aflejrer knoglevævsmatrix
- først er vævet umineraliseret ‘osteoidt væv’

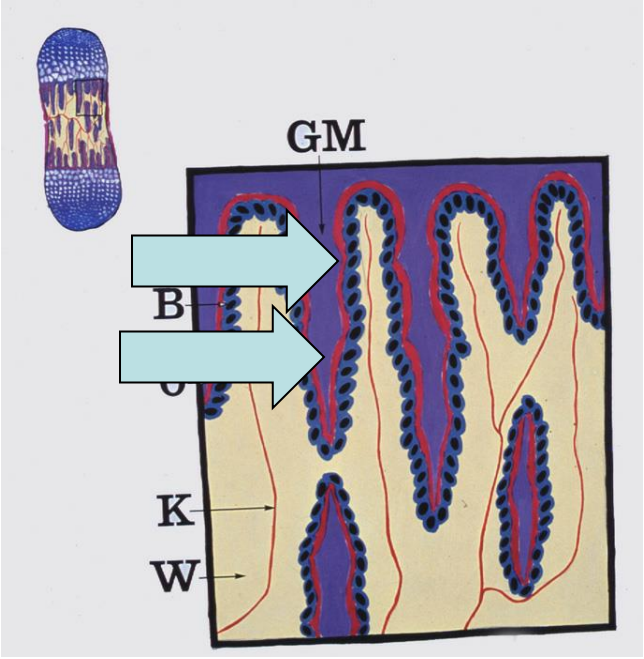

CHONDRAL OSTEOGENESE (h)

- Det osteoide væv <u>mineraliserer</u>

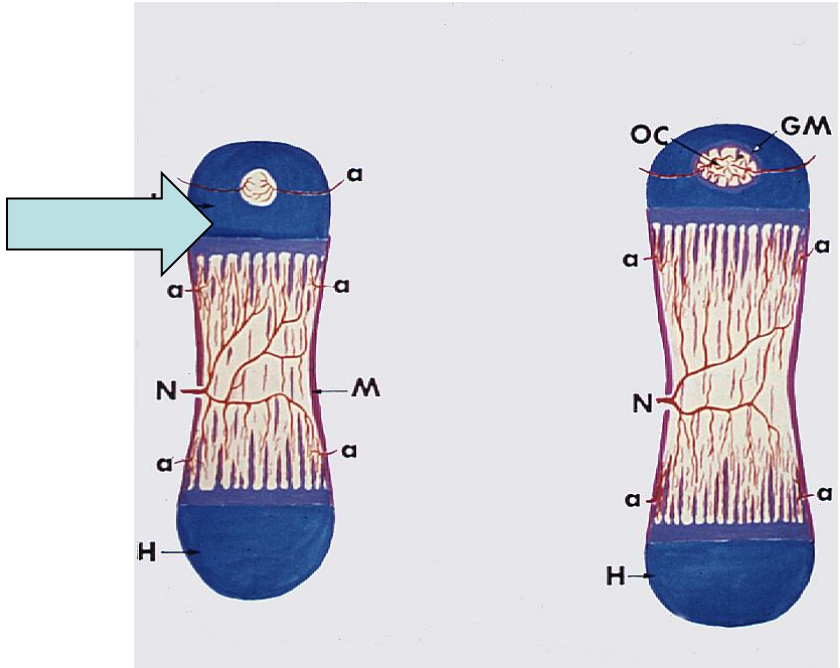

CHONDRAL OSTEOGENESE (i)

- Det osteoide væv bliver til knoglevæv med <u>indlejrede osteocyter</u>

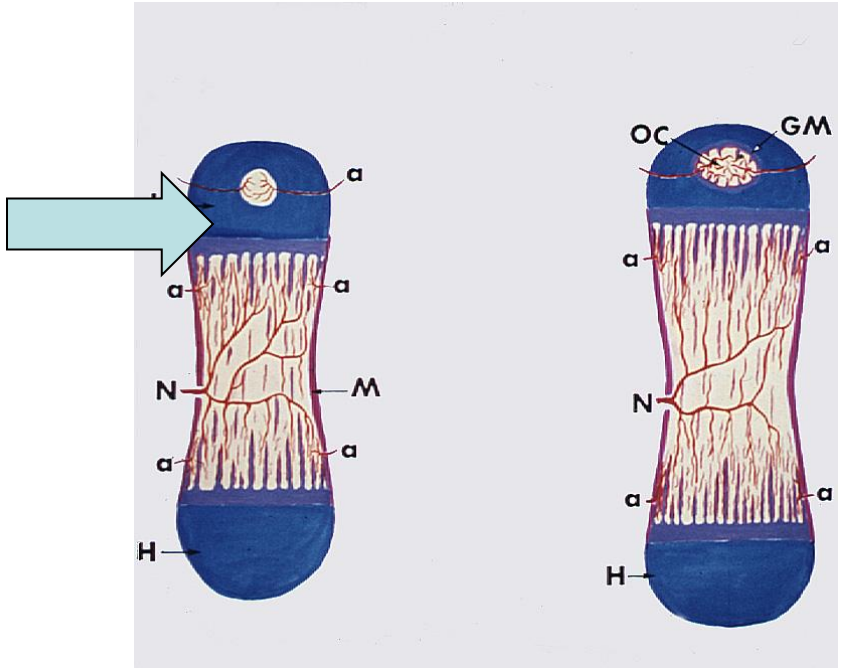

Knogledannelse
..en sammenfatning

Desmal osteogenese

- mesenkymalt bindevæv ”omdannes” til knogle

Chondral osteogenese

- bruskvæv ”erstattes” af knogle

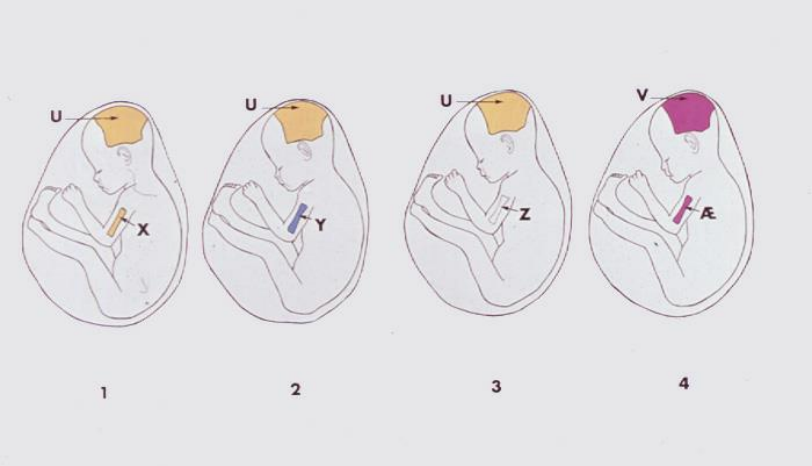

OMDANNELSE AF KNOGLEVÆV

- en færdiganlagt knogle bliver over tid omdannet indeni, og kan også vokse udenpå

apposition

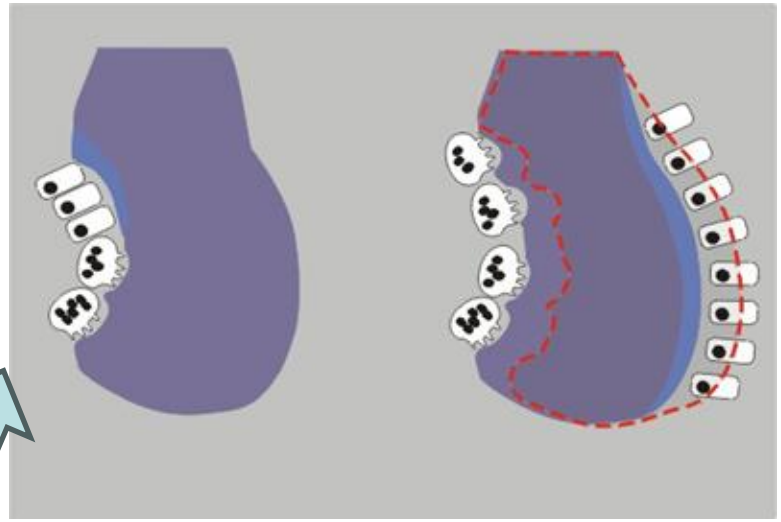

resorption

http://class.cvm.uiuc.edu/j-eurell/ms23.htm

Remodelering

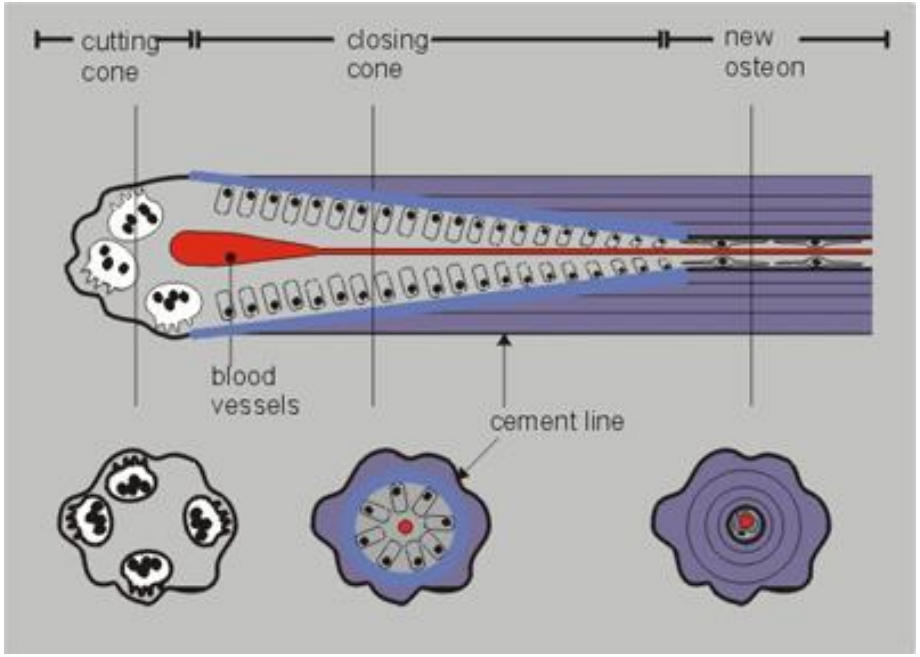

- Moden knogle omdannes løbende indeni ved remodelering
- Kompakt knogle bliver resorberet af osteoklaster
- Ny knogle bliver dannet i resorptionskaviteten af osteoblaster
- Væggene vokser indad og blodkarrene kommer til at ligge centralt i den nye osteon
- De koncentriske cirkler svarer til det Haverske lamelsystem

http://class.cvm.uiuc.edu/j-eurell/ms23.htm

KNOGLECELLER

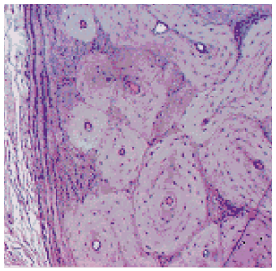

- <u>osteoklaster</u> nedbryder knogle
  - har flere kerner
- <u>osteoblaster</u> opbygger knogle
  - er unge knogledannende celler



KNOGLECELLER

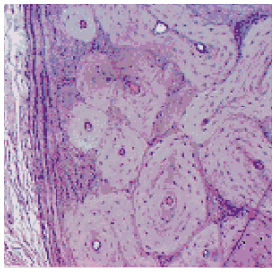

- <u>osteocyter</u> er modne osteoblaster
  - indlejret i mineraliseret grundsubstans
  - med udløbere mellem lakuner (de når hinanden og ‘anastomoser’)

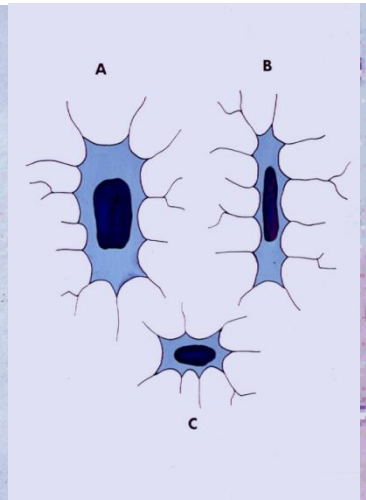

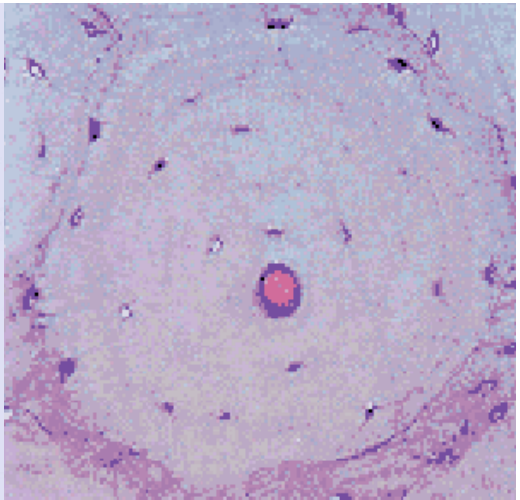

KNOGLECELLER

Altså:

- osteoblaster bliver til osteocyter

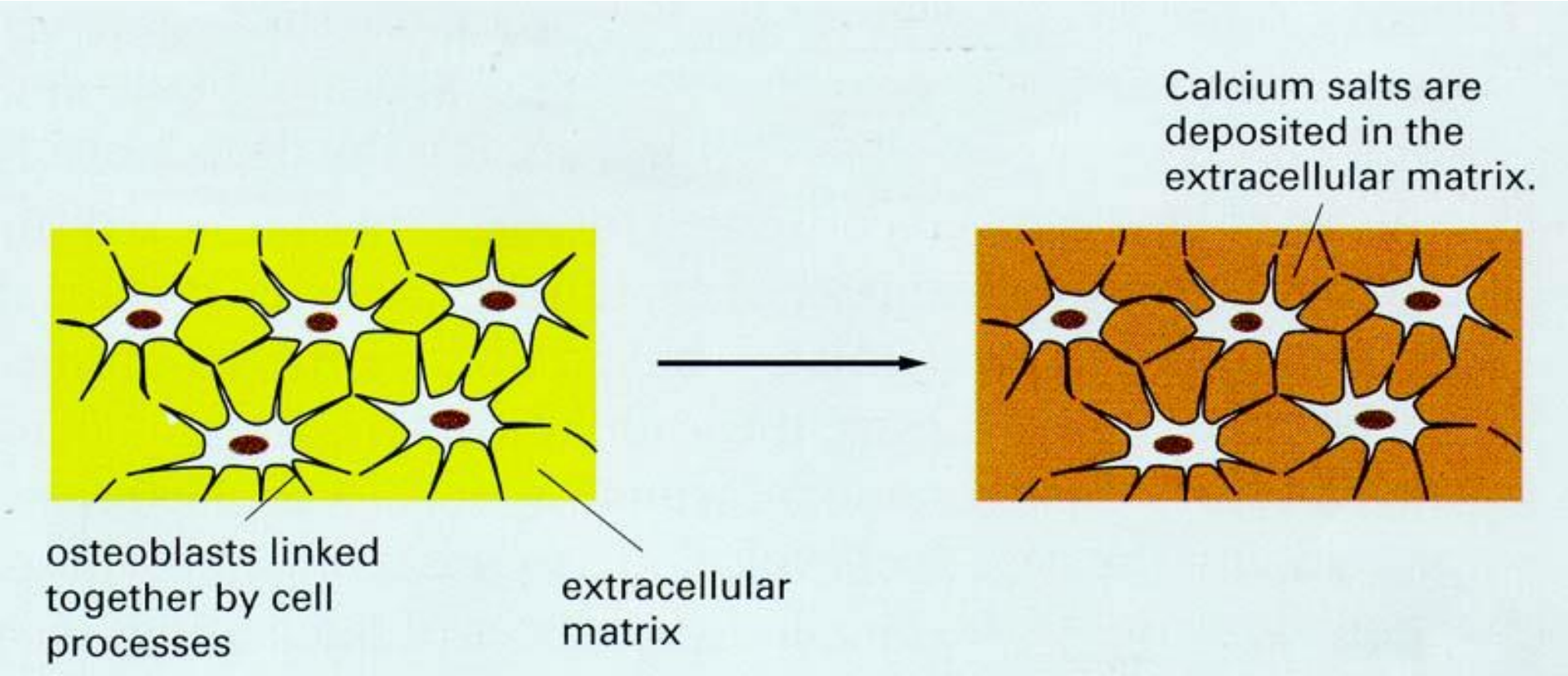

KNOGLEVÆV

- grundsubstans er mineraliseret
- kollagenfibriller ligger i lameller

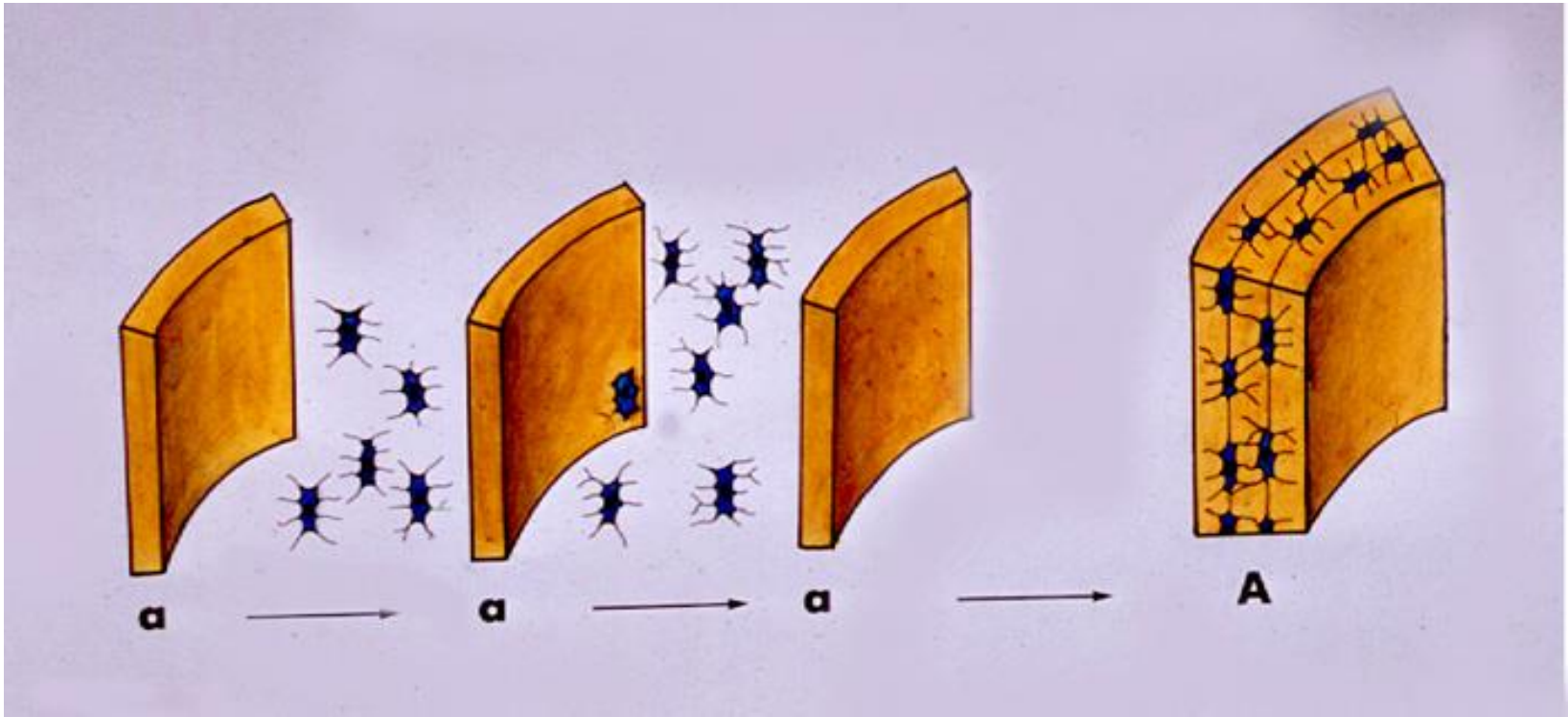

Haverske lamelsystem

- aflejring af fibriller og grundsubstans
- i 5-10 koncentriske rør
- ind mod en central kanal

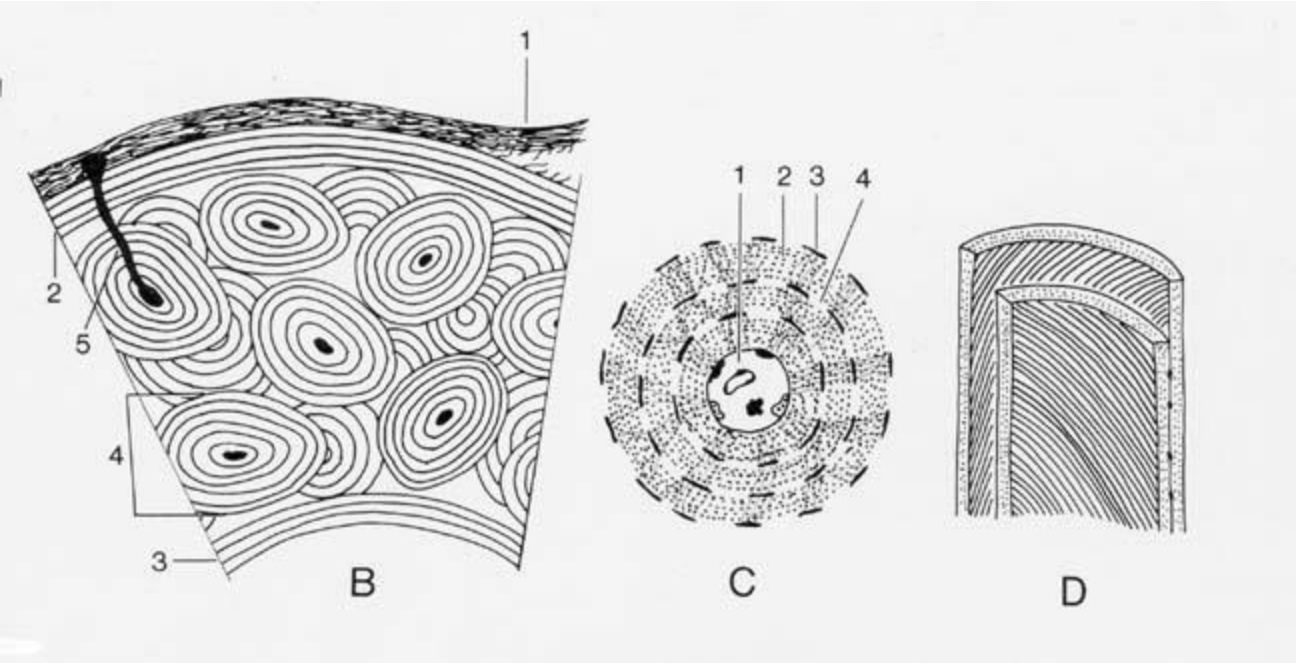

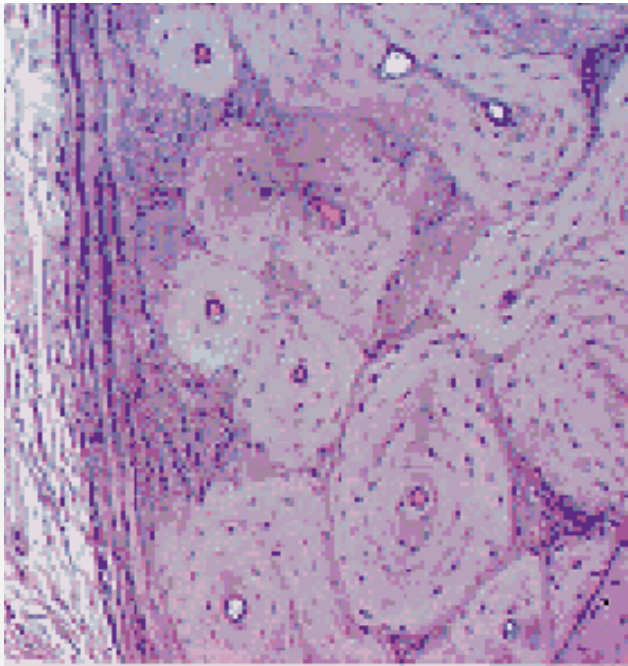

Knoglevæv

→ Mentimeter

Osteon

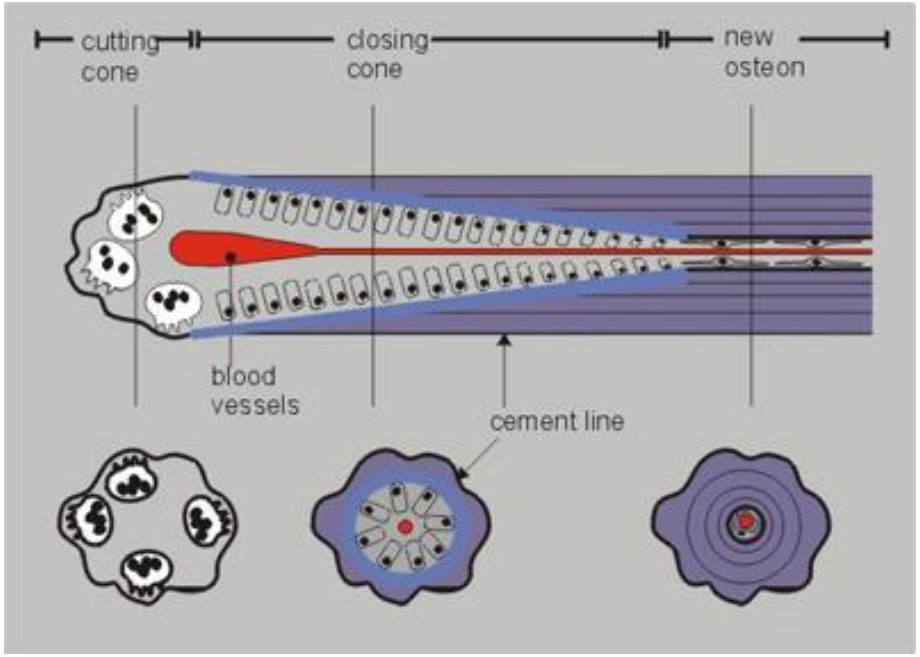

Osteon (bone structural unit)

- Haversk lamelsystem
  - osteoblaster
  - osteocyter
  - bone lining cells
  - osteoklaster
  - bindevæv og kar
  - Haversk kanal
- i substantia compacta

http://class.cvm.uiuc.edu/j-eurell/ms23.htm

Hemi-osteon

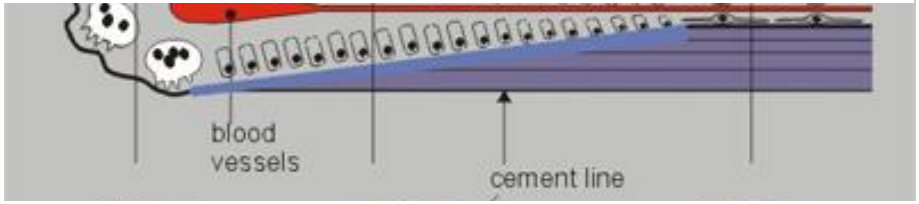

- i knogleoverfladen
- i knogletrabekler
- i substantia spongiosa

http://class.cvm.uiuc.edu/j-eurell/ms23.htm

Periost (benhinde)

- fibrøs membran
- fibrillært, kollagent, fast, organiseret bindevæv
- vigtig for ernæring og tykkelsesvækst
- reparation/regeneration

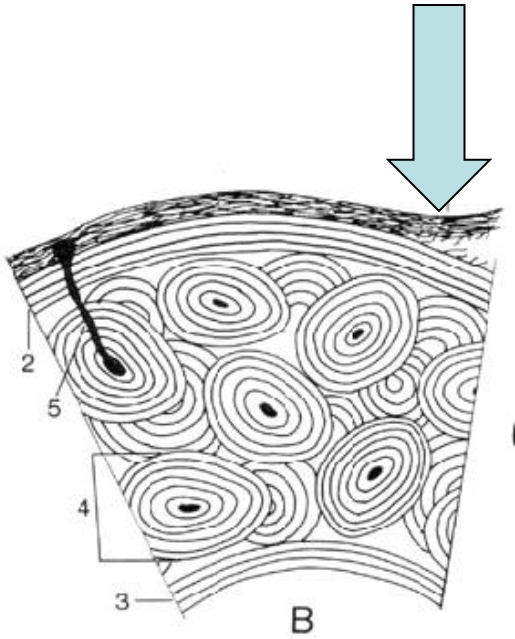

Kompakt knogle..

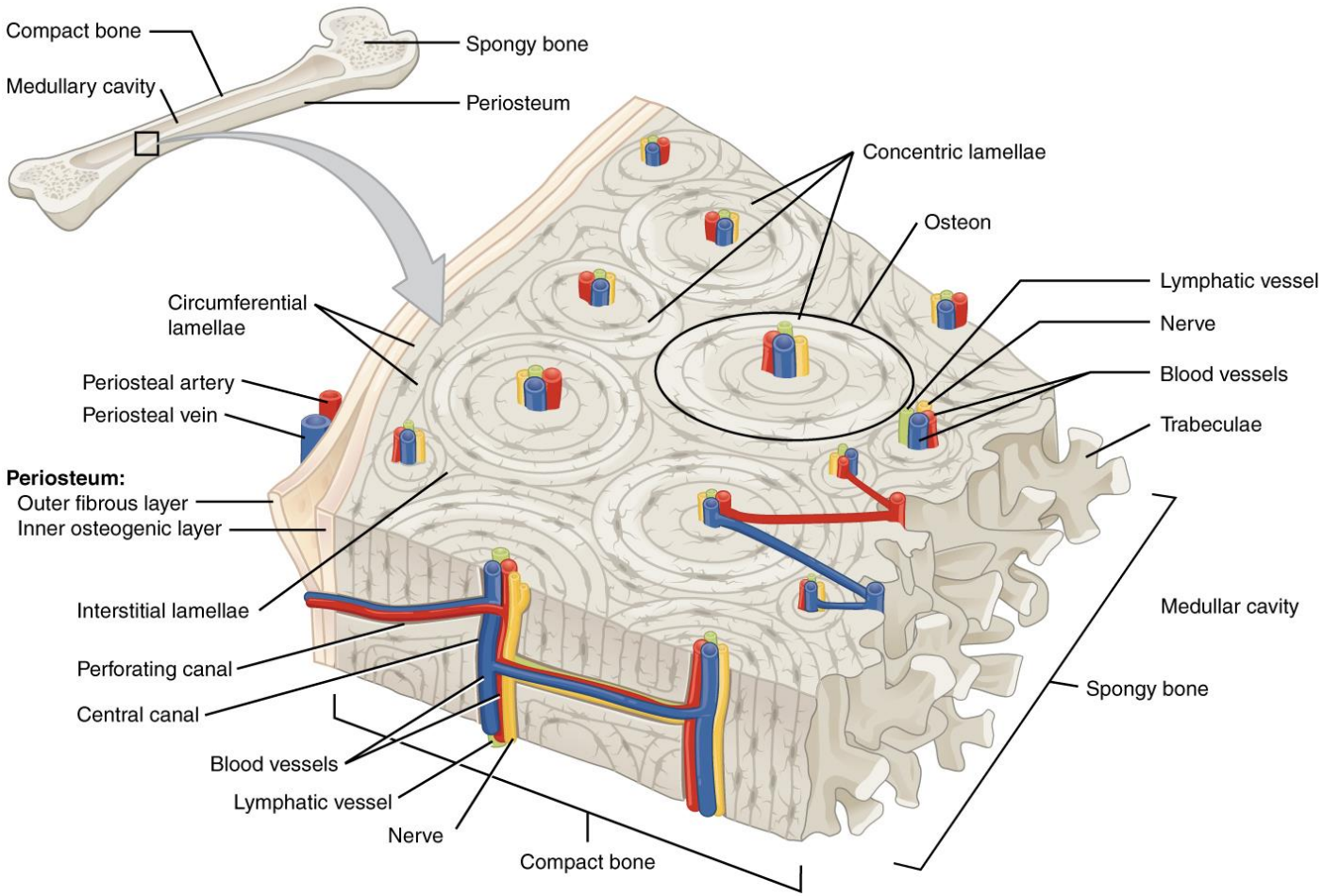

(a)

https://upload.wikimedia.org/wikipedia/commons/5/58/624_Diagram_of_Compact_Bone-new.jpg

Knogletrabekler

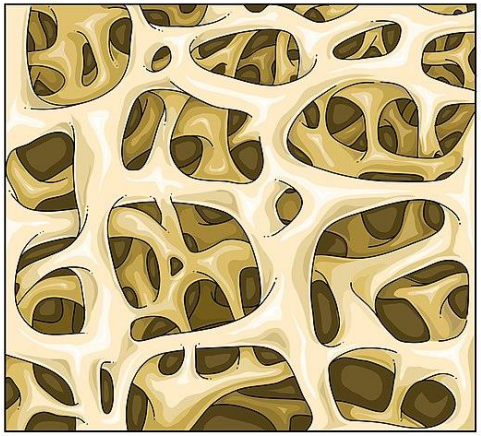

Normal trabecular bone

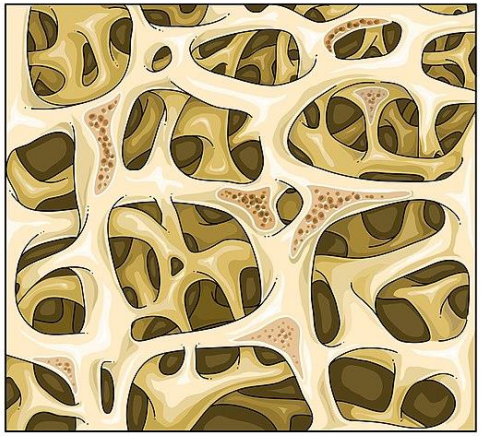

Trabecular bone with resorption areas

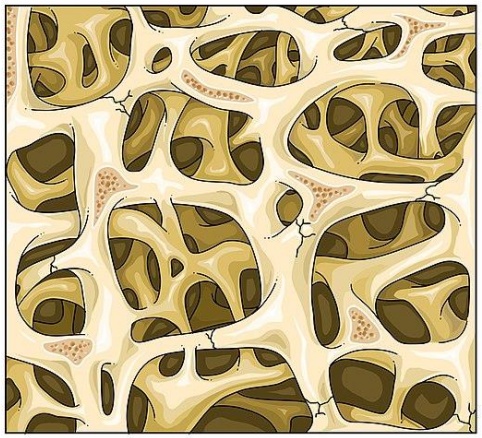

Trabecular bone with microcracks

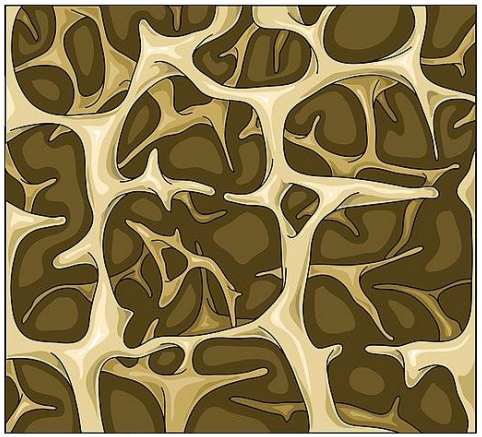

Osteoporotic trabecular bone

Knoglemarv

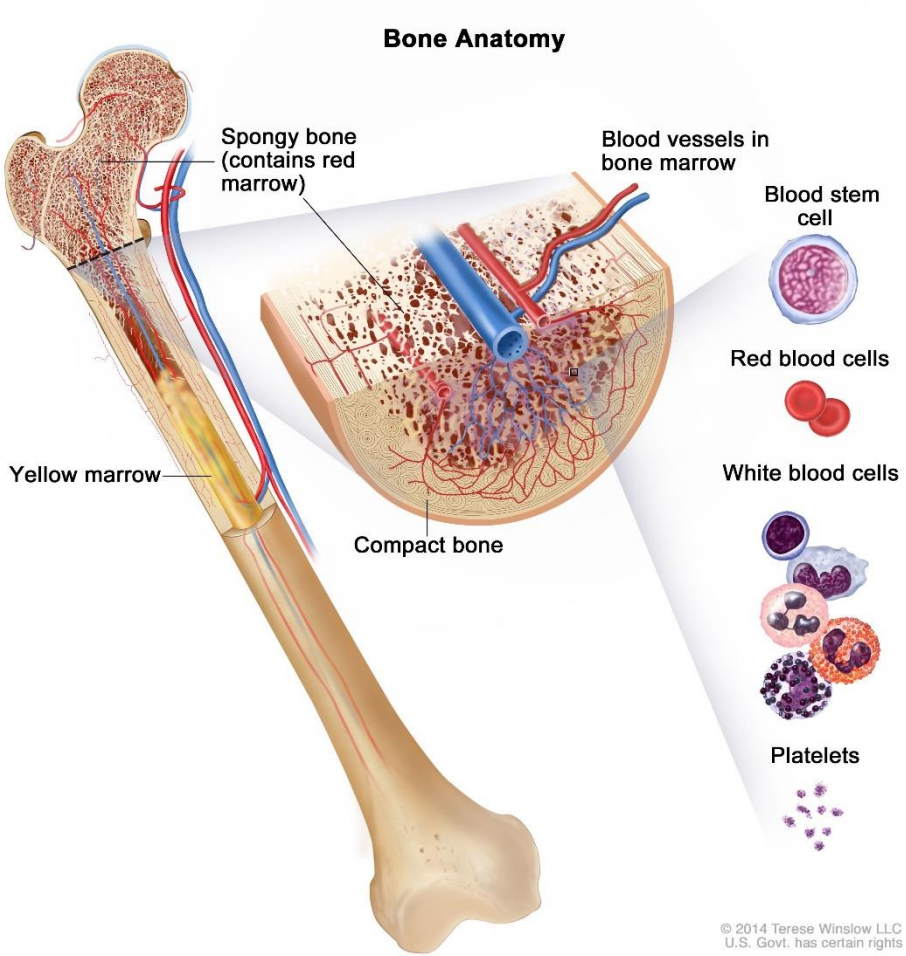

https://nci-media.cancer.gov/pdq/media/images/755927.jpg

Knoglemarvsbiopsi

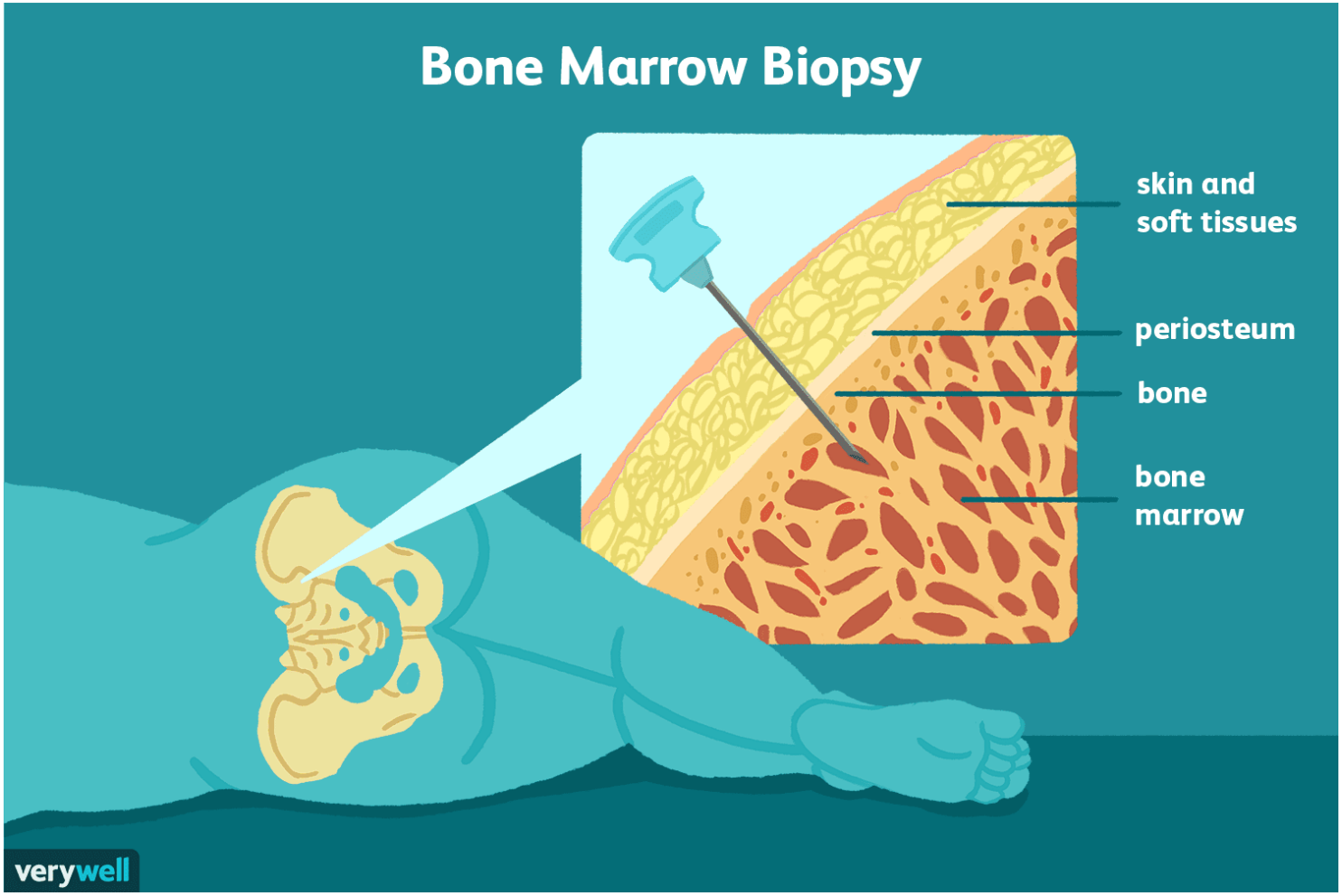

Peerfeedback 2 og 2 - evt 3

Knoglevæv		
Bindevævspræformeret Bruskpræformeret knogle (2)		
Osteoblaster Osteoklaster (2)		
Resorption Apposition (2)		
Osteon Hemiosteon (2)		
Spongiøs knogle Kompakt knogle(2)		

Støttevæv
- bindevæv
- bruskvæv
- benvæv
- blod

BLOD

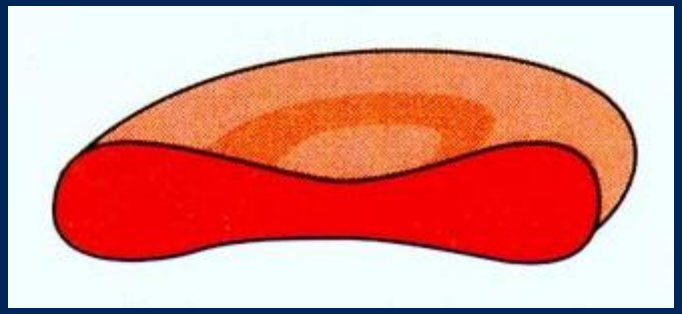

BLOD

- Varetager transport mellem legemets forskellige dele
  - Blodceller
  - flydende grundsubstans

- 55% plasma
- 45% formede bestanddele
  - Røde blodlegemer
  - Hvide blodlegemer
  - Blodplader

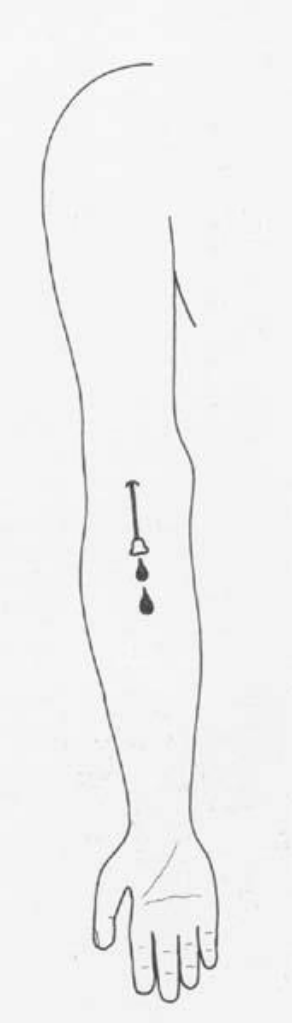

BLODCELLER

- røde blodlegemer (erythrocyter)
- hvide blodlegemer (leukocyter)
- blodplader (thrombocyter)

RØDE BLODLEGEMER

- Erytrocyter
- indeholder hæmoglobin
- er 7-8 µm i diameter
- lever ca. 120 dage

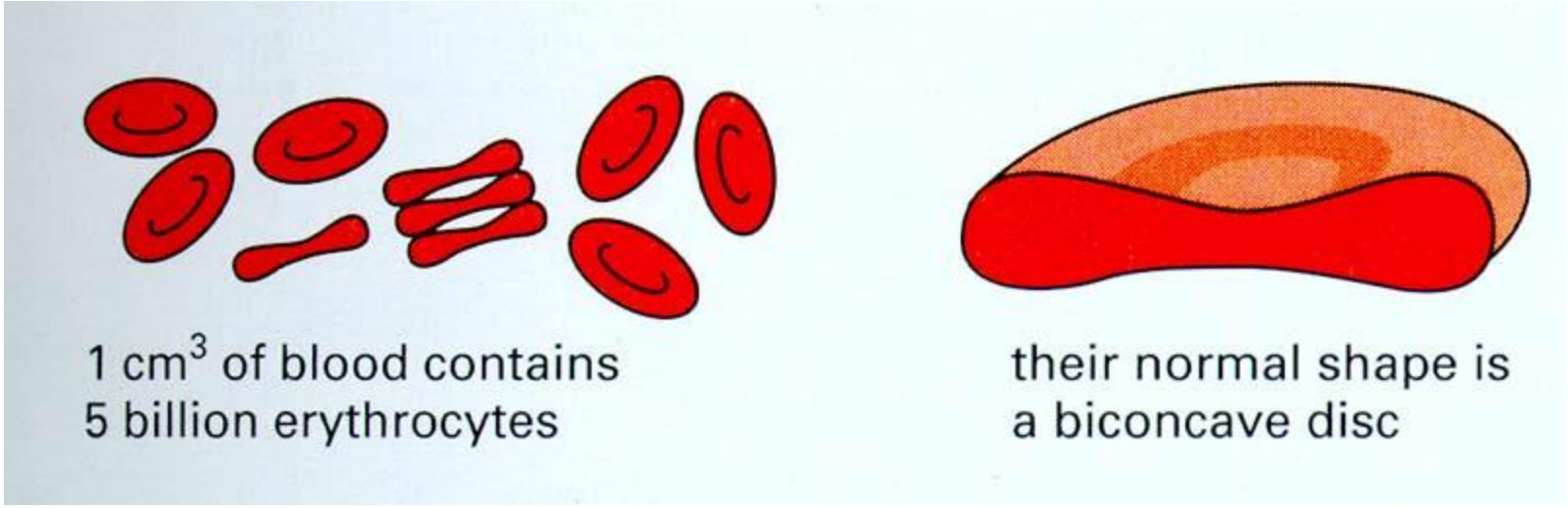

HVIDE BLODLEGEMER

- kan udføre amøboide bevægelser

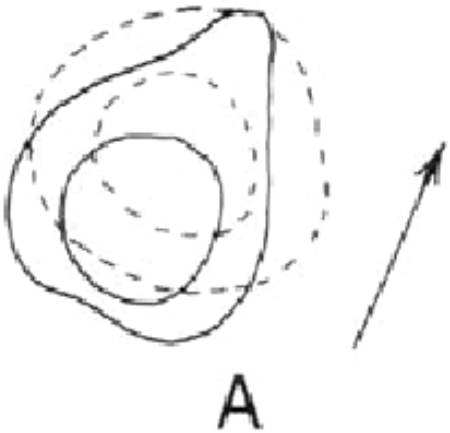

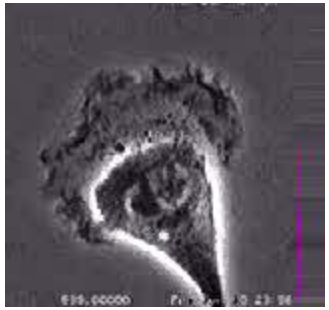

HVIDE BLODLEGEMER

- nogle kan fagocytere

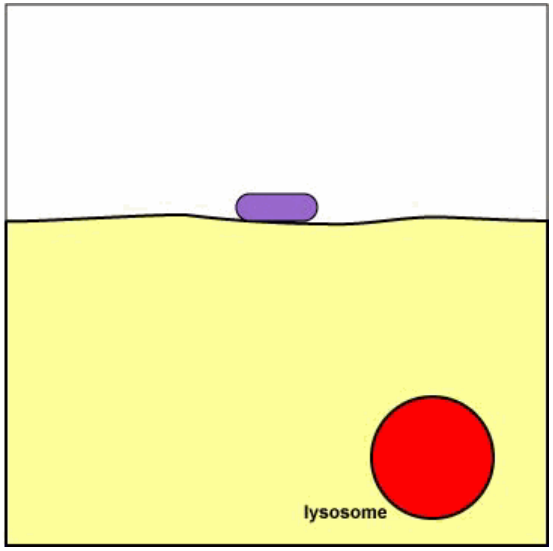

- kaldes fagocyter
  - makrofager, monocyter, neutrofile granulocyter..

Granulocyter

- Granulocyter har granula i cytoplasma
  - neutrofile granulocyter (a)
  - basofile granulocyter (b)
  - eosinofile granulocyter (c)
  - mastcelle

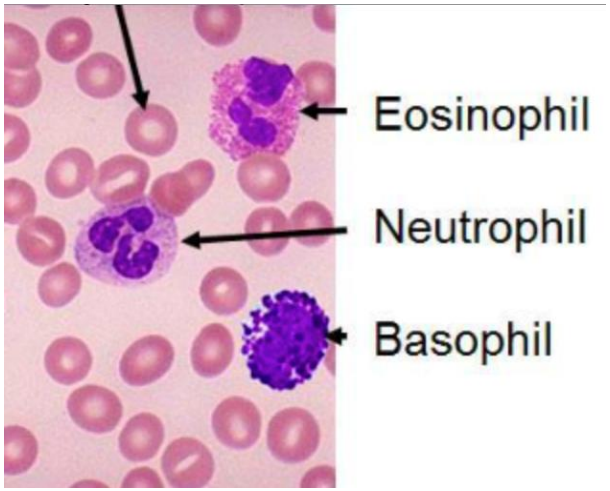



Agranulocyter

- <u>agranulocyter</u> har ikke sådanne granula
  - lymfocyter (d)
  - monocyter (e)
  - thrombocyter (f)

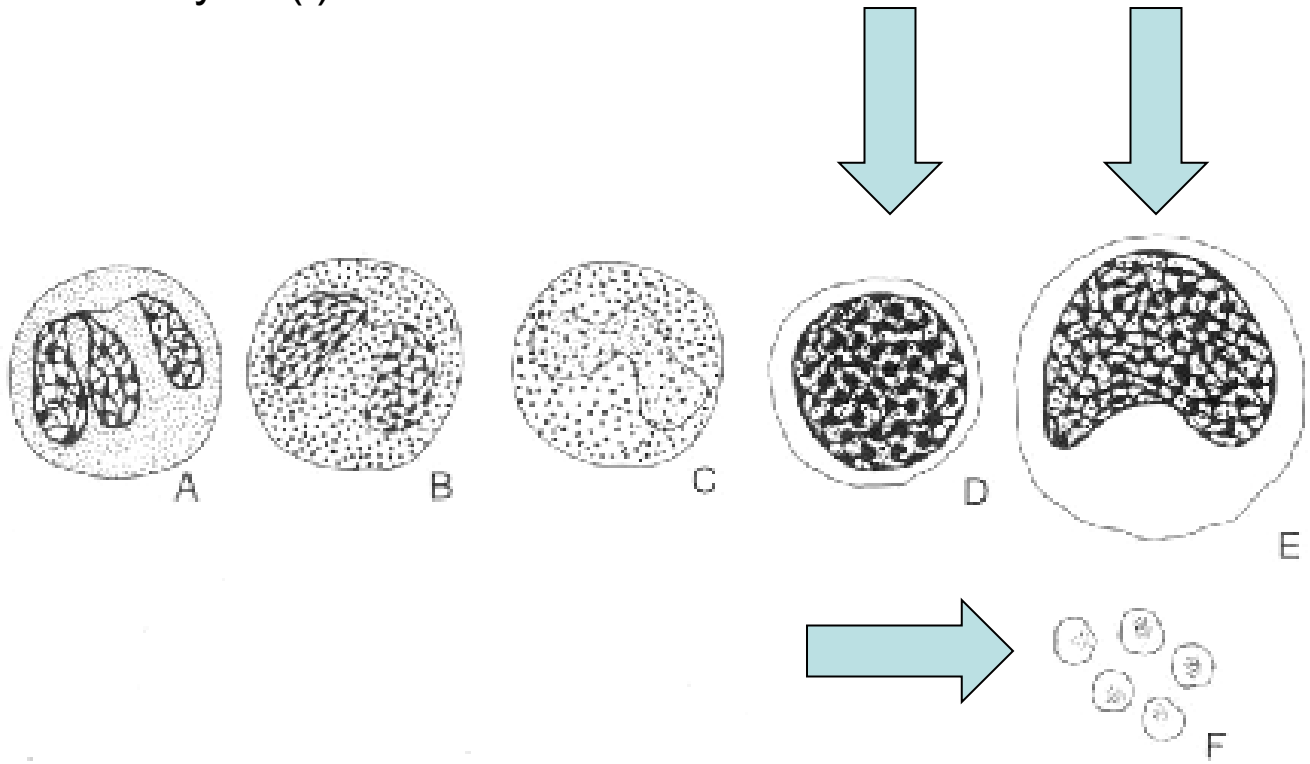

Lymfocyt

- lymfocyt → <u>plasmacelle</u> → antistof

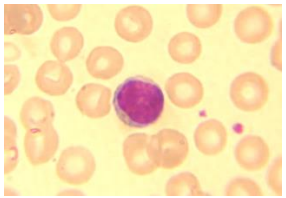

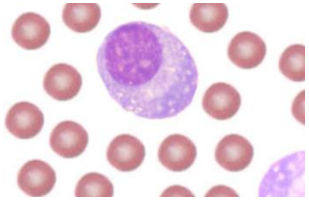

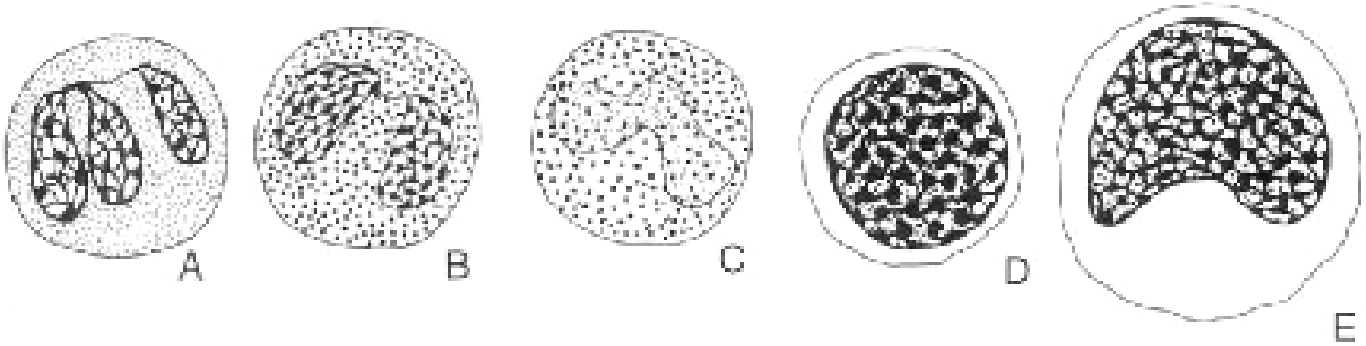

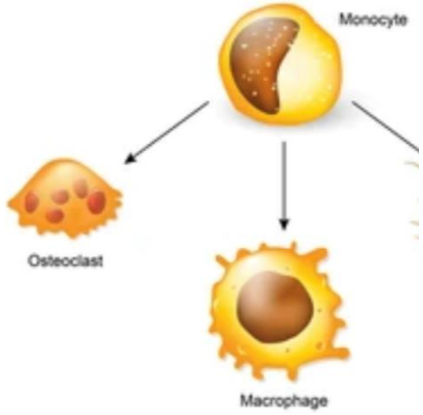

Monocyt

Støttevæv
- bindevæv
- bruskvæv
- benvæv
- blod

- Monocyt → makrofag

↓

- Monocyt → osteoklast (knoglecelle)

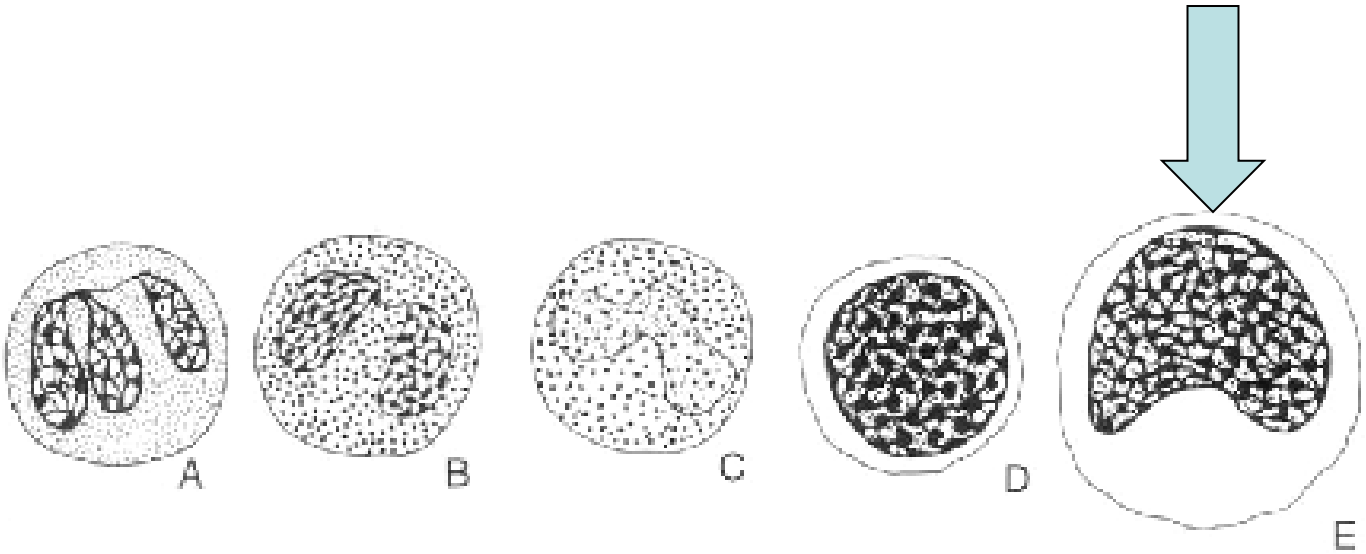

Neutrofil granulocyt

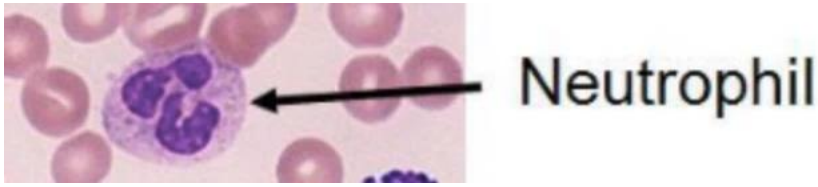

- neutrofile granula i cytoplasmaet

Basofil granulocyt

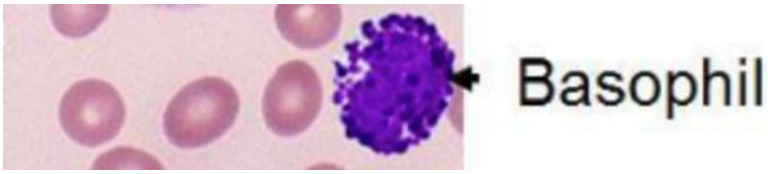

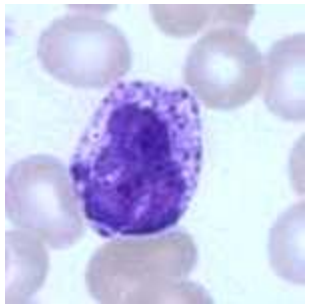

- blå granula i cytoplasma (basofile)

Eosinofil granulocyt

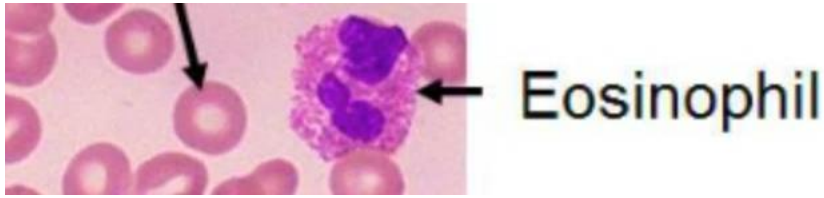

- store røde (eosinofile) granula i cytoplasma

Cellulært bindevæv

- ses i lymfeknuder og rød knoglemarv
- vævet indeholder:
  - frie celler (1)
  - reticulumceller (2)
  - retikulintråde (3)

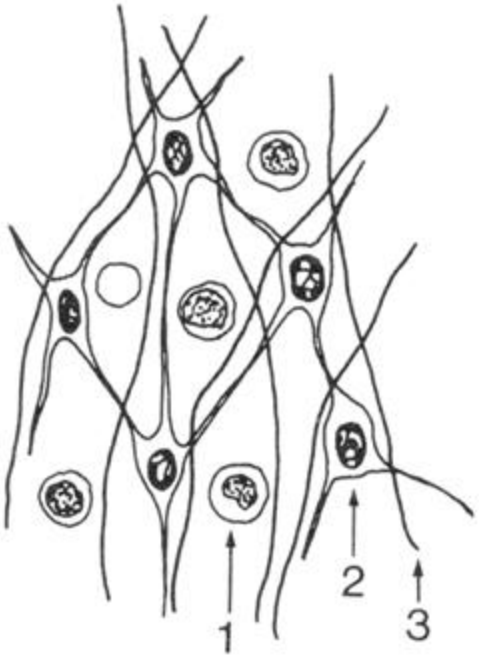

Lymfe

- cellefri væske fra væv
- lymfekar
- lymfeknuder
- iblandes her lymfocyter

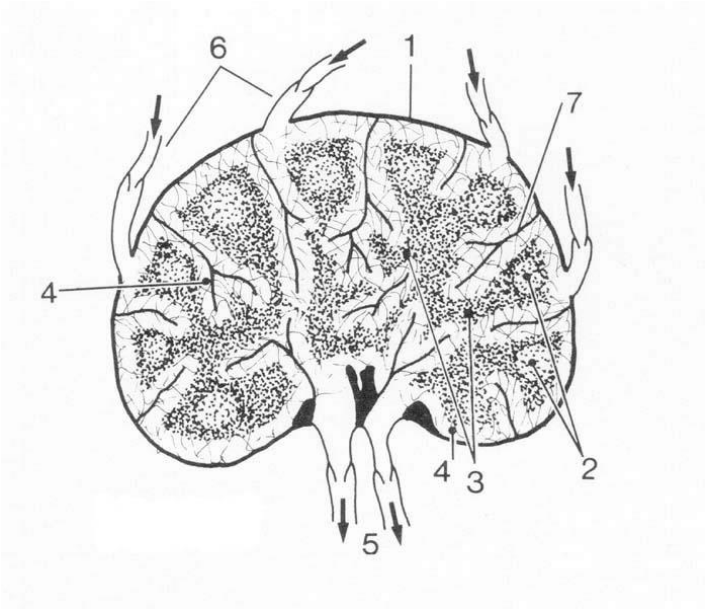

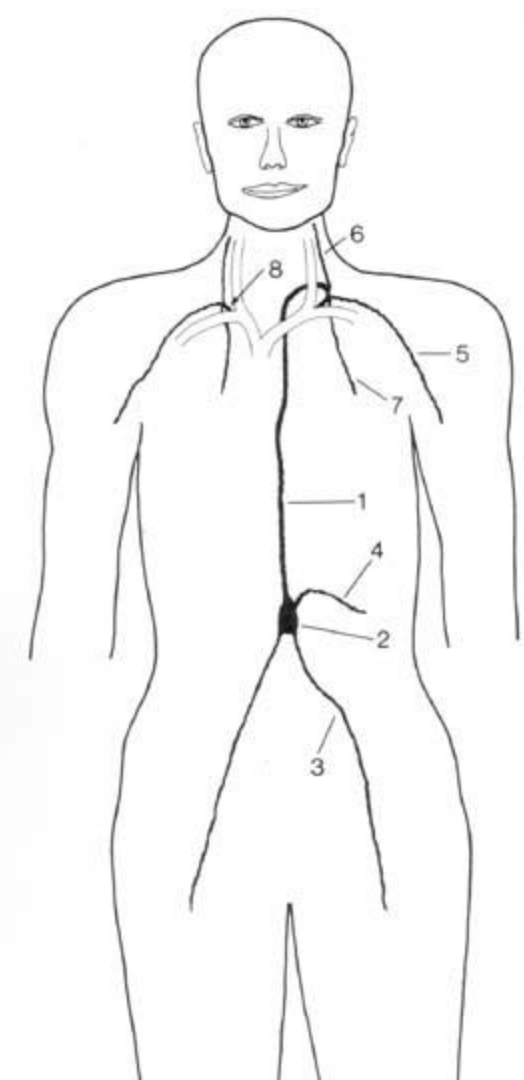

Hæmopoiese (bloddannelse)

- En stamcelle i knoglemarven “hæmacytoblast” bliver til <u>alle</u> blodceller

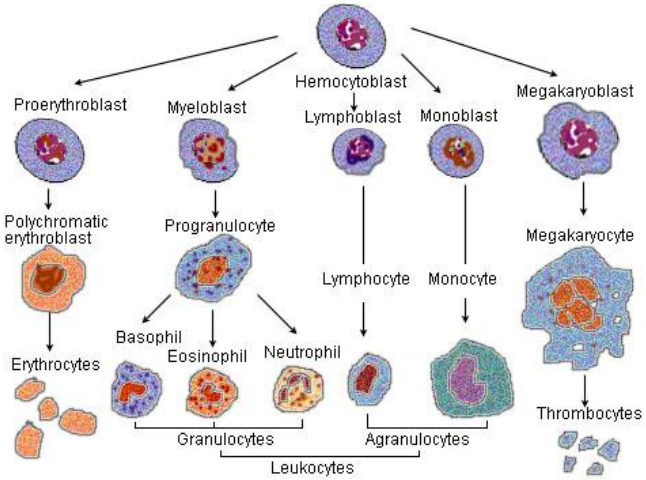

Hæmopoiese

- Multipotent stamcelle i knoglemarven, “hæmacytoblast” bliver til alle blodceller
  - Nogle bliver til røde blodlegemer via erythroblaststadiet
  - Nogle bliver til granulocyter via myelocytstadier

- Megakaryocyter:
  - afsnører blodplader

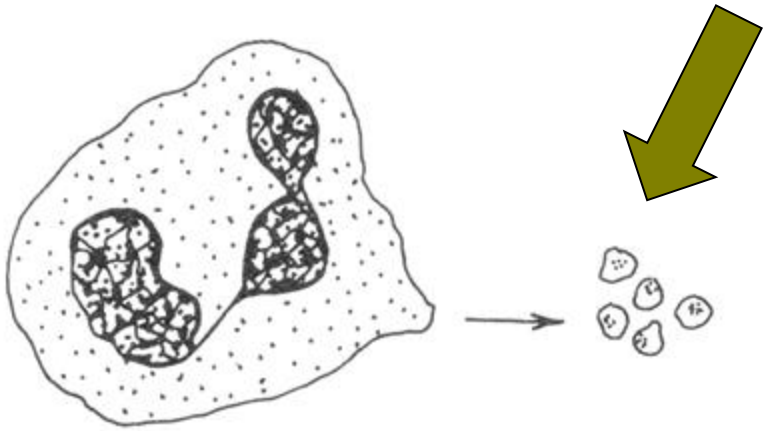

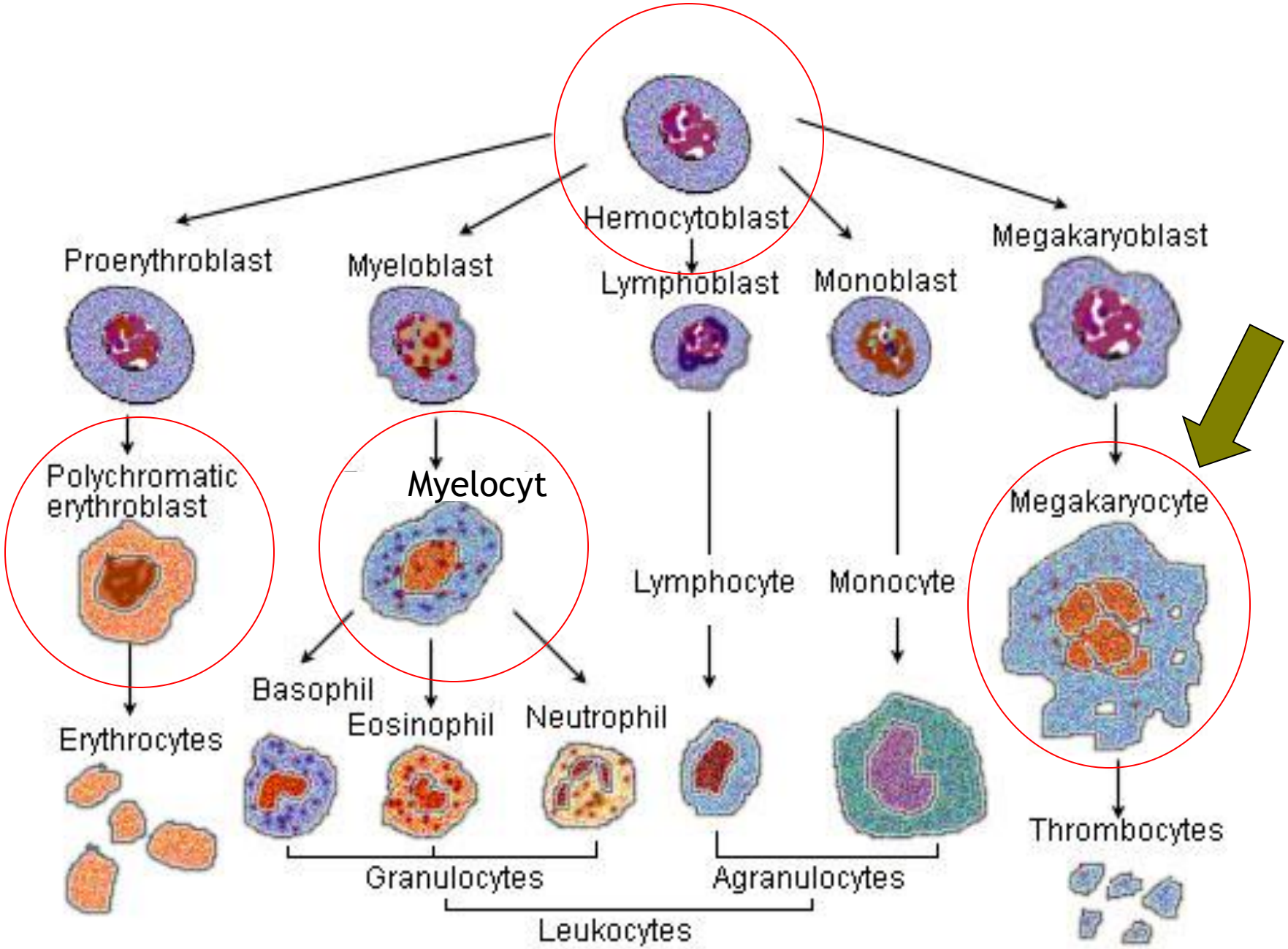
Hemocytoblast
Proerythroblast
Myeloblast
Lymphoblast
Monoblast
Megakaryoblast
Polychromatic erythroblast
Myelocyt
Lymphocyte
Monocyte
Megakaryocyte
Basophil
Eosinophil
Neutrophil
Erythrocytes
Thrombocytes
Granulocytes
Agranulocytes
Leukocytes

IOOS, AU

Stamceller er ‘pluripotente’
dvs de kan blive til flere celletyper

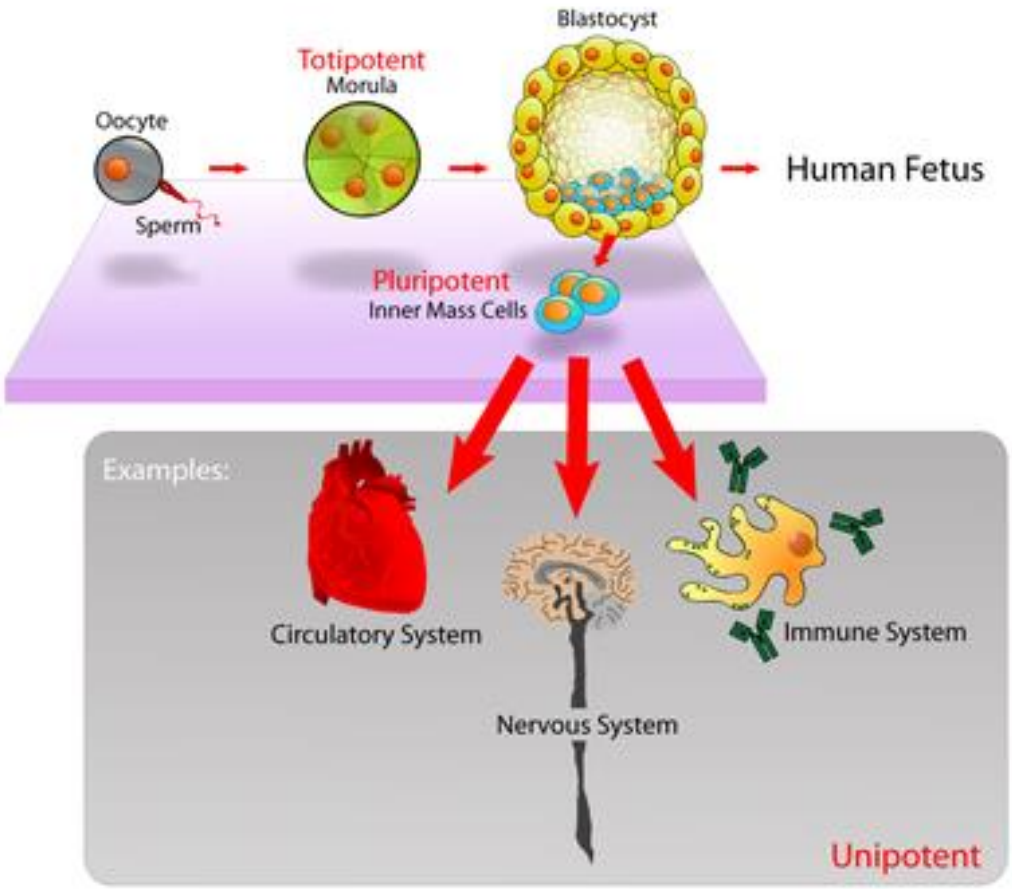

vi har bloddannede væv

- i knoglemarv
  - frie celler
    - umodne/modne
    - røde/hvide

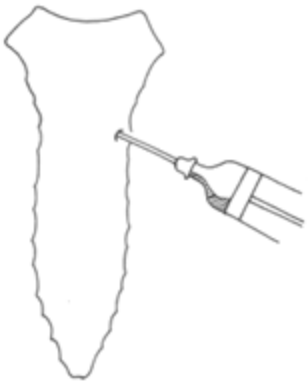

- fostre danner blodlegemer:
  - først i mesenchym
  - dernæst i lever og milt
  - endelig i knoglemarv og lymfeknuder

Peerfeedback 2 og 2 - evt 3

Blod		
Blodceller (3)		
Granulocyter (4)		
Agranulocyter (3)		
En monocyt kan blive til .. (2)		
En osteoclast kan dannes af.. (2)		
Hæmocytoblast kan danne.. ..		
Myelocyt kan danne..		
Megacaryocyt kan danne..		

Blod % i bog

- Blod %'er differential-tællinger af hvide blodlegemer

NERVEVÆV
- vævslære

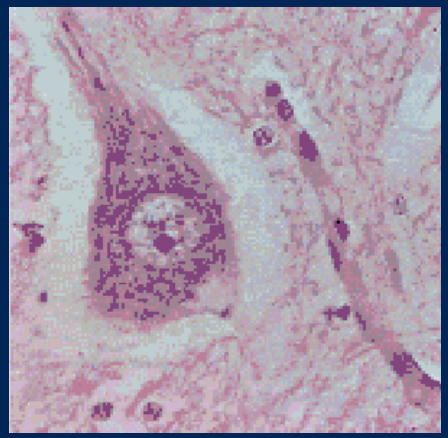

AARHUS
UNIVERSITET
INSTITUT FOR ODONTOLOGI OG ORAL SUNDHED

NERVEVÆV

- veludviklet ledningsevne

- bl a neuroner

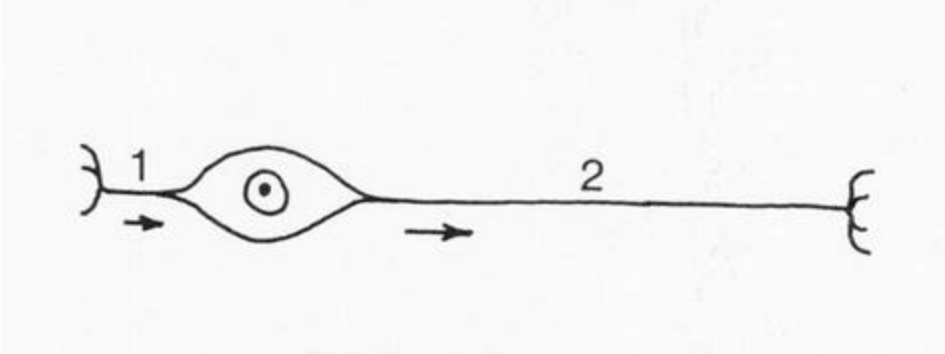

Hvad består nervevæv af?

- Centralnervesystemet
  - neuroner
  - neuroglia (specielt støttevæv)
- Det perifere nervesystem
  - neuroner
  - nerver (bundter af nervetråde)
  - ganglier (hobe af nervecellelegemer)
  - perifere nerveender

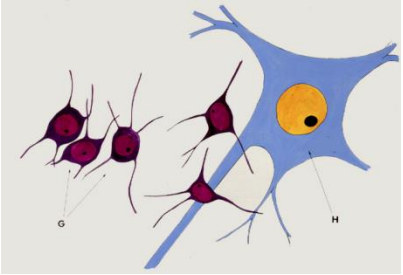

Hvad er en neuron?

- det er en nervecelle med samtlige udløbere

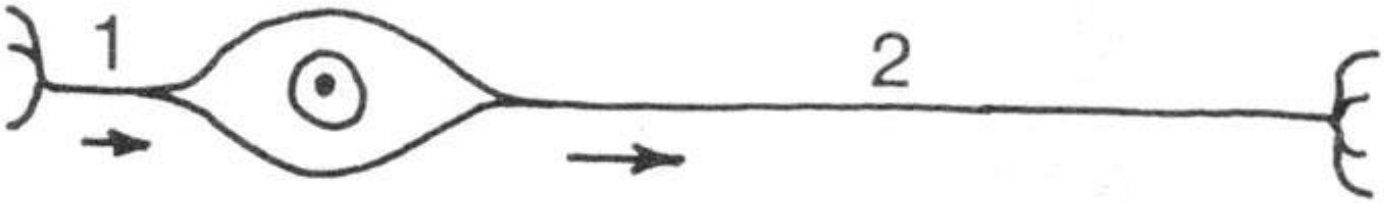

Neuron

- funktionel enhed i nervesystemet
- egenskaber:
  - irritabilitet
  - leder impulser (konduktivitet)

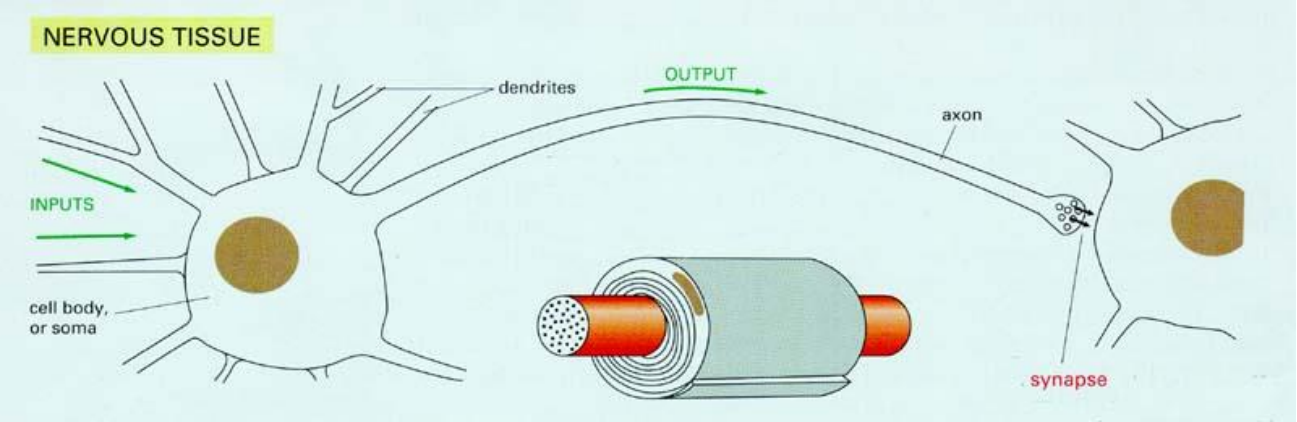

Neuroners udløbere

- (D) Dendritter
- (N) Neurit

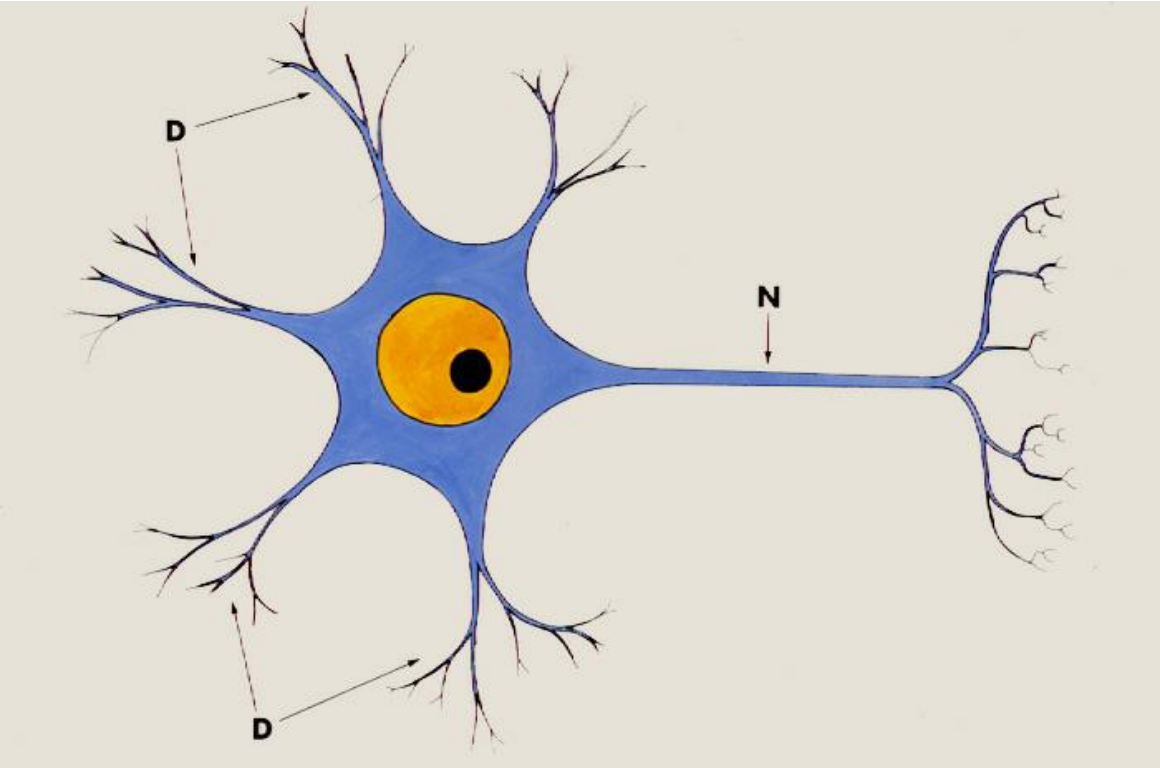

Dendrit

- udløber/e
- fører impulser
- mod nervecellelegemet

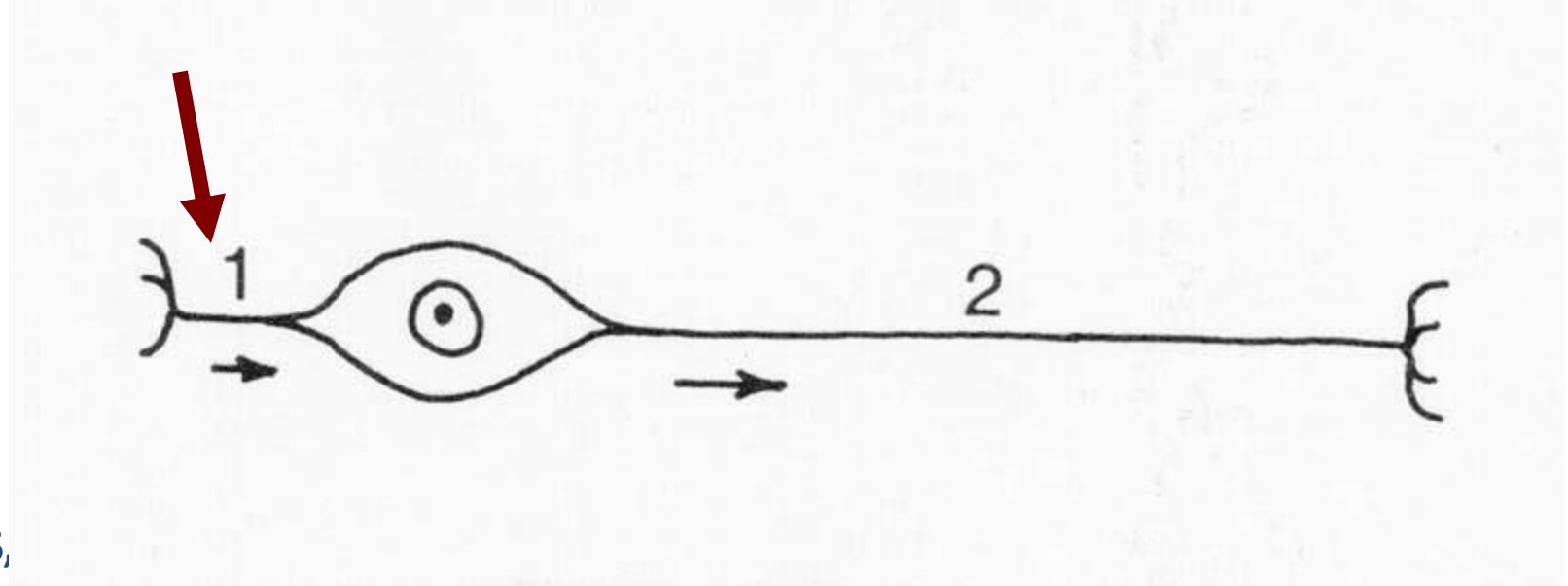

Neurit

- én udløber
- fører impulser
- væk fra nervecellelegemet

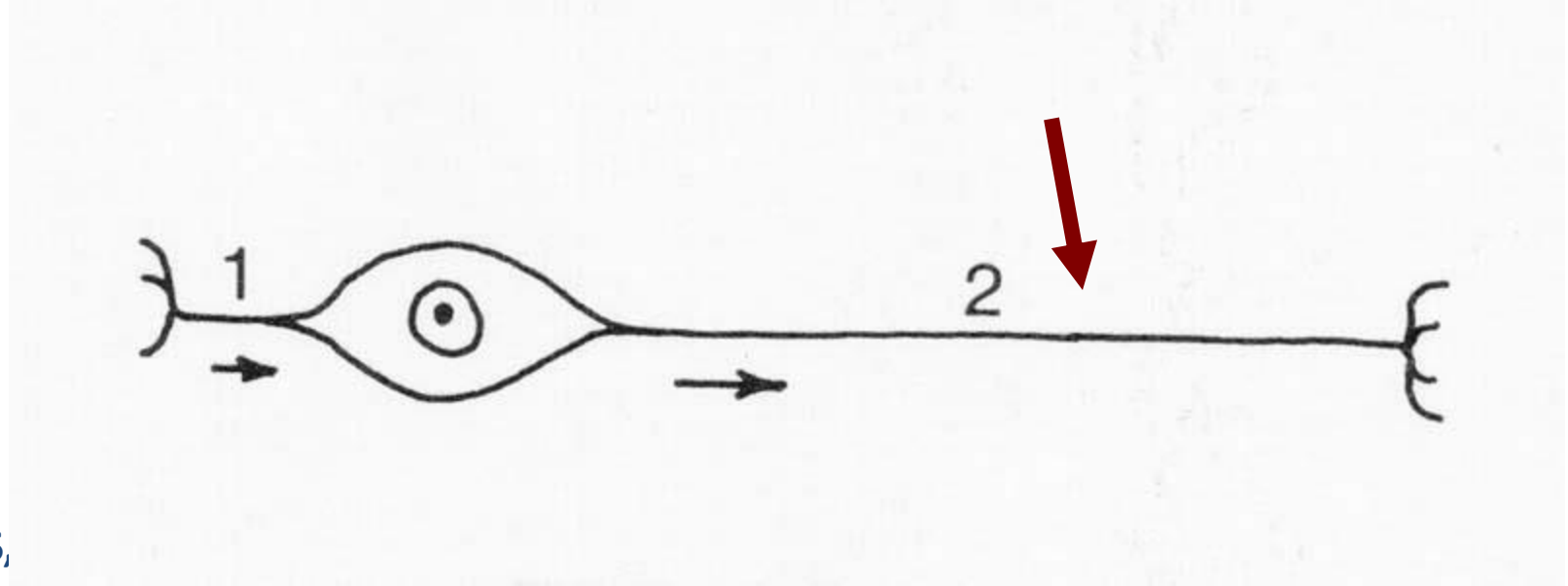

Axon*

- længste udløber
- uanset impuls retning

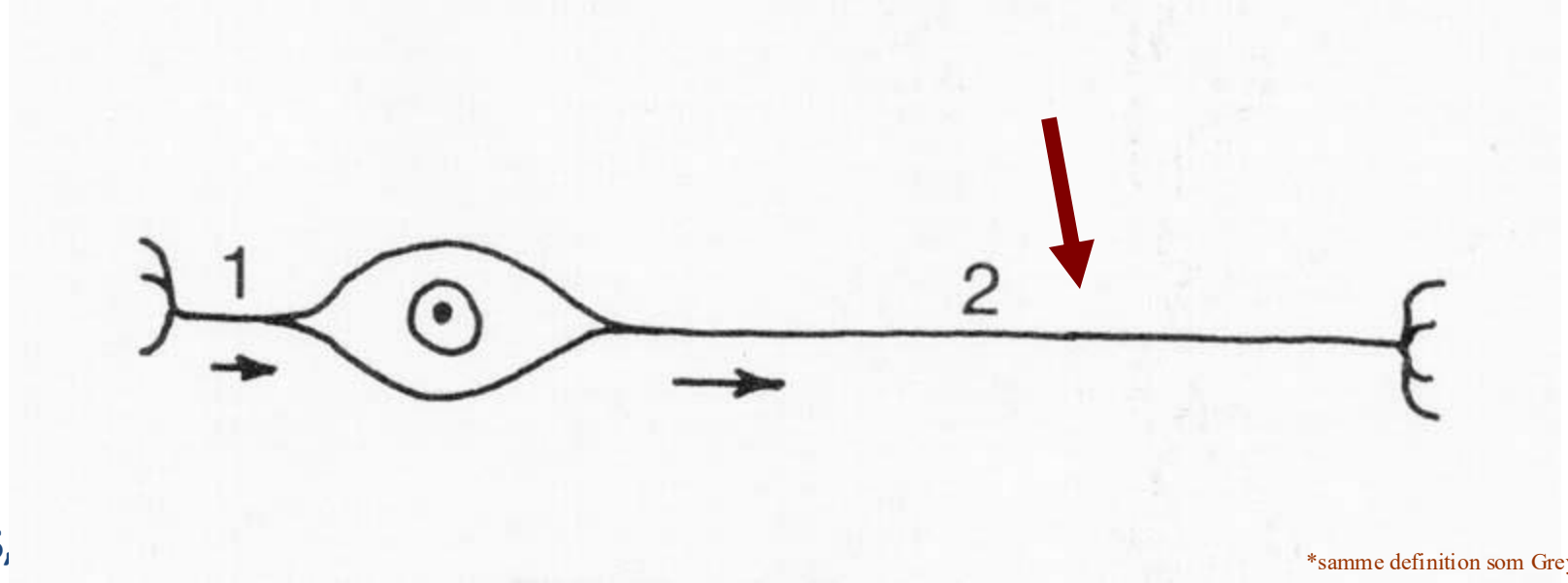

*samme definition som Grey

Cellelegemet

- trofisk centrum (ernæringsmæssigt)

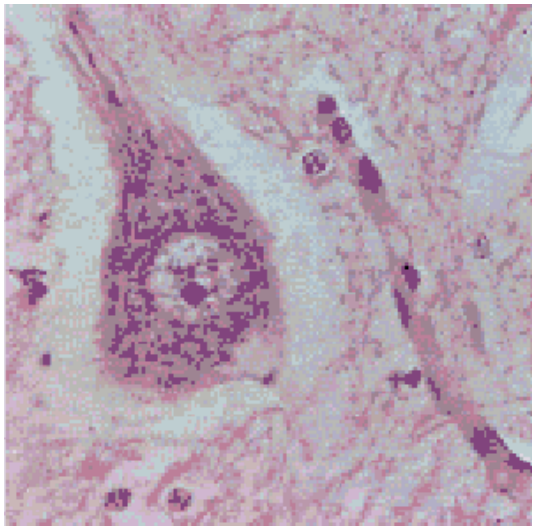

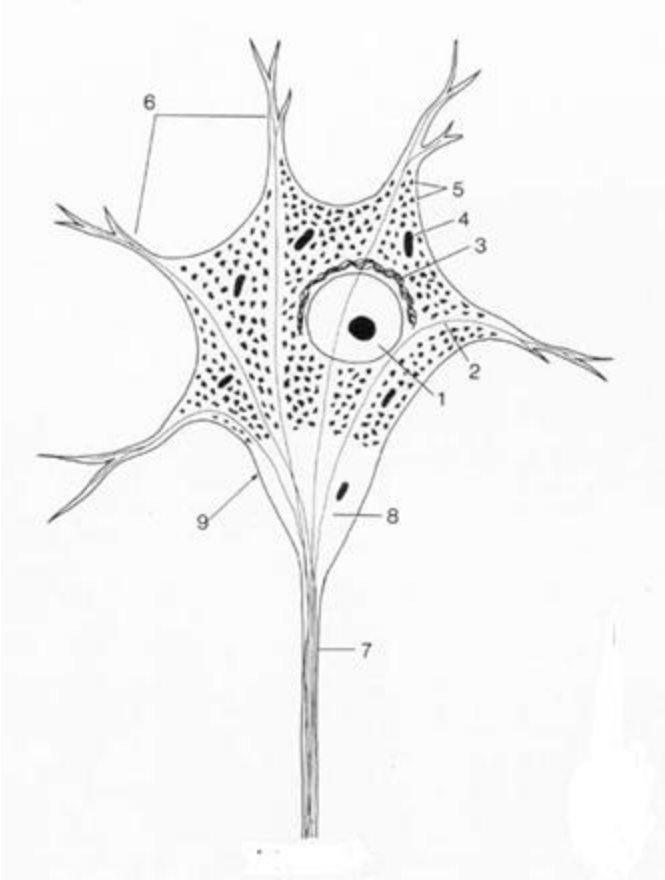

Neuroners form

a. Unipolær
b. Bipolær
c. Multipolær
d. Pseudounipolær

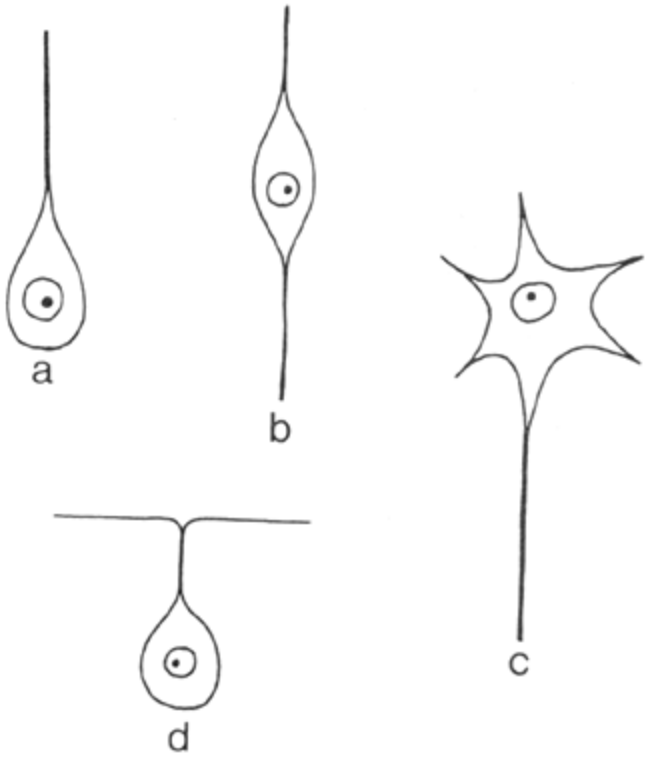

Neuroners form

- Unipolar en udløber
- Bipolar to udløbere
- Multipolar mange udløbere
- Pseudounipolar en udløber som deler sig

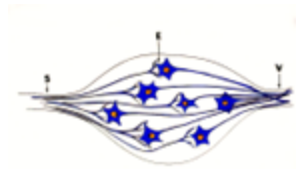

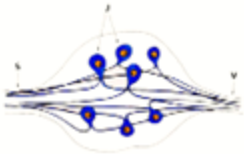

Neuroner – funktionel inddeling

- Receptor-celler
- Effektor-celler
- Integratorer

Receptorcellen

Modtager:

- **eksteroceptive** impulser fra overflader
- **interoceptive** impulser fra organer og kar
- **proprioceptive** impulser fra muskler, sener, ligamenter, led og tænder

Effektorcellen

Sender:

- *motoriske* impulser til muskler
- *sekretoriske* til kirtler

Integratorer

Receptor-celler
Effektor-celler
Integratorer

Modtager og sender:

- impulser fra receptorceller
- til effektorceller

Neuron

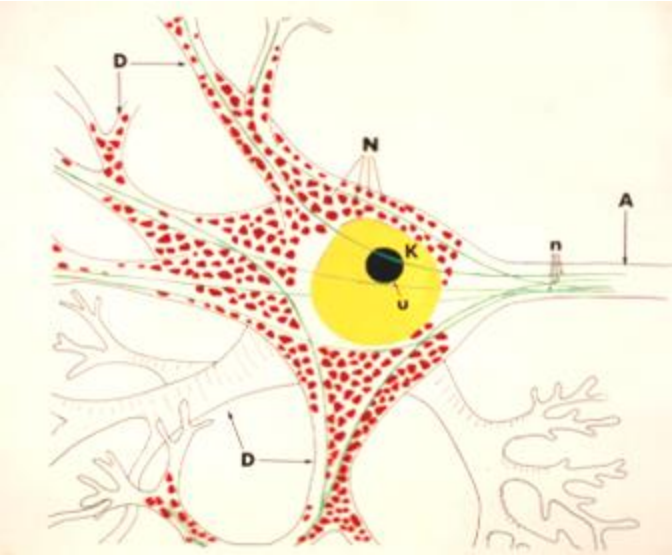

- kernen er lys (har nucleolus)
- Nissl´s substans (rER)
- neurofibriller (sv t intermed. filamenter)
- mikrotubuli (transportprocesser)
- Golgiapparatet (bl a neurotransmittere)

Dendritter

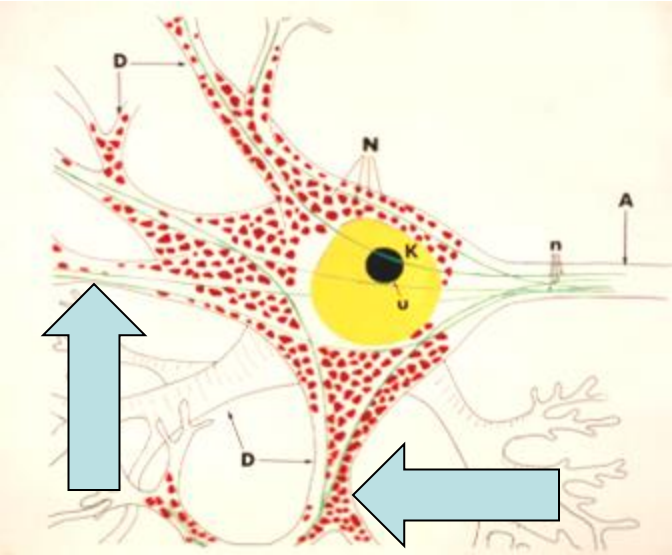

- korte
- forgrenede
- fortsættelse af cellelegemet
- indeholder Nissl's substans

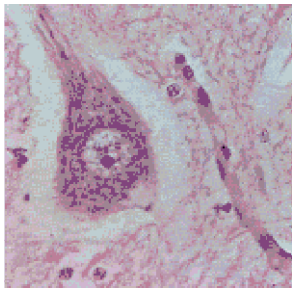

Neurit

- aksecylinder

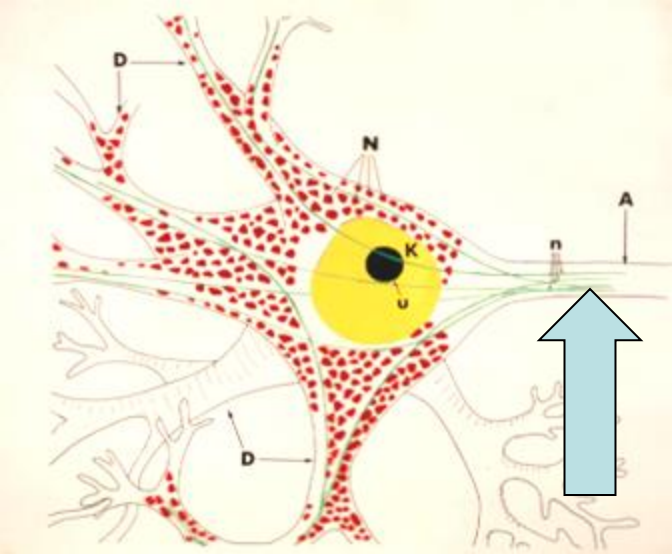

Neurit

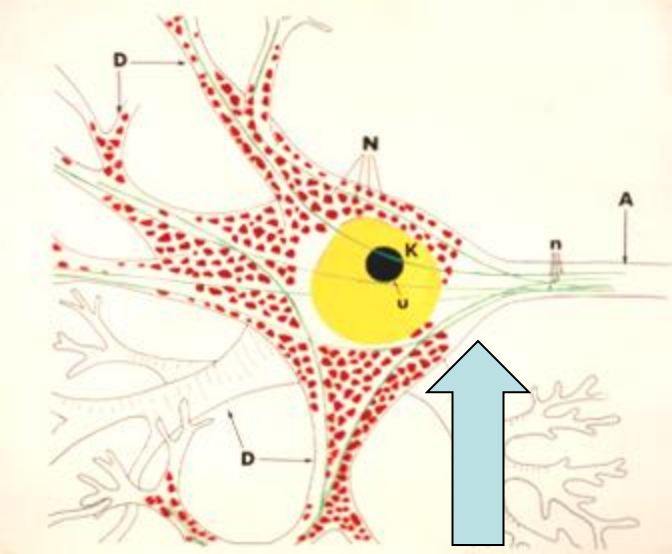

- aksecylinder
- udspringskegle
    - aksoplasma
    - neurofibriller
    - mikrotubuli
    - mitokondrier

Nervetråd

- axon

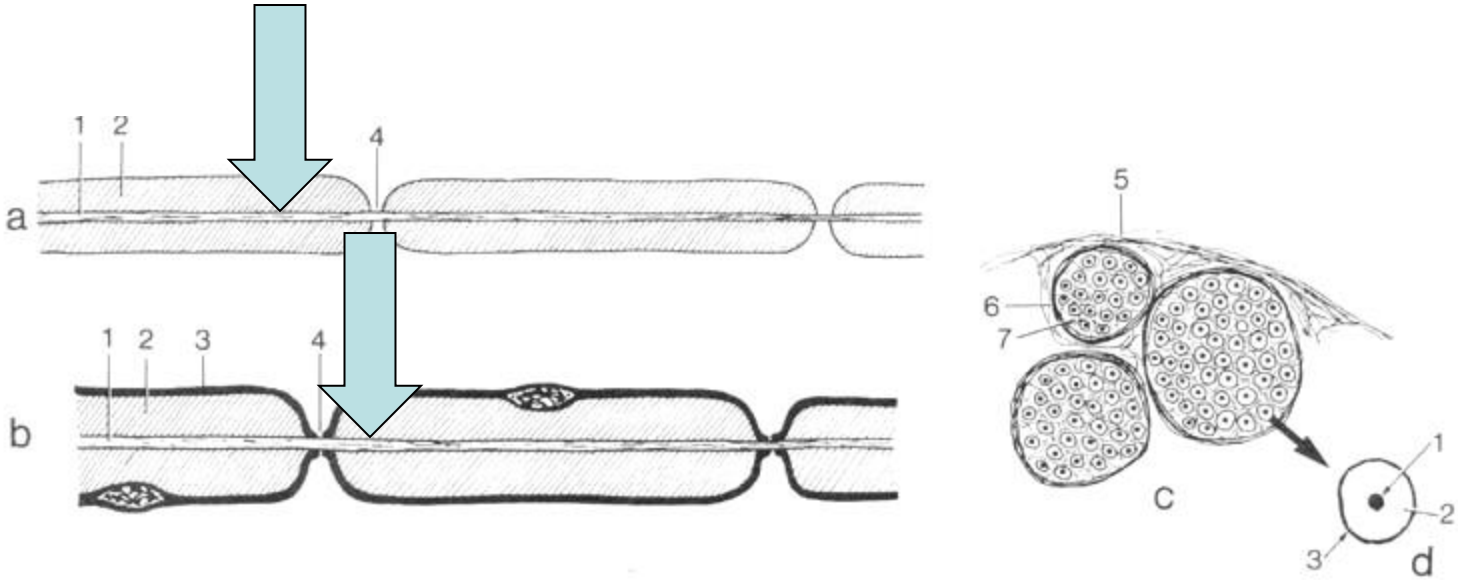

Nervetråd

- axon
- <u>myelinskede</u>

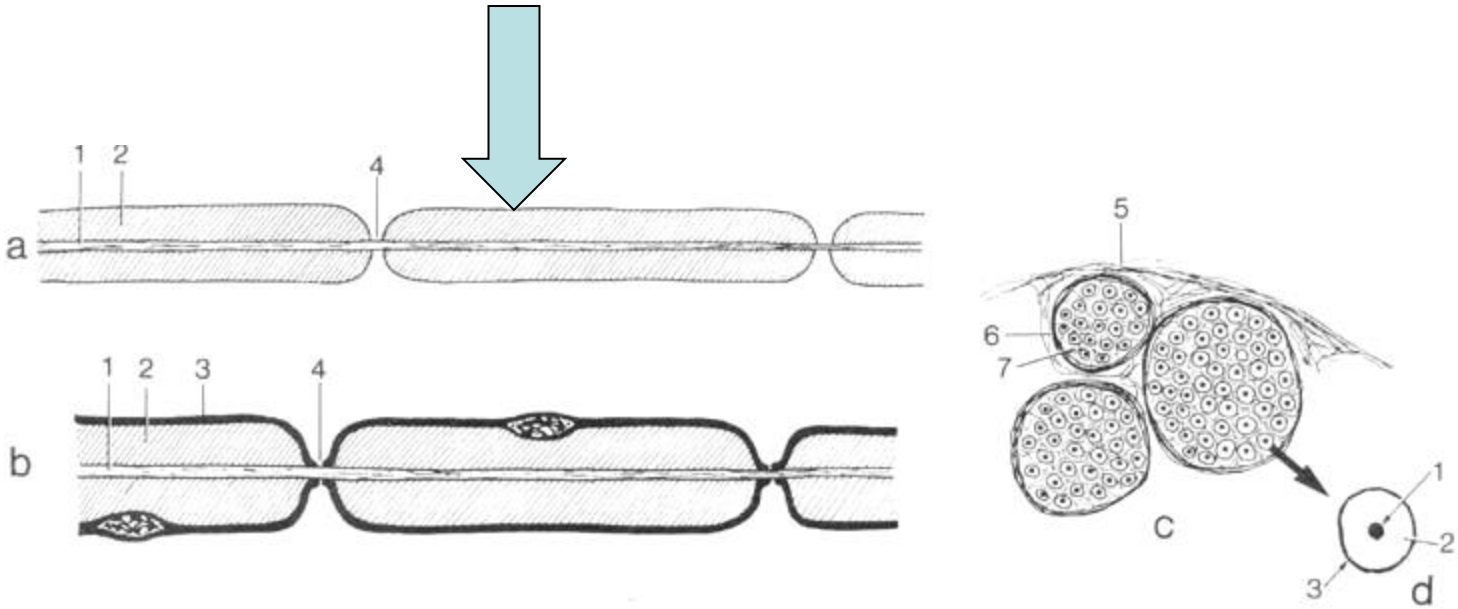

Nervetråd

- axon
- myelinskede
- <u>Schwanns celle</u>

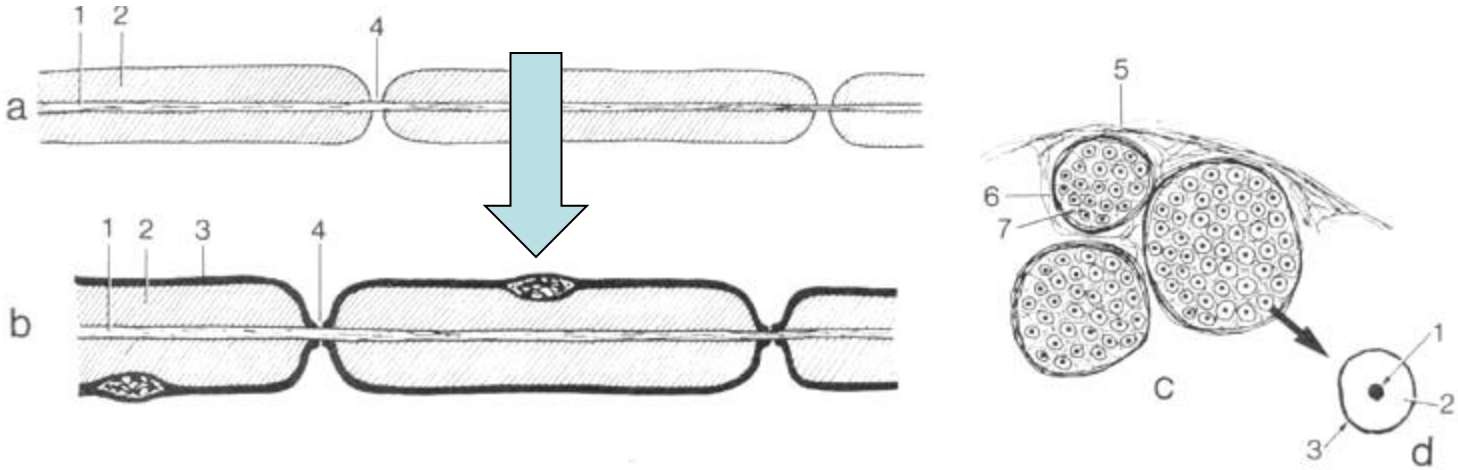

Nervetråd

- axon
- myelinskede
- Schwanns celle
- <u>Neurilemna</u> – ydre celledel omkring myelin

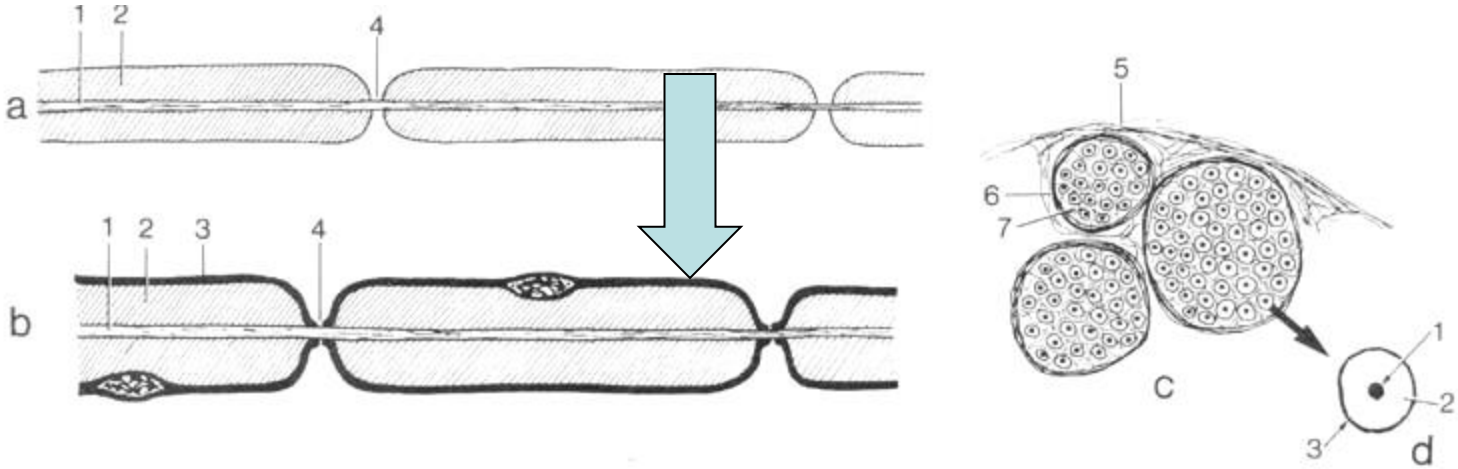

Tværsnit af axon

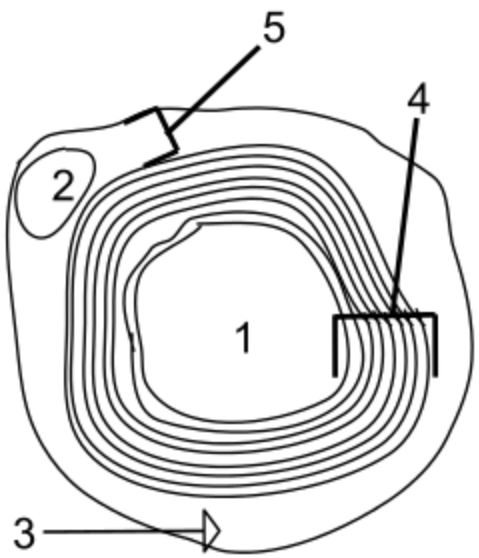

1. Axon
2. Kerne
3. Schwanns celle
4. Myelinskede
5. Neurilemma (Schwans skede)

Schwanns celle

- rørformede
- omkring axon
- danner myelin
- i perifere nerver

Myelinskede

- lipidholdig marvskede
  - dannet af Schwanns cellers membraner viklet tæt omkring axonet i PNS (dannet af oligodendrocyter i CNS)

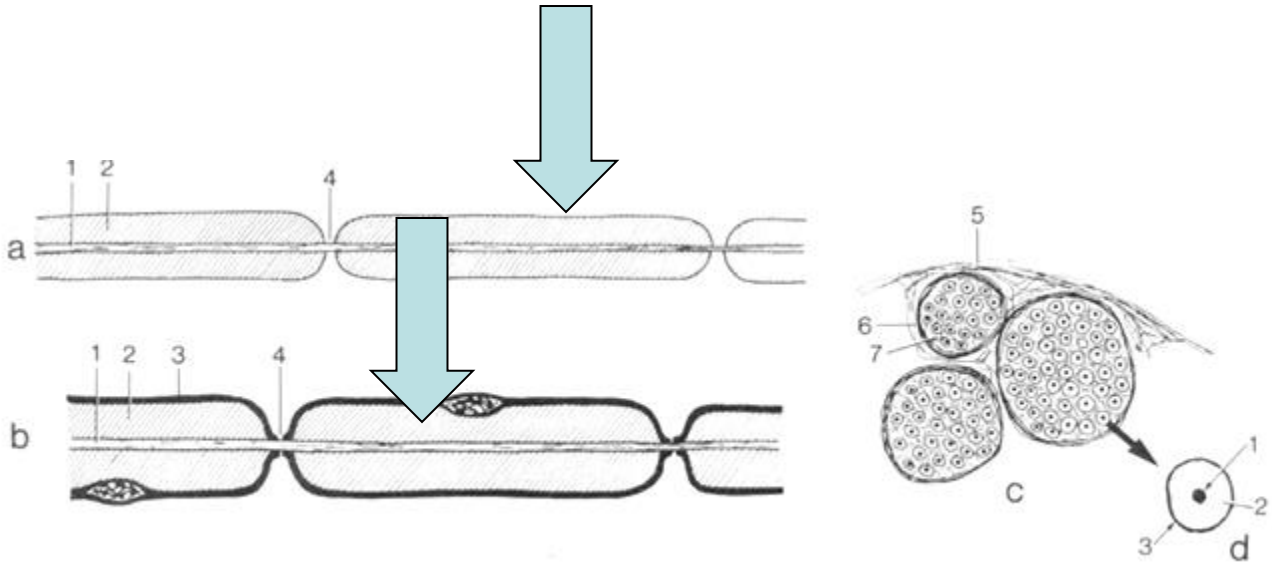

Peerfeedback 2 og 2 - evt 3

Nervevæv (1)		
En simpel myeliniseret nervetråd indeholder 'lag' (4)		
Neuroners form (4)		
Neuroner - funktionel inddeling (3)		
Effektor cellers impulser (2)		

Nerveimpuls

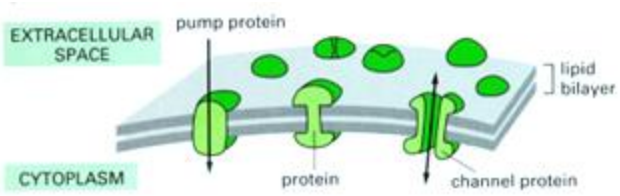

- membranpumper
- opbygger electrokemiske gradienter

Nerveimpuls

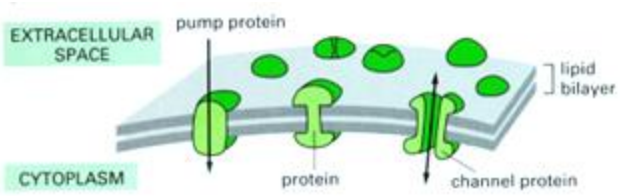

- membranpumper
- opbygger elektrokemiske gradienter
- der kan depolariseres



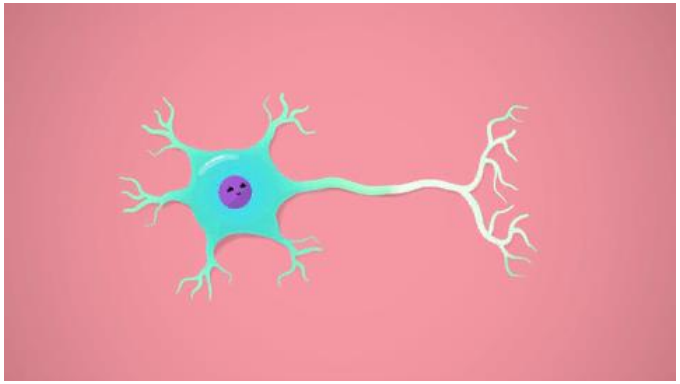

Myeliniserede nerver -har ranviers indsnøringer

- Axon'et har blottet overflademembran i Ranviers indsnøringer

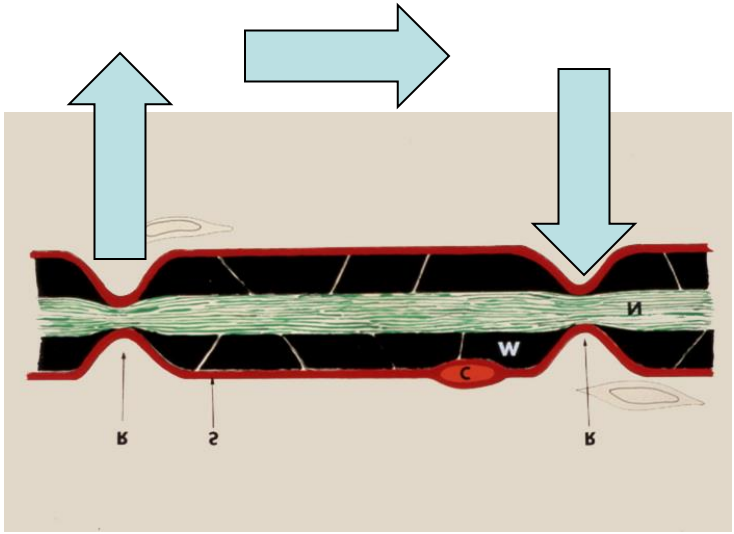

Myeliniserede nerver
-har ranviers indsnøringer

- Axon'et har blottet overflademembran i Ranviers indsnøringer
- Lokal depolarisering (ændret spænding) påvirker membrane længere fremme og udløser depolarisering (voltage-gated channels) - impulsledning bliver saltatorisk

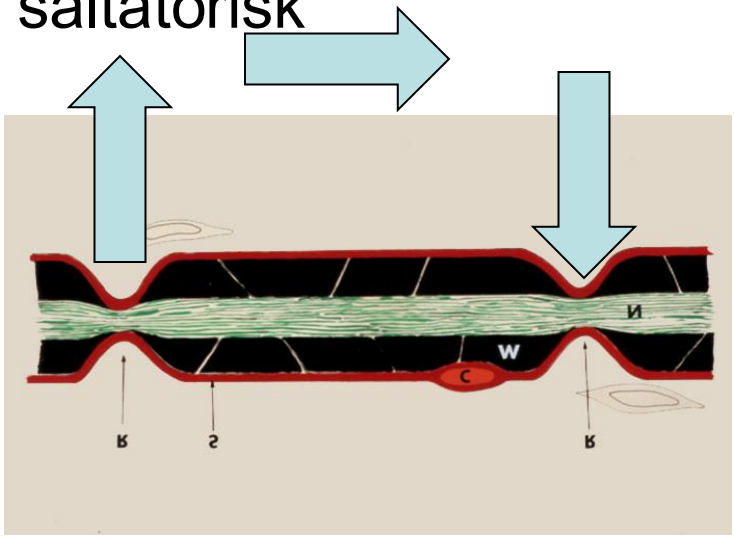

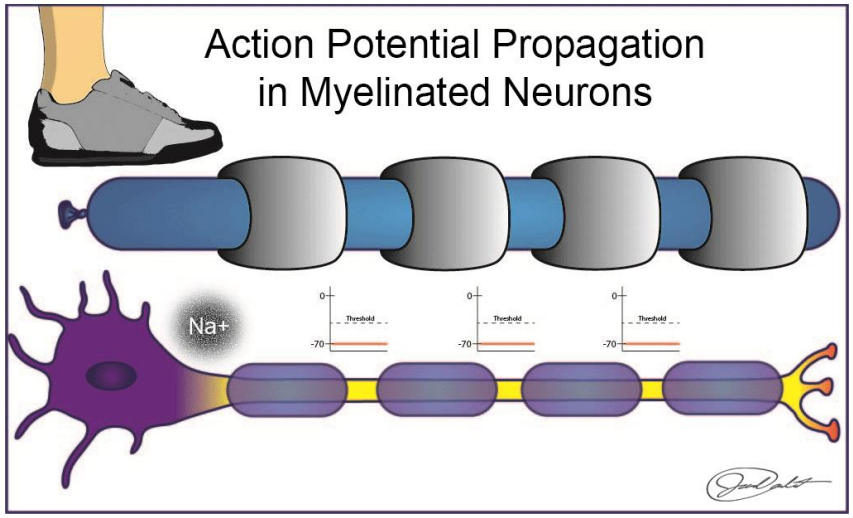

https://content.byui.edu/file/a236934c-3c60-4fe9-90aa-d343b3e3a640/1/module5/readings/refractory_periods.html

Ledningshastighed

nervetyper		m/s	tykkelse
• type A	tykke	15 -100	20 µm
• type B	tyndere	3 - 15	3 µm
• type C	tyndest	0,5- 2	0,3 µm

jo tykkere nerve

jo større ledningshastighed

Overskæring af axon (1)

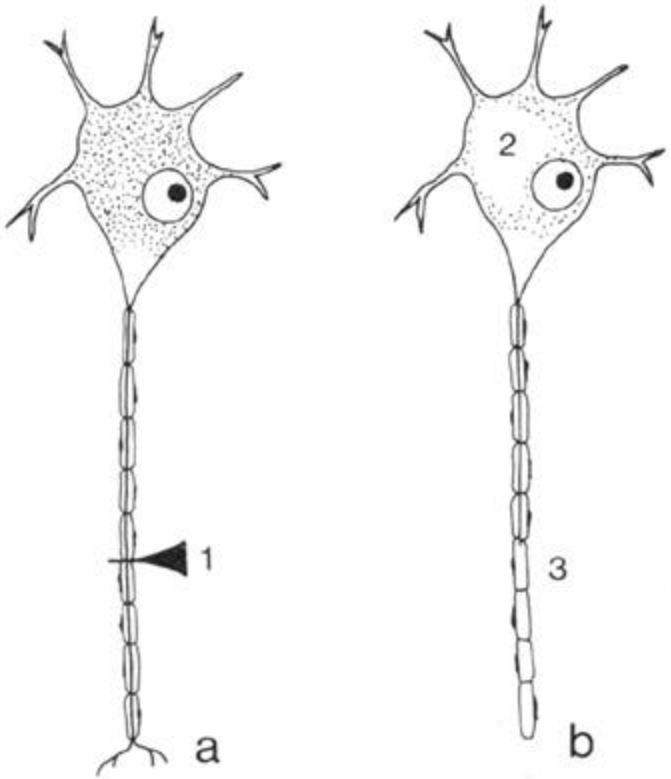

- kromatolyse af Nissl's substans (2)
- afskårne del ændrer farve (3)
- afskårne axon med myelinskede forsvinder (3)
- Schwanns celler overlever (3)

Axonet vokser frem

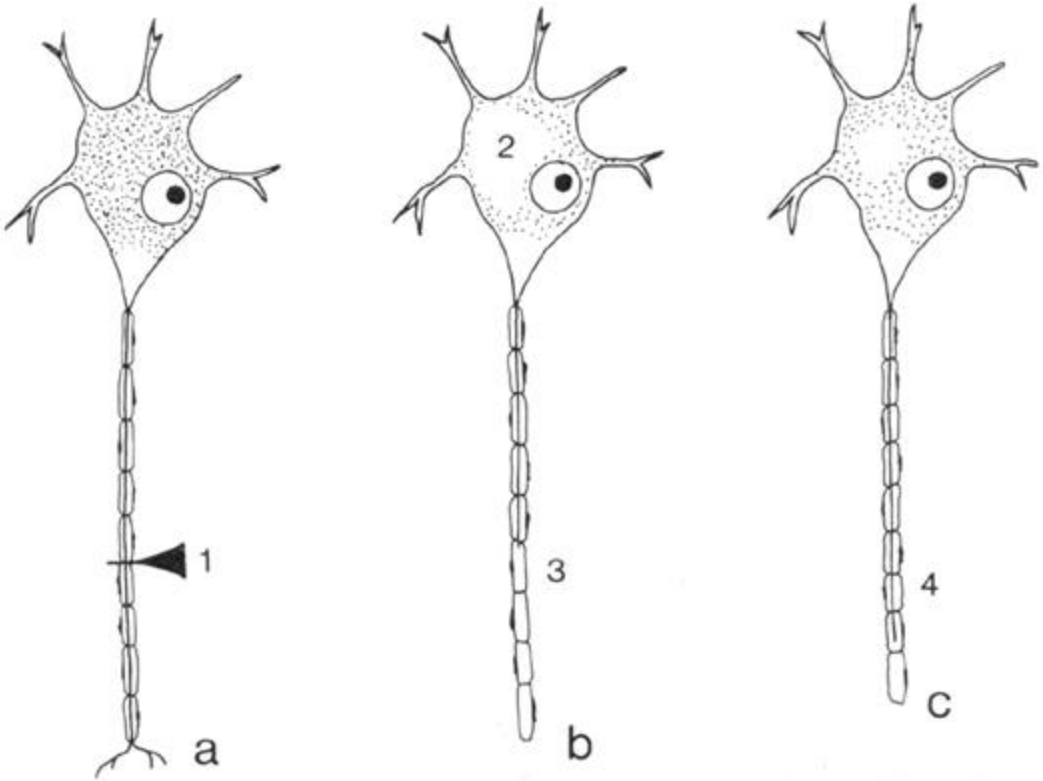

- axon-del med forbindelse til det trofiske centrum vokser frem (3)
- guidet af tilbageblivende Schwanns celler (4)
- som efterhånden danner myelin igen

Nerveregeneration mulig?

- Spontan nerveregeneration er kun mulig i PNS (ikke i CNS)
- Schwanns celler skal være tilstede
- nervetråde i rygmarv og hjerne kan ikke regenerere

Sammensyning af overskårne nerver

- der sys i omkringliggende bindevæv (perineurium)
- fremmer sammenvoksning
- axon kan lettere finde Schwanns skede
- axon vækst ca 2 mm/døgn

Nervevæv (1)

→ Mentimeter

Synapse

- kontaktområde mellem to neuroner

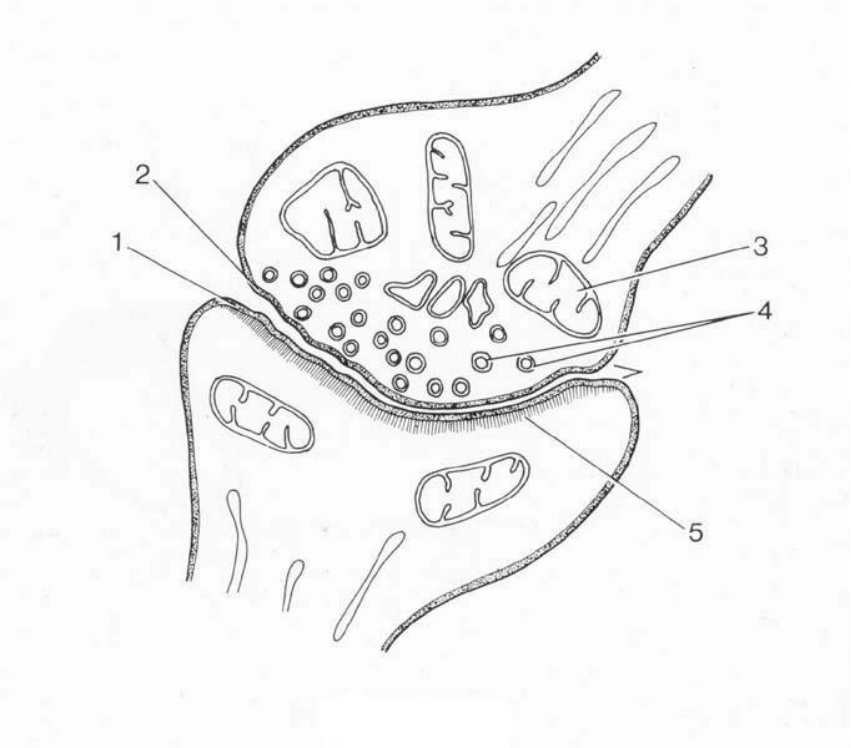

Synapse

- kontaktområde mellem to neuroner
- Axon danner synapse til:

  ↔ dendriter

  ↔ cellelegeme
- op til tusinder

  synapser pr neuron

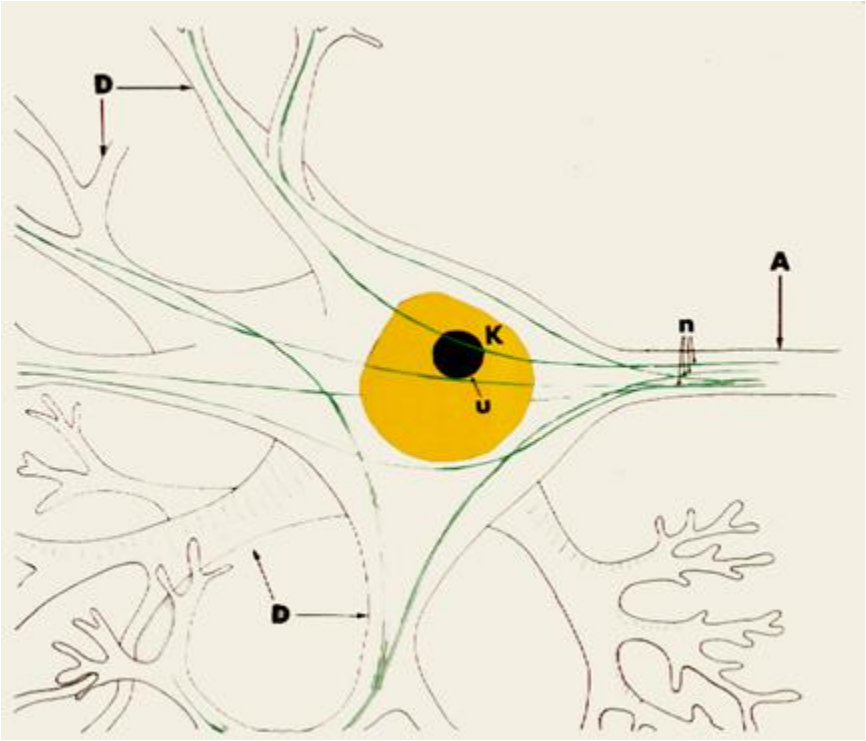

Den synaptiske kløft

- axonets endeknop indeholder talrige vesikler
- transmitterstof bliver overført til receptor-molekyler på den tilgrænsende celleoverflade

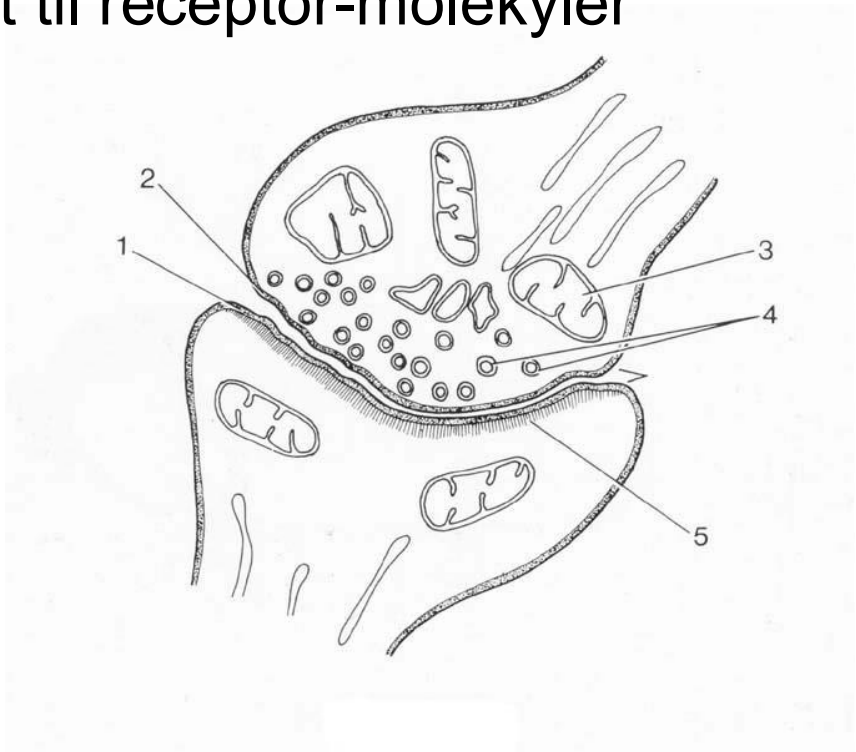

Neuroglia

- CNS's særlige støttevæv
- ofte stjerneformede celler
- flere typer..

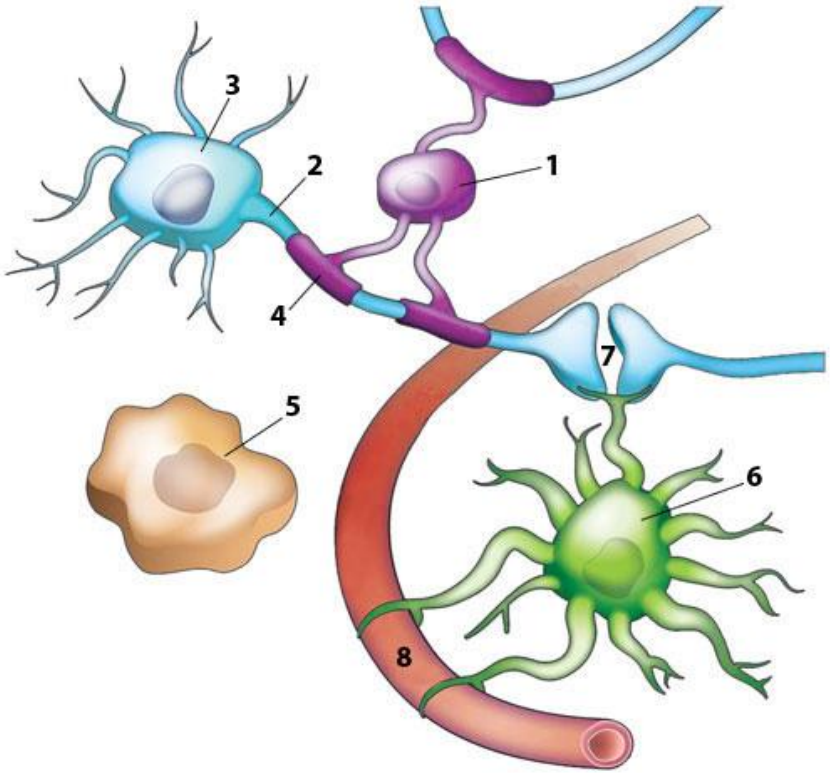

http://med.stanford.edu/ism/2009/september/glia-0921.html

Neuroglia

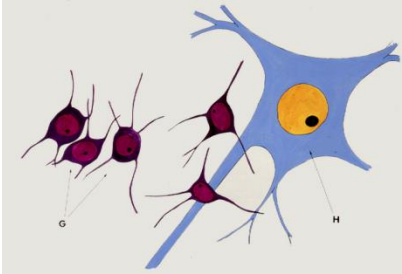

- astrocyter — danner net
- oligodendrocyt — danner myelinskeder
- mikroglia — makrofag
- ependymceller — kubiske/prismatiske i hulheder

Bindevæv

Omkring:

- hele nerven — epineurium (a)
- nervetrådsbundter — perineurium (b)
- enkelte nervetråde — endoneurium (c)



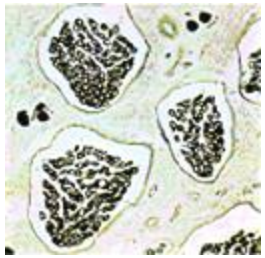

Ganglier

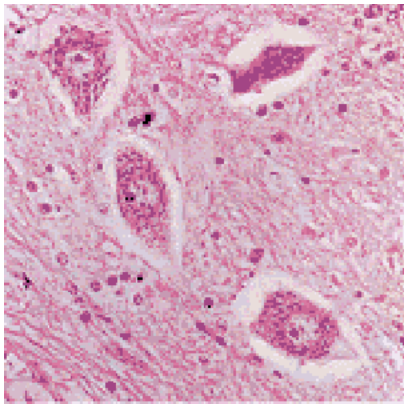

ansamling af cellelegemer:

- sensitive ganglier
- hjernenerveganglier
- spinalganglier
- autonome ganglier

..beskrevet i CNS kapitlet

Perifere nerveender

- Afferente impulser (tilførende): sensitive indtryk fra omgivelser og organismen selv
- Efferente impulser (fraførende): motoriske og sekretoriske signaler til muskler og kirtler

Afferente nerveender

Forekomst:

- frit
- indkapslede

Nerveender i dækepitel

- frie forgreninger uden myelinskede responderer på *smerte* og *temperaturændringer*

- Merkel-celle fungerer som følelegemer, der reagerer på *tryk og berøring*

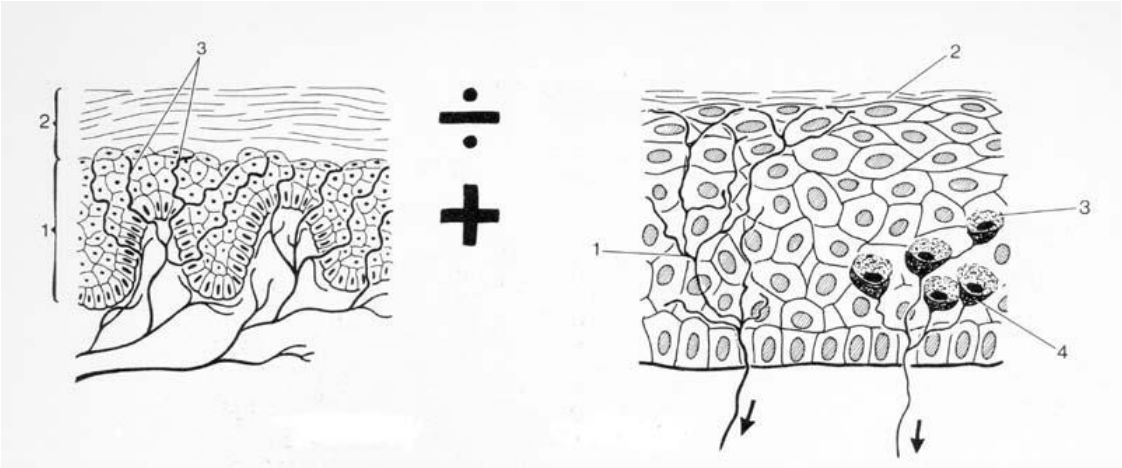

Frie nerveender i bindevæv

- i læderhud: *smerte* og *temperaturændringer*
- omkring hår: *tryk* og *berøring*

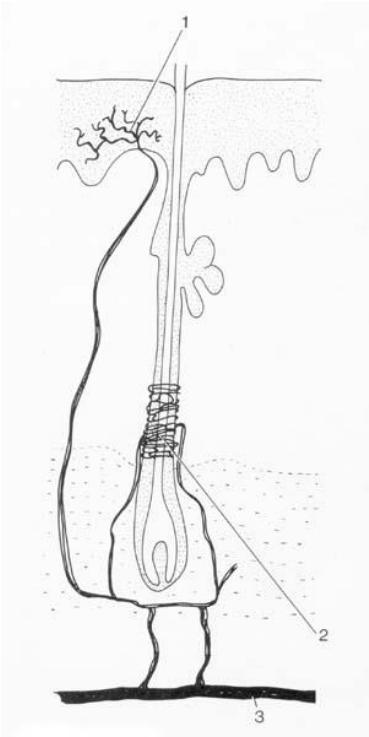

Indkapslede nerveender i bindevæv

- mekanoreceptorer

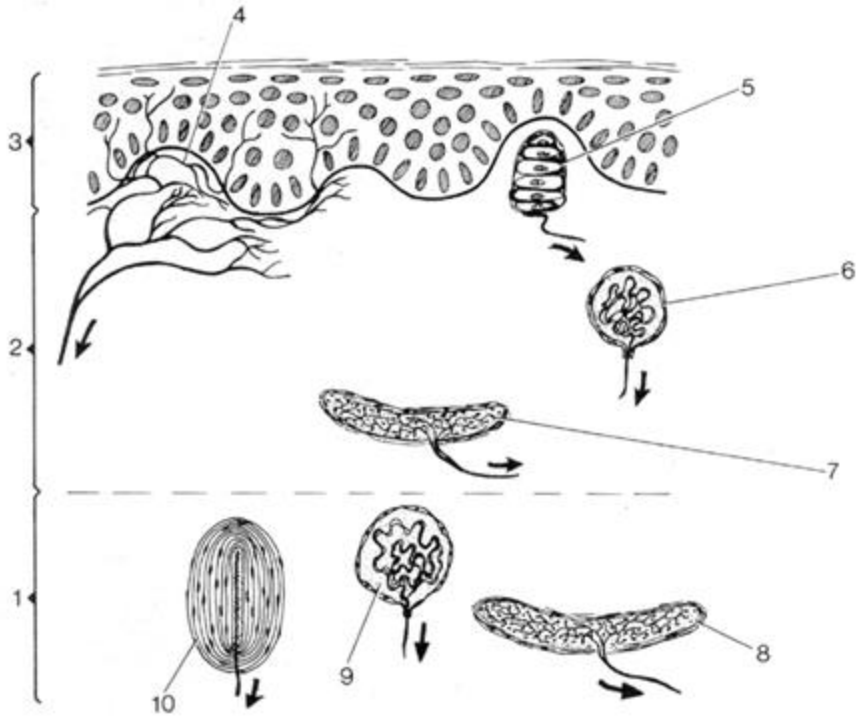

Endekolber

- Endekolber
- Meissner legemer
- Vater-Pacini

- mekanoreceptor
- i læderhud eller i underhud
- kapsel omkring granuleret substans hvor nervetråde forgrener sig
- (6-9)

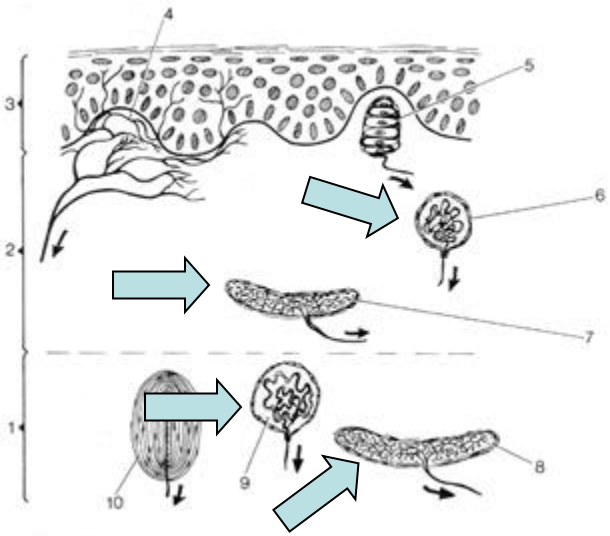

Meissner legemer

- Endekolber
- Meissner legemer
- Vater-Pacini

- mekanoreceptor
- i læderhudspapiller i fodsåler og håndflader
- kapsel omkring kileformede celler, som nervetråde løber igennem (5)

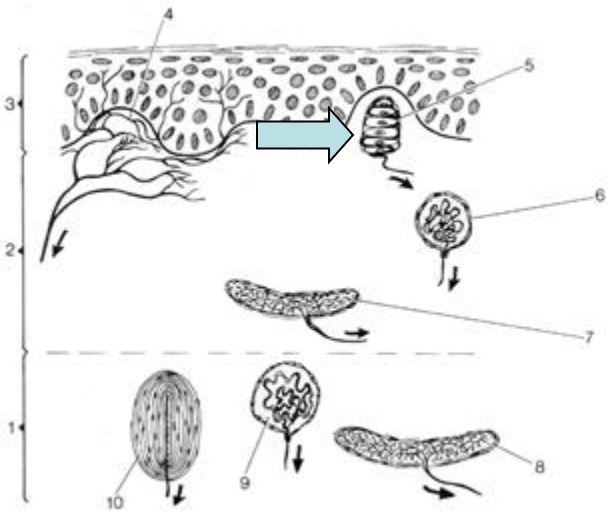

Vater-Pacini

- stor mekanoreceptor
- i underhud og omkring led
- koncentriske lameller omkring en central masse med en nøgen aksecylinder (10)

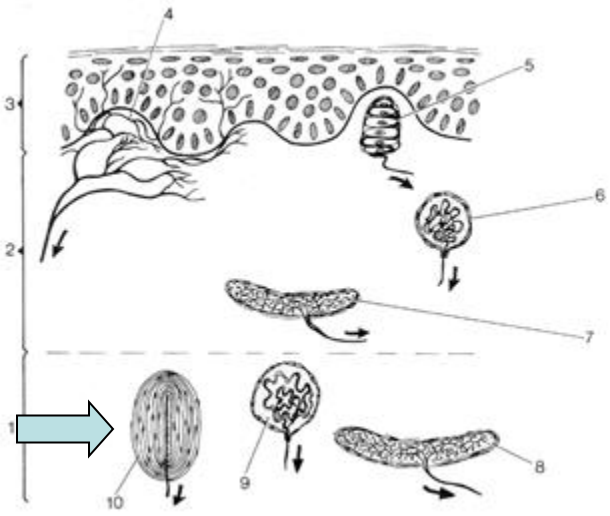

Muskelten

- 3-8 tynde muskeltråde (1-7 mm)
- med spiralsnoet sensitiv nervetråd
- i bindevævskapsel
- giver impuls ved strækning

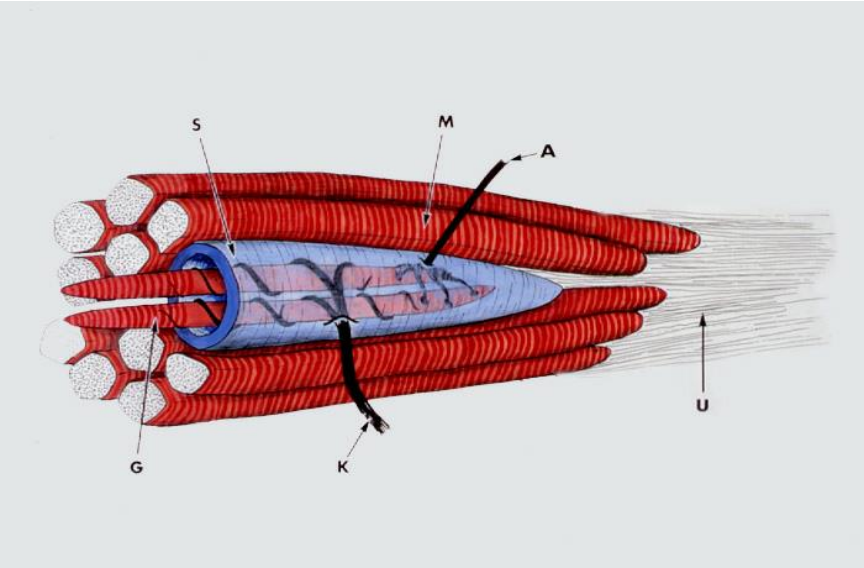

Seneten

- kollagene fibrilbundter med indlejrede nervetråde
- omgivet af bindevævskapsel
- giver impuls ved strækning
- impuls dæmper muskelkontraktion

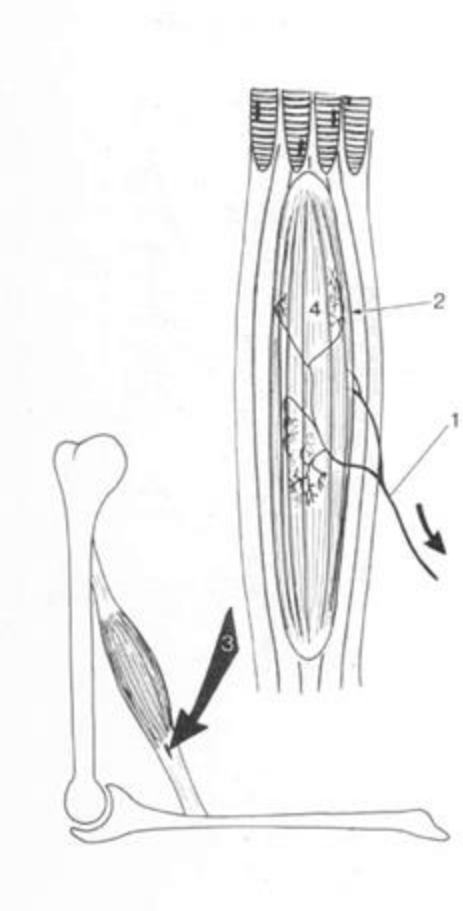

Efferente nervetråde

- uden på glatte muskelceller
- imellem hjertemuskelceller
- `ind i` tværstribede muskelcelle

(næste billede)

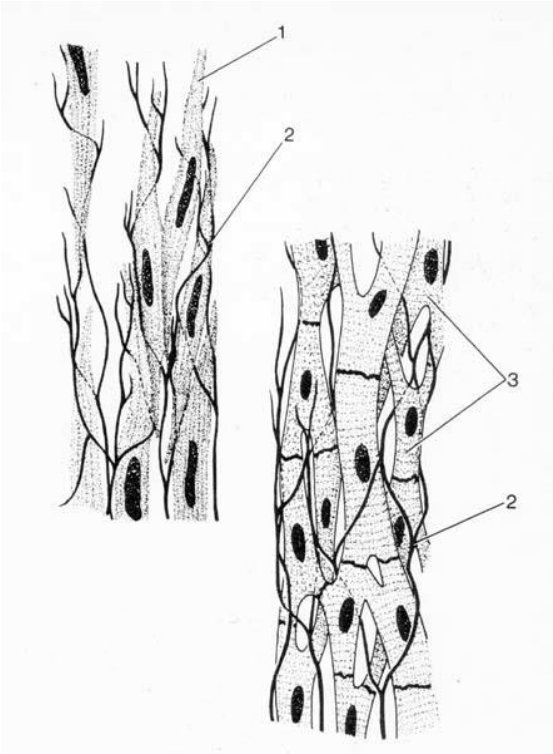

Motorisk endeplade

- fungerer som en synapse
- tværstriberne er forsvundet lokalt
- er et kernerigt område

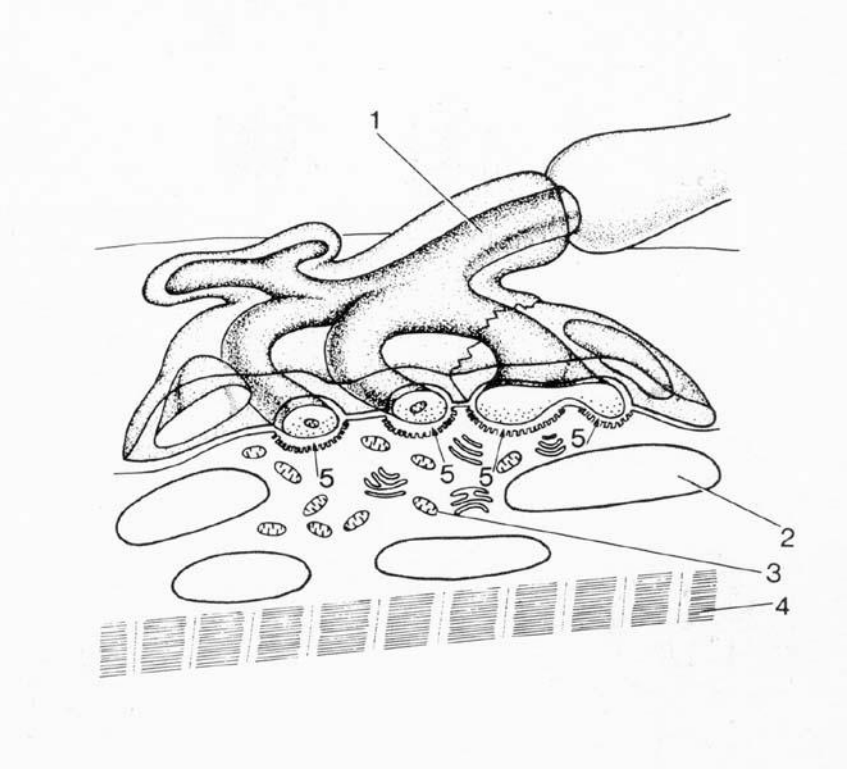

“Motor unit”

- et neuron
- innerverer mange muskelceller (tråde)
- 5-2000 muskeltråde

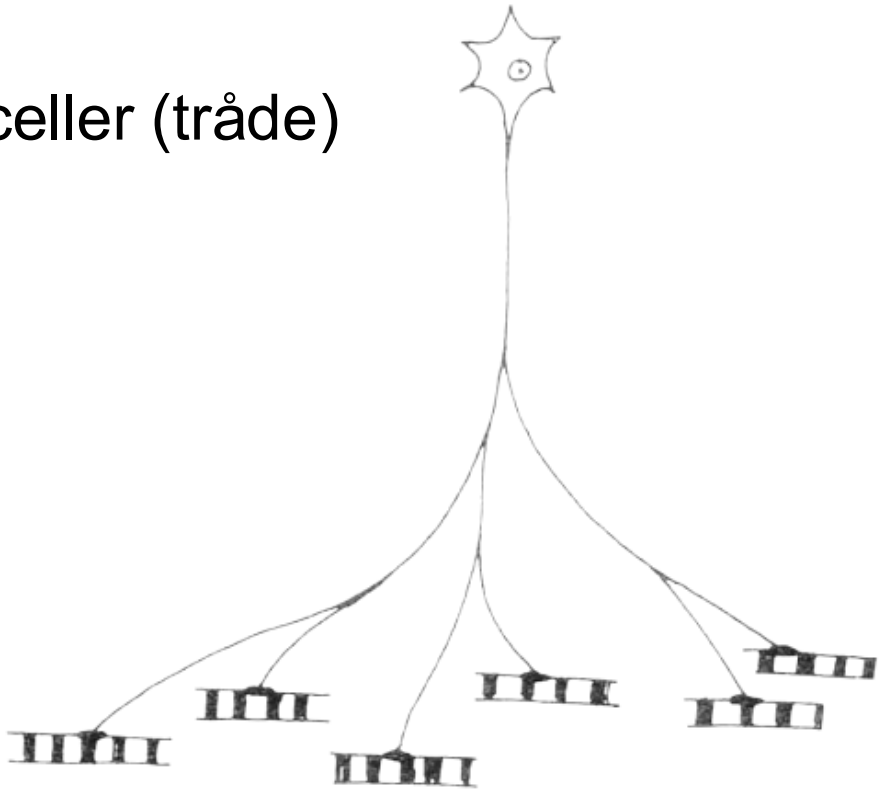

- 1-4

1-4’ motor unit
5-9’ synapse

Peerfeedback 2 og 2 - evt 3

Nervevæv (2)		
Nervetråde (3 typer / ledningshastigheder)		
Ved overskæring af perifer nerve - hvad forsvinder (1)		
- hvad guider axon udvækst (1)		
Nerveender (5 typer)		
Tene (2)		
En motorisk neuron innerverer antal muskelceller (tråde)		

Animations

Synapser er vigtige for muskler, nerver og hjernen.

Link: Motor unit (sek 0:20-2:48)

MUSKELVÆV
- vævslære

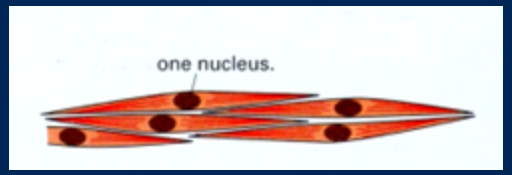

AARHUS
UNIVERSITET
INSTITUT FOR ODONTOLOGI OG ORAL SUNDHED

MUSKELVÆV

En muskel består af:

- bundter af muskelceller også kaldet muskeltråde
- sammenholdt af bindevæv

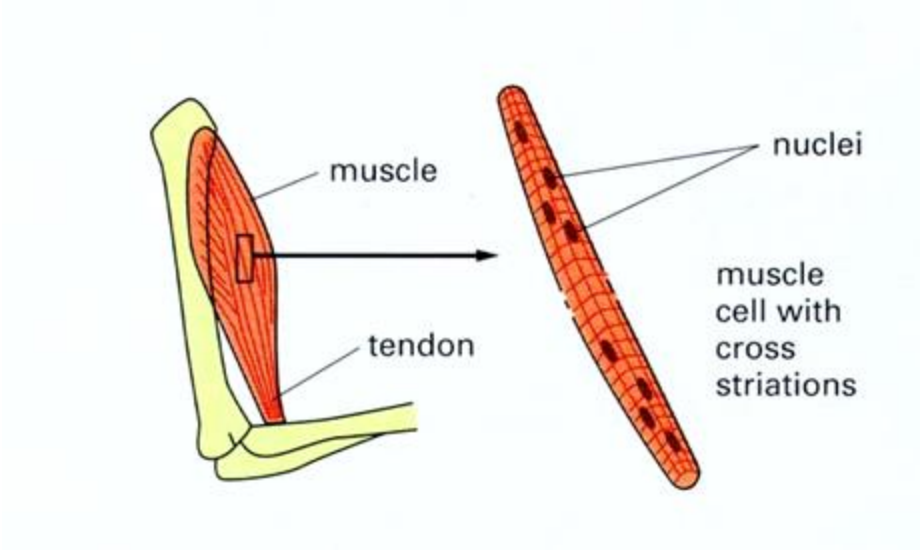

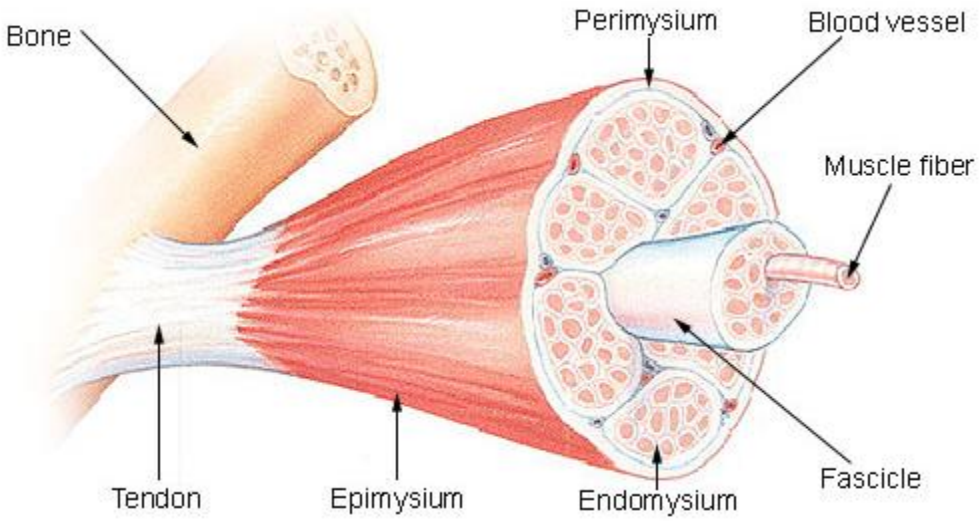

MUSKELVÆV

- indeholder fibriller
- evne til kontraktion
- aktinfilamenter glider henad myosinfilamenter

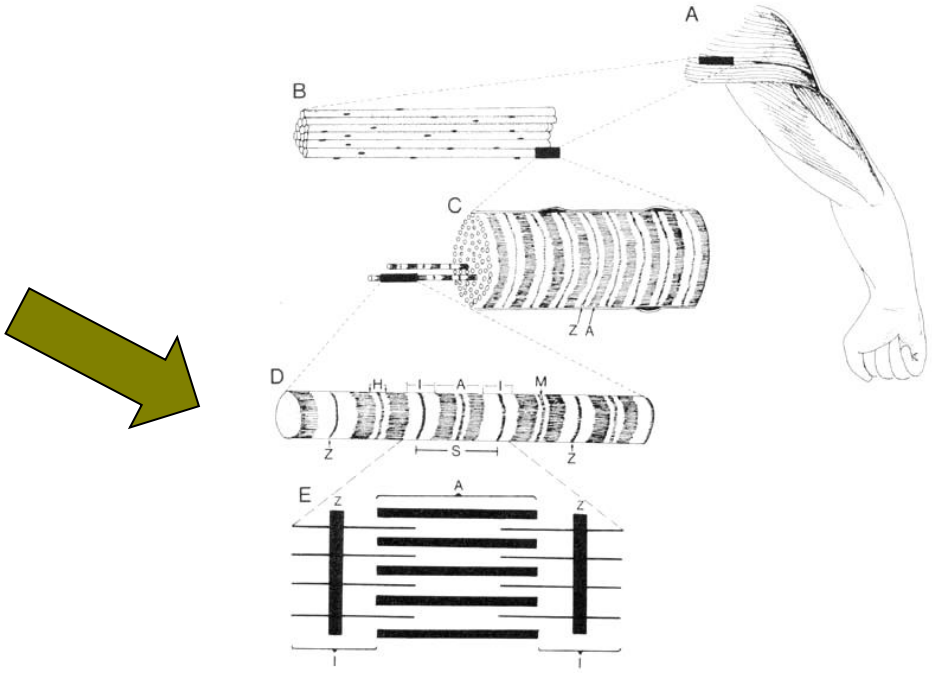

MUSKELVÆV

- glat
- tværstribet
- hjerte

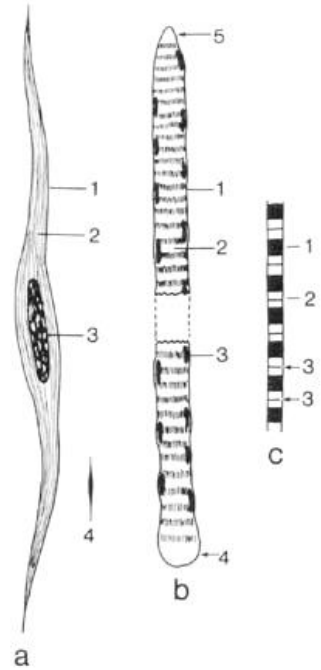

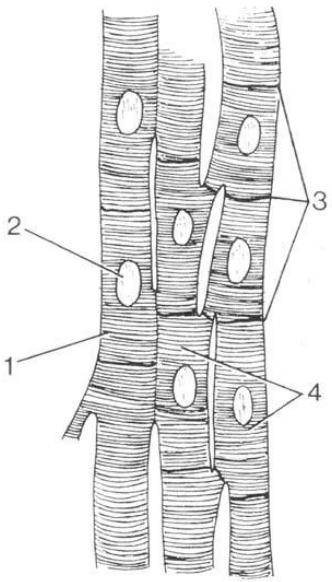

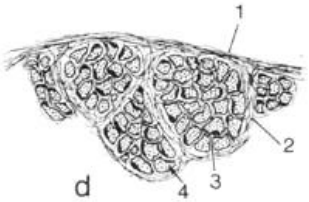

MUSKELVÆV

	kontraherer:
• glat..	langsomt og uvilkårligt
• tværstribet..	hurtigt og vilkårligt
• hjerte..	variabelt og uvilkårligt

- myoepithelial glat muskelcelle

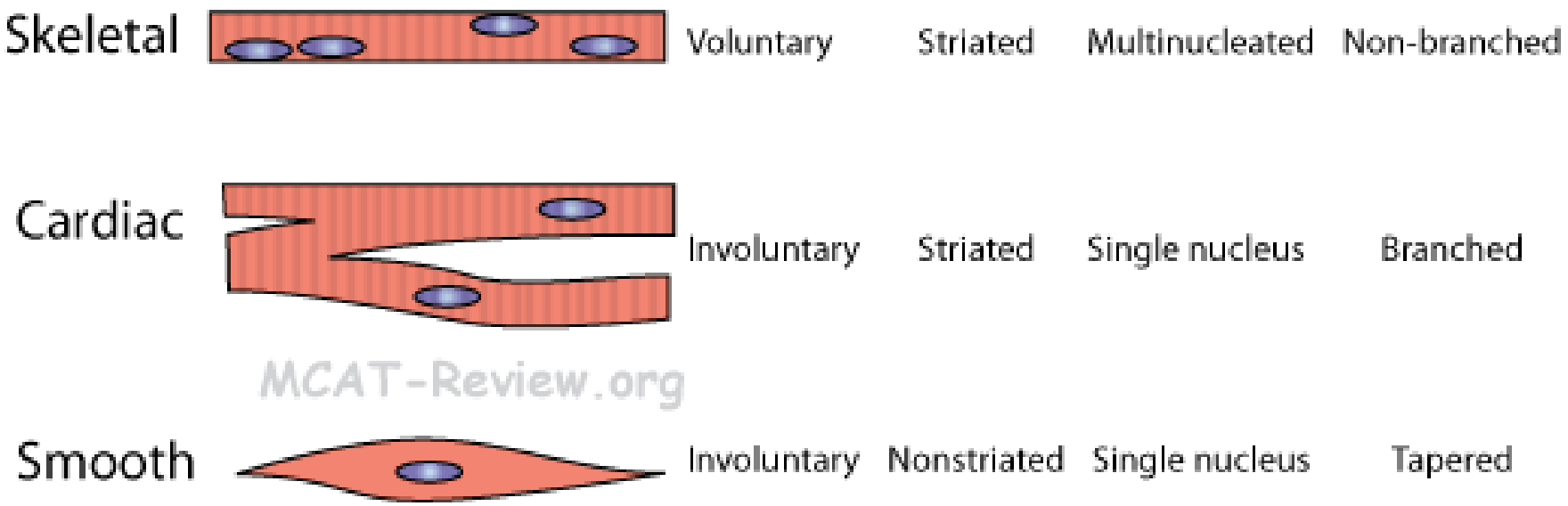

http://mcat-review.org/muscle-skeletal-systems.php

GLAT MUSKELCELLE

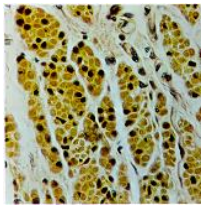

- tenformet
- kun én central kerne
- myofibriller mangler tværstribning

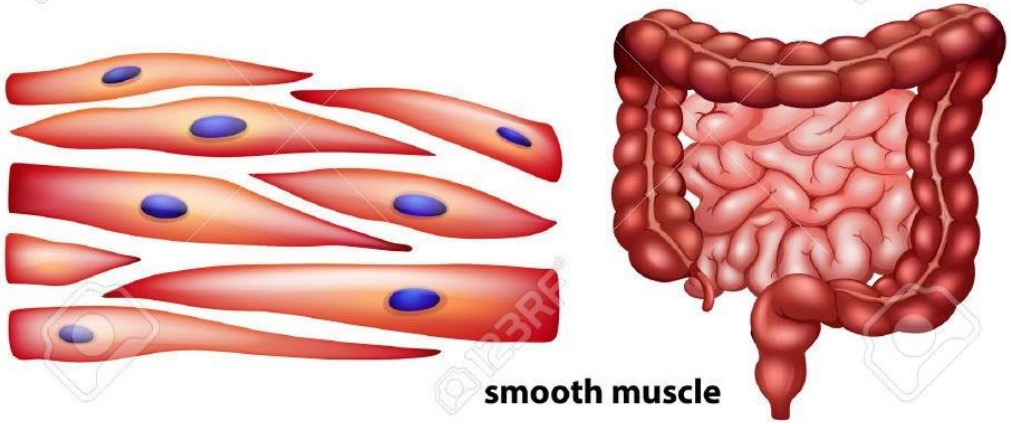



GLAT MUSKELCELLE

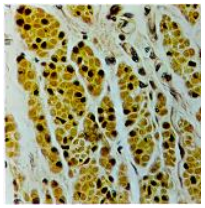

- længde og bredde

  i gennemsnit ca 100 µm x 10 µm
- længdevariation: 15-500 µm

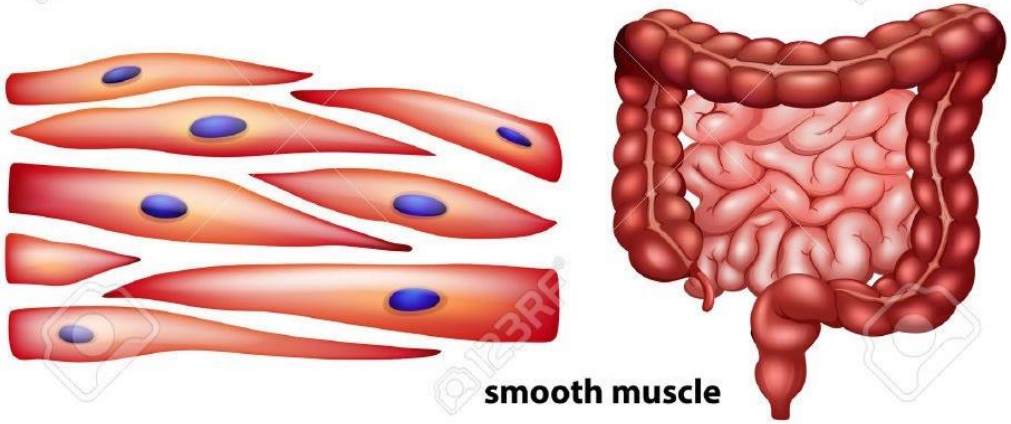

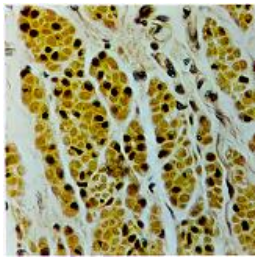

GLATTE MUSKELCELLER

Forekomst:

- fra midten af spiserør og ned i fordøjelseskanalen
- fra luftrøret og ned i alveolesække
- omkring hår
- i pupiller
- arterier

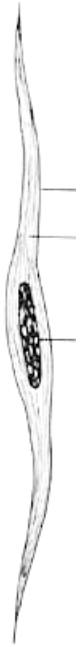

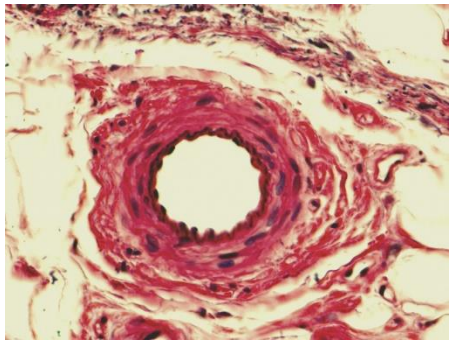

GLATTE MUSKELCELLER

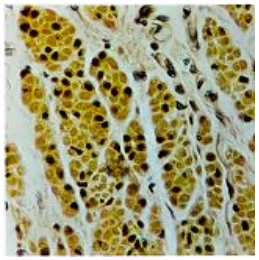

To typer:

- adskilte muskelceller (multienhedstypen)
- tætte bundter (viscerale type,

  med gap junctions)

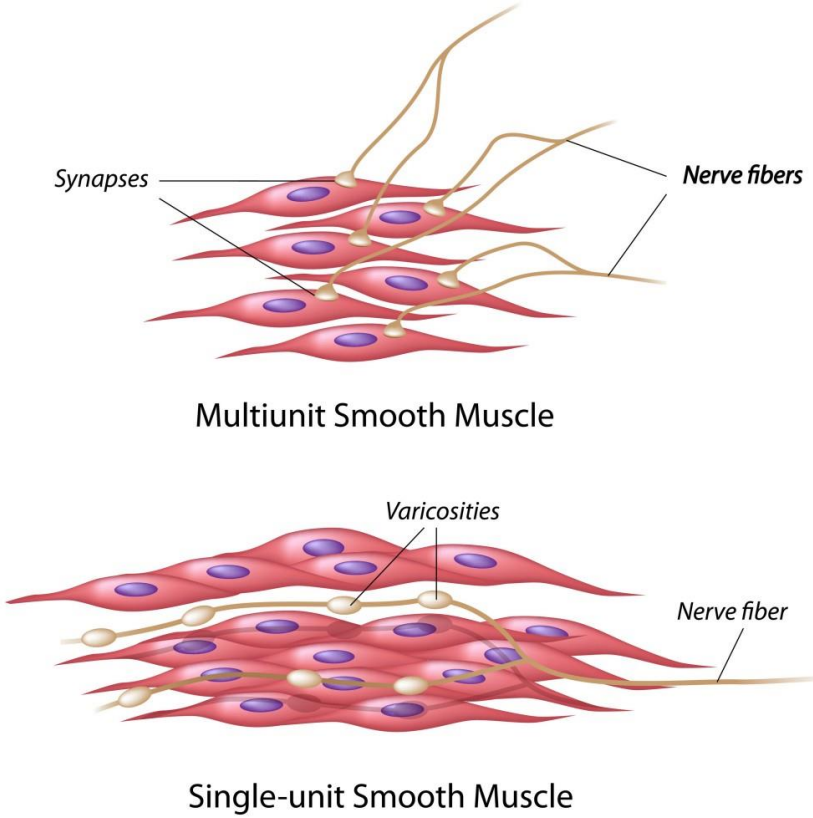

http://www.interactive-biology.com/3373/the-muscular-system-how-we-move-

TVÆRSTRIBET MUSKELCELLE

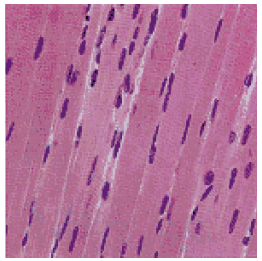

- stor og cylindrisk
- mange kerner op til flere hundrede
- kerner perifert

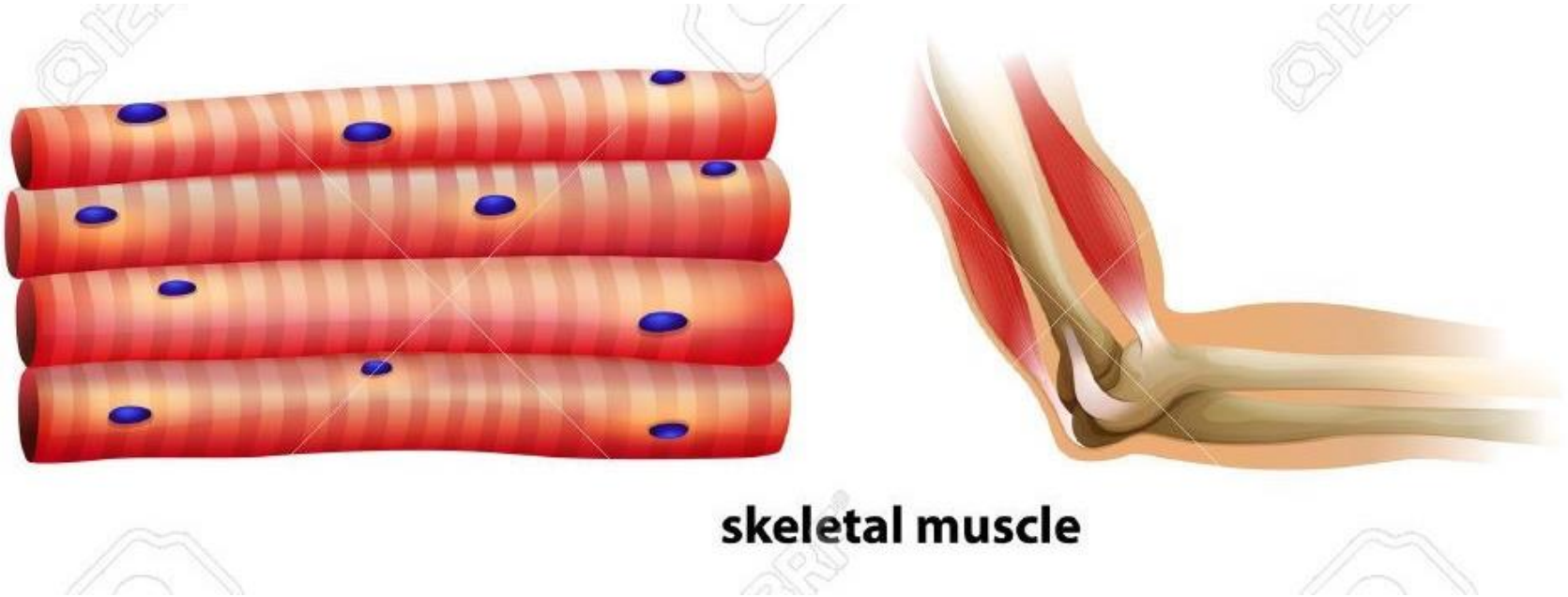

TVÆRSTRIBET MUSKELCELLE

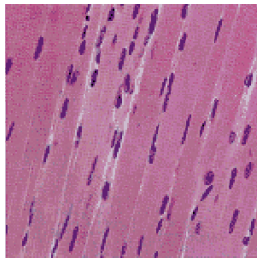

- bredde 10-100 µm
- længde: ofte flere cm

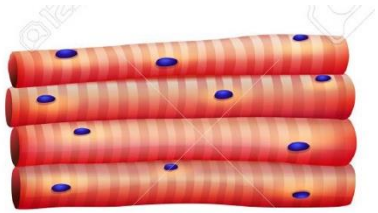

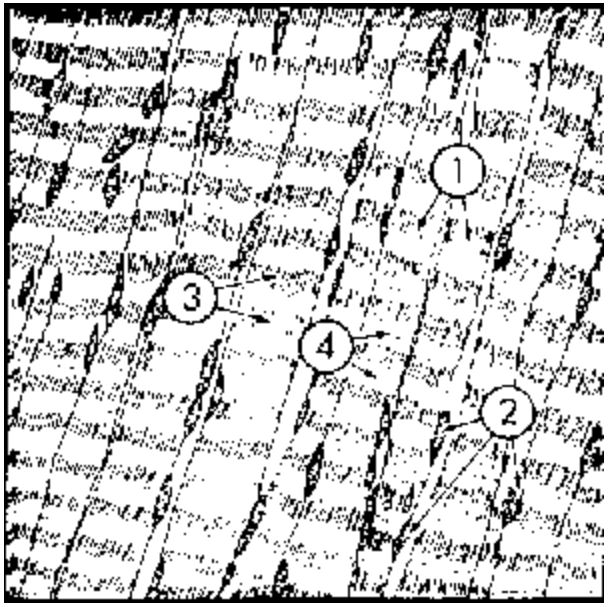

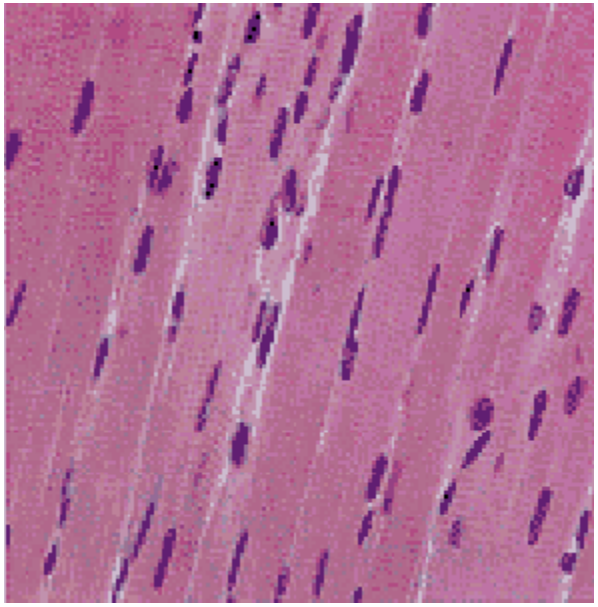

HJERTEMUSKELCELLE

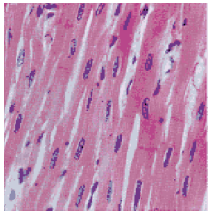

- er tværstribet
- kerner ligger centralt

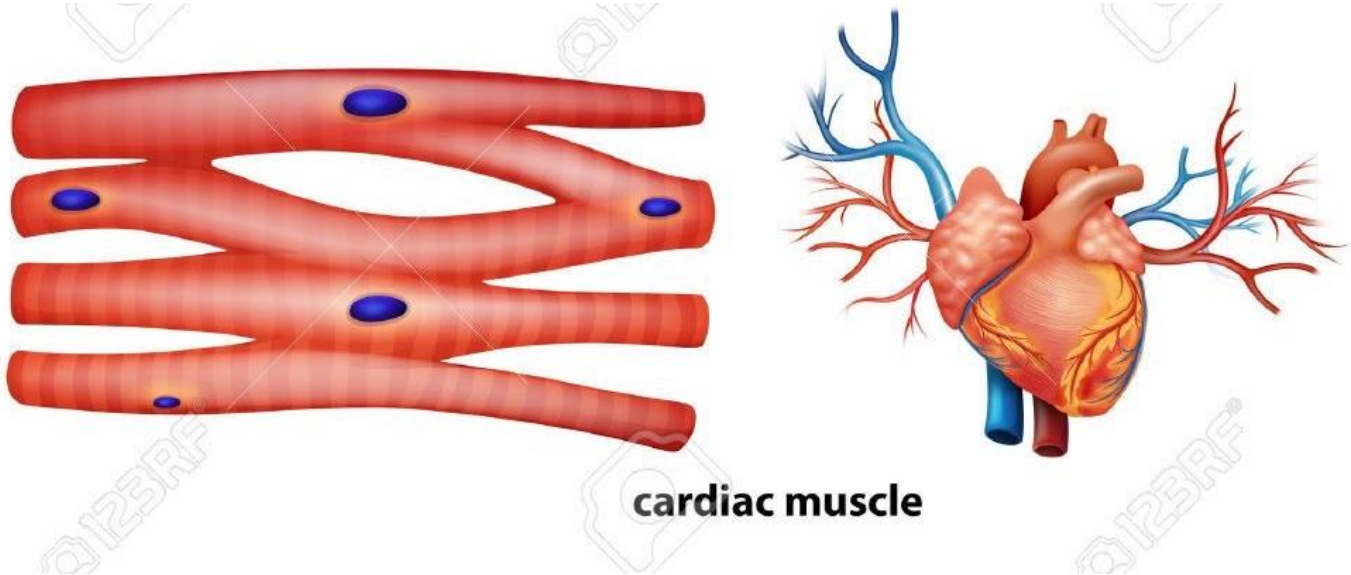

HJERTEMUSKELCELLE

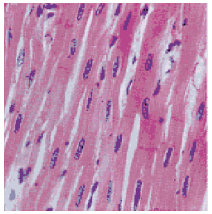

- "kitlinjer" optræder på tværs af cellerne

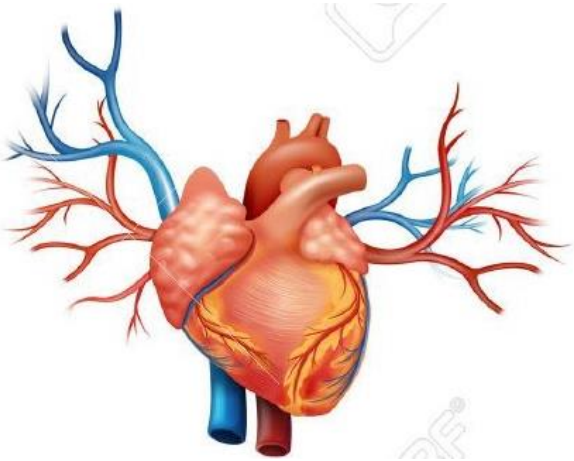

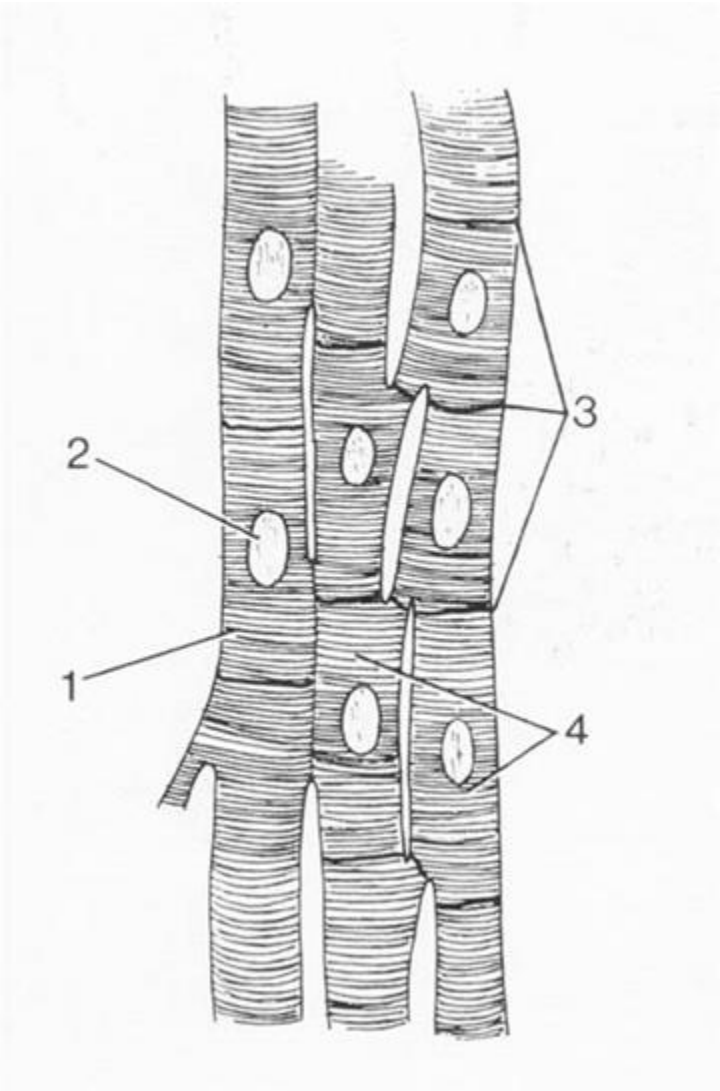

Muskelvæv

→ Mentimeter

HJERTEMUSKELCELLE

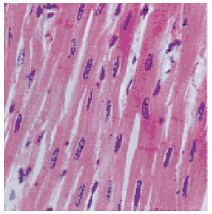

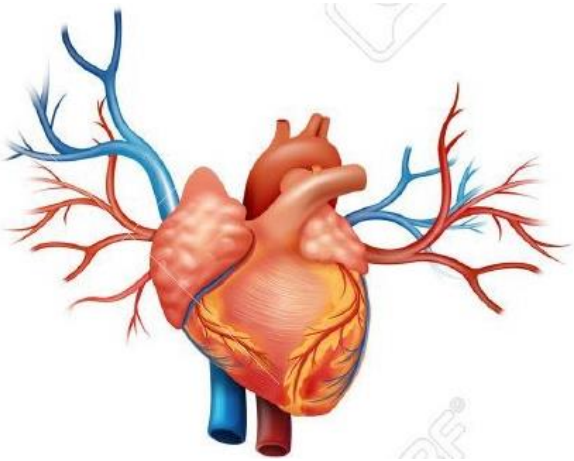

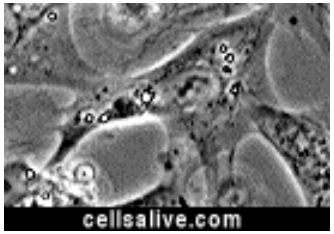

Peerfeedback 2 og 2 - evt 3

Muskelvæv		
Muskelvæv inddeles i (3)		
Hvordan kontrahere de (3)		
Hvordan ser de ud (3)		

IOOS, AU