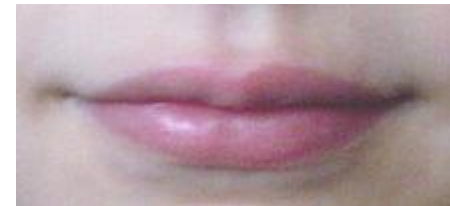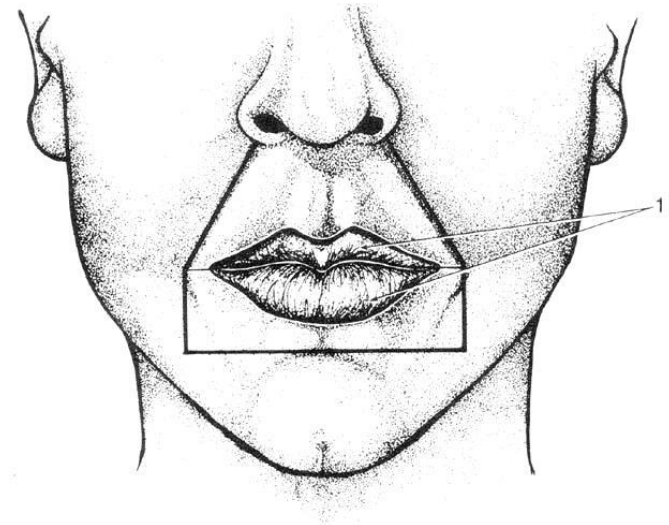


# FORDØJESSESYSTEMET

- HOVEDETS MUSKLER
  - ANSIGTSMUSKLER
    - MUNDENS MUSKLER
      - LÆBERNE
      - KINDEN
      - HAGEN



NB læbernes region = regio oralis

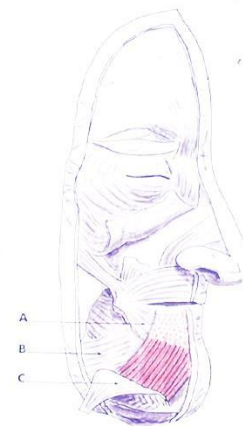


# ansigtsmuskler

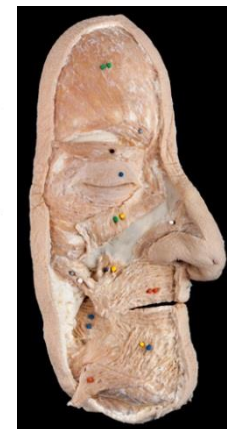## Inddeling:

- overlæbens muskler
- underlæbens muskler
- kindens muskler
- hagens muskler
- næsens muskler
- øjeåbningens muskler
- øreåbningens muskler

## MUNDENS MUSKLER



A02-129 16-16



# mundhulens muskler



## Inddeling:

- overlæbens muskler
- underlæbens muskler
- kindens muskler
- hagens muskler

DYBE &  
OVERFLADISKE

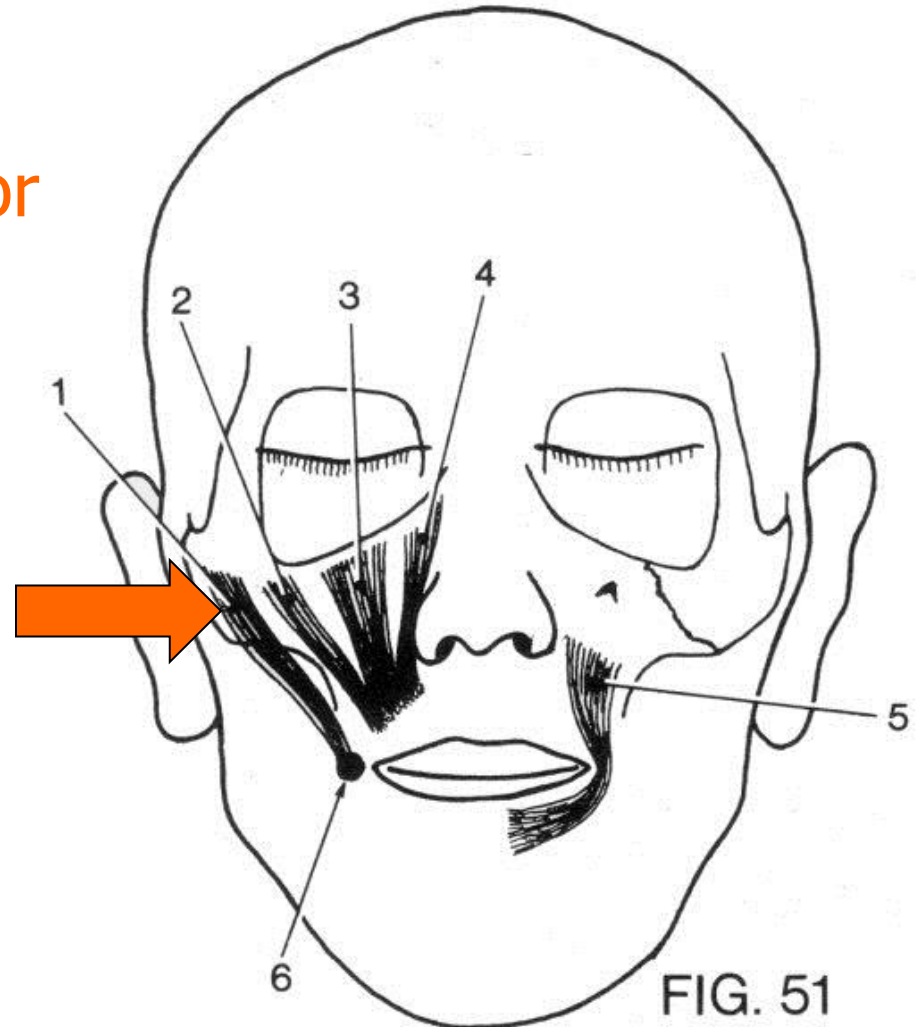
# overlæbens muskler





# overlæbens muskler

- **superficielle lag**
  - **m. zygomaticus major**

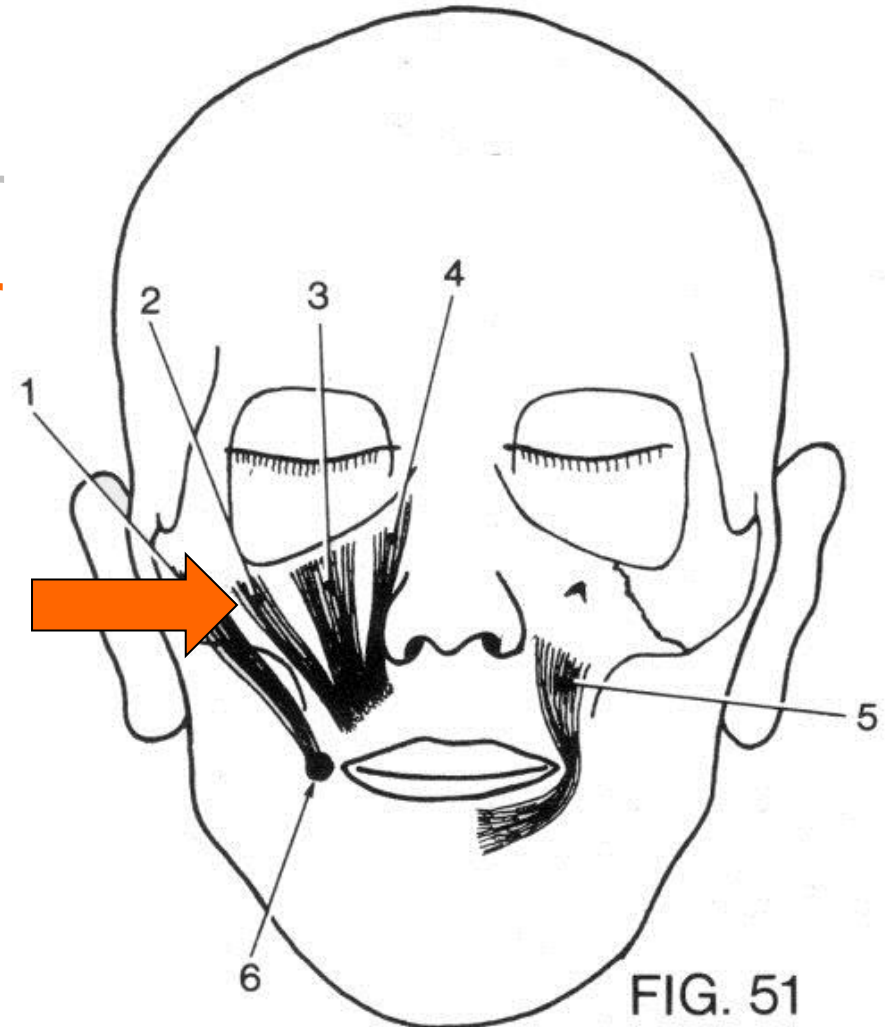


- (Se fx sp19/1) Skab 39/11

# overlæbens muskler

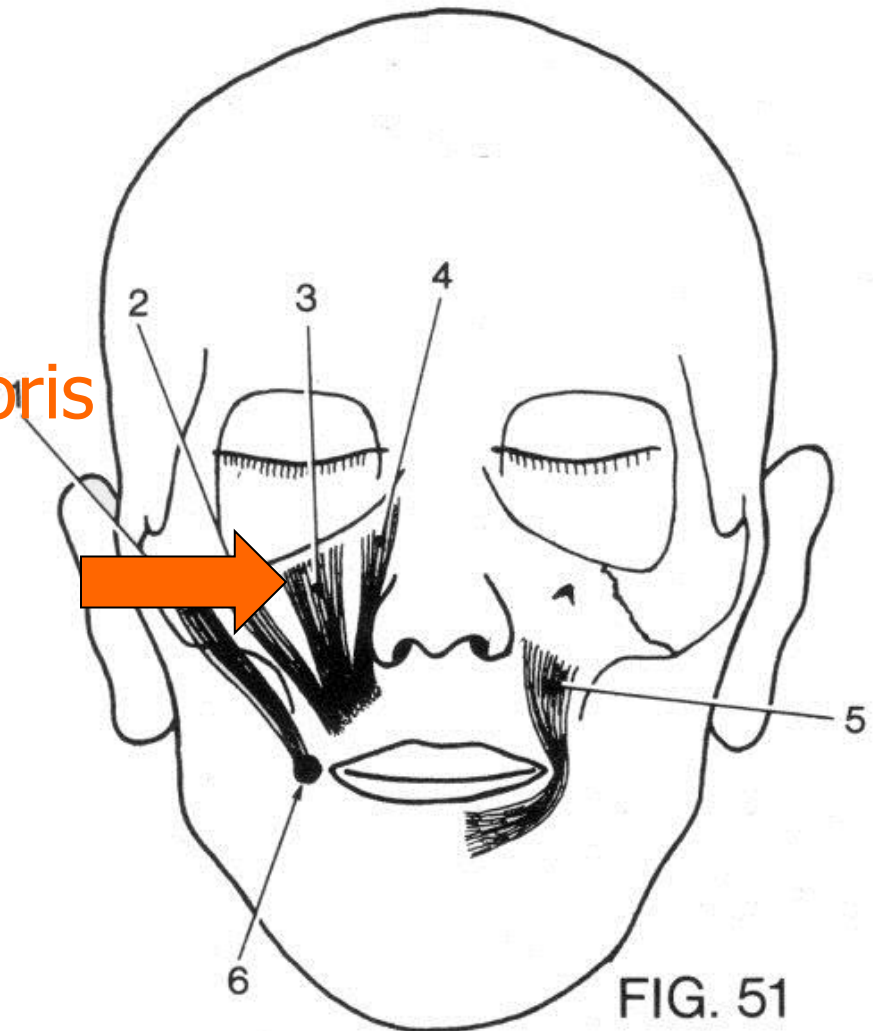
- **superficielle lag**
  - m. zygomaticus major
  - m. zygomaticus minor

- Skab 49/4



# overlæbens muskler

- **superficielle lag**
  - m. zygomaticus major
  - m. zygomaticus minor
  - **m. levator labii superioris**

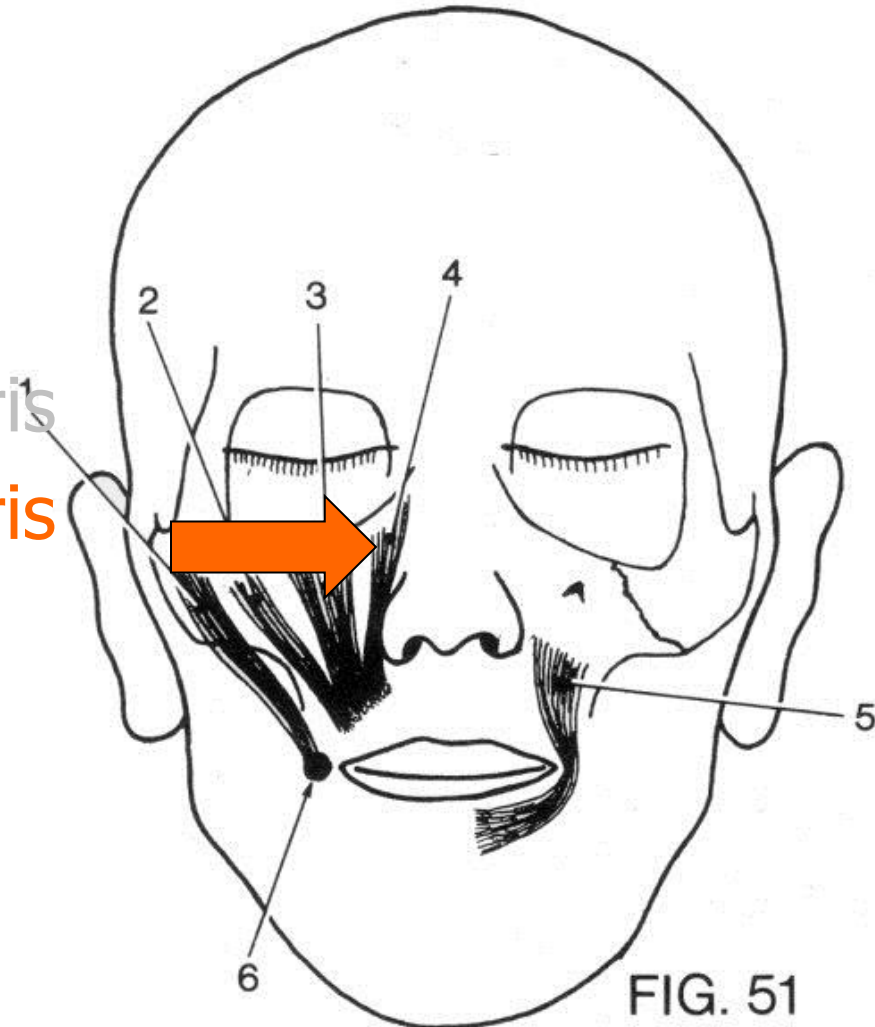


- (Se fx sp37/2) Skab 49/3



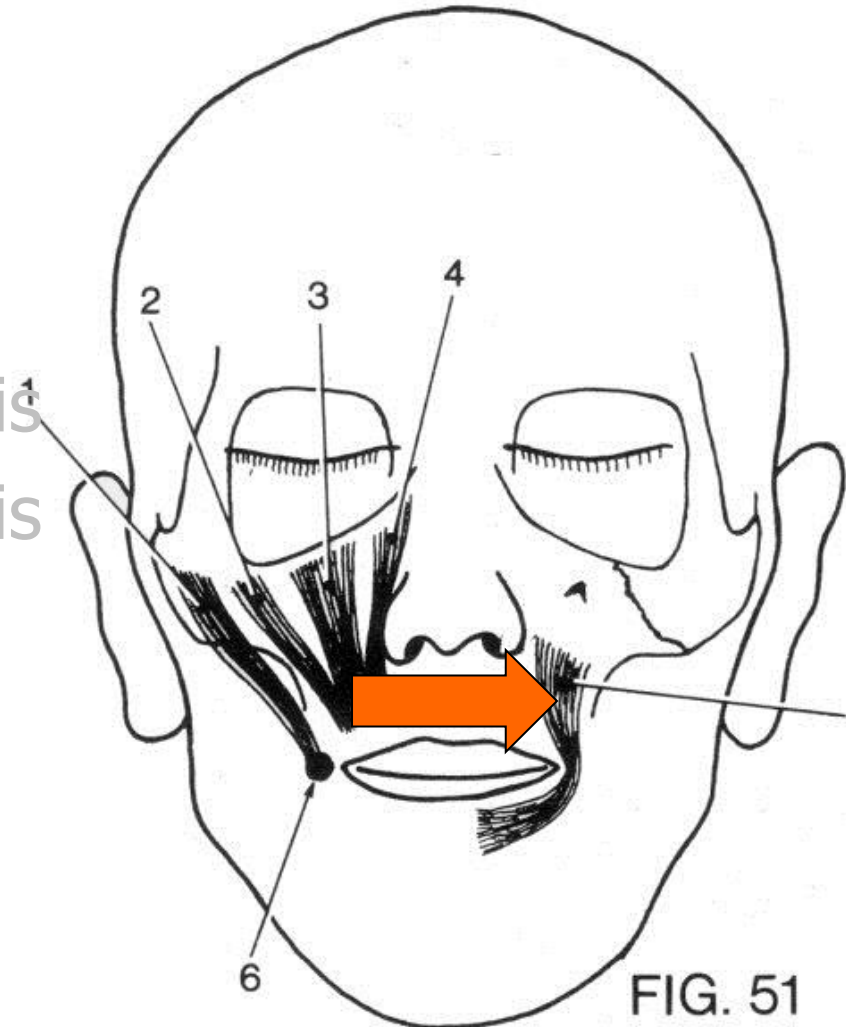
# overlæbens muskler

- **superficielle lag**
  - m. zygomaticus major
  - m. zygomaticus minor
  - m. levator labii superioris
  - **m. levator labii superioris alaeque nasi**
  
- (Se fx sp37/2) Skab 49/3



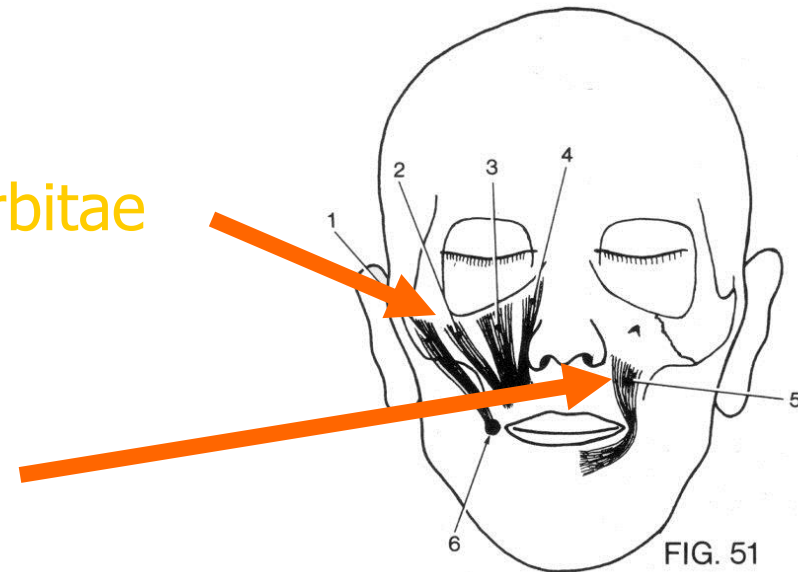
# overlæbens muskler

- superficielle lag
  - m. zygomaticus major
  - m. zygomaticus minor
  - m. levator labii superioris
  - m. levator labii superioris alaeque nasi
- **profunde lag**
  - m. levator anguli oris
- (se fx sp38/2 ) Skab 49/4



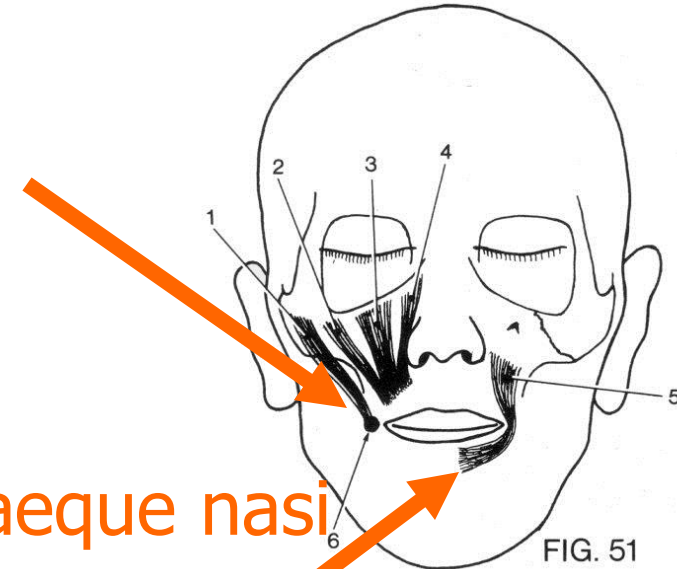
# udspring

- **superficielle lag**
  - udspringer langs aditus orbitae
- **profunde lag**
  - udspringer i fossa canina



# tilhæftning

- m. zygomaticus major
  - tilhæfter modiolus
- m. zygomaticus minor
- m. levator labii superioris
- m. levator labii superioris alaeque nasi
  - tilhæfter huden
- m. levator anguli oris
  - fortsætter i m. orbicularis oris



# underlæbens muskler



- Superficielle lag
- Profunde lag

# underlæbens muskler

- Superficielle lag
  - m. depressor anguli oris

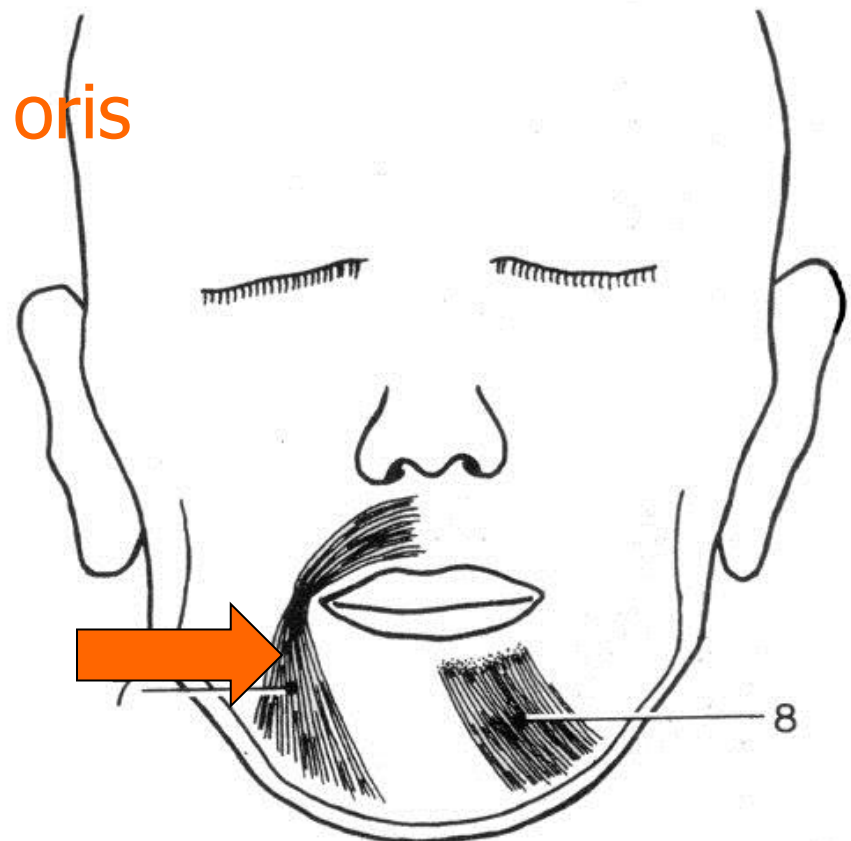


FIG. 52

# underlæbens muskler

- Superficielle lag
  - *m. depressor anguli oris*
- Profunde lag
  - *m. depressor labii inferioris*

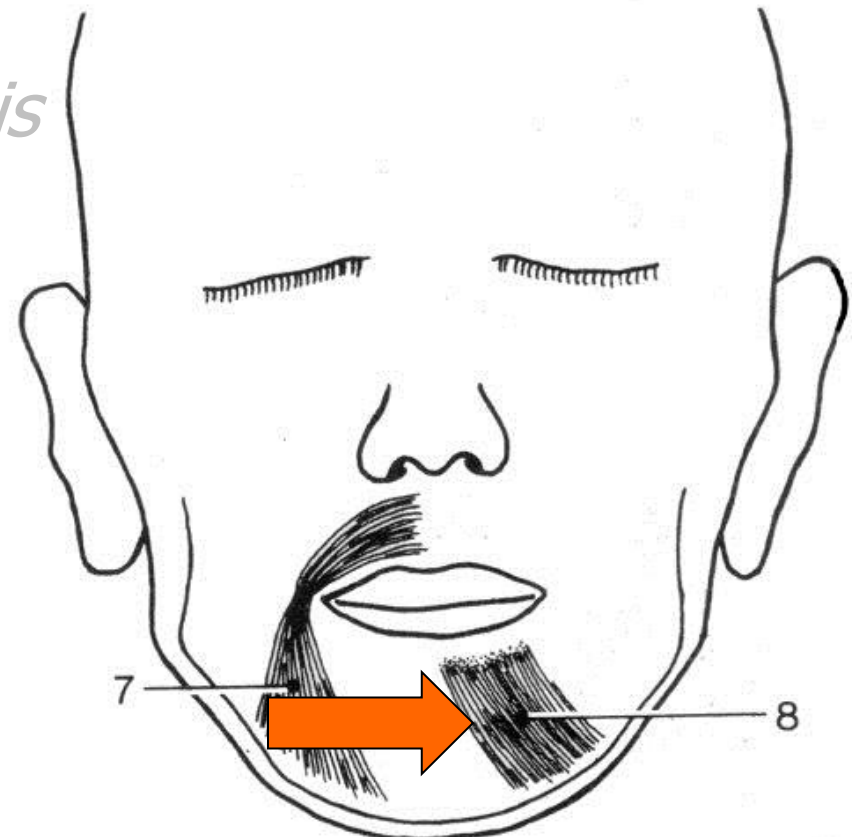


FIG. 52

# underlæbens muskler..

- **Superficielle lag**
  - m. depressor anguli oris
    - udspring på mandibula
    - fortsætter i m. orbicularis oris
- **Profunde lag**
  - m. depressor labii inferioris
    - udspring på mandibula
    - tilhæfter i underlæbens hud

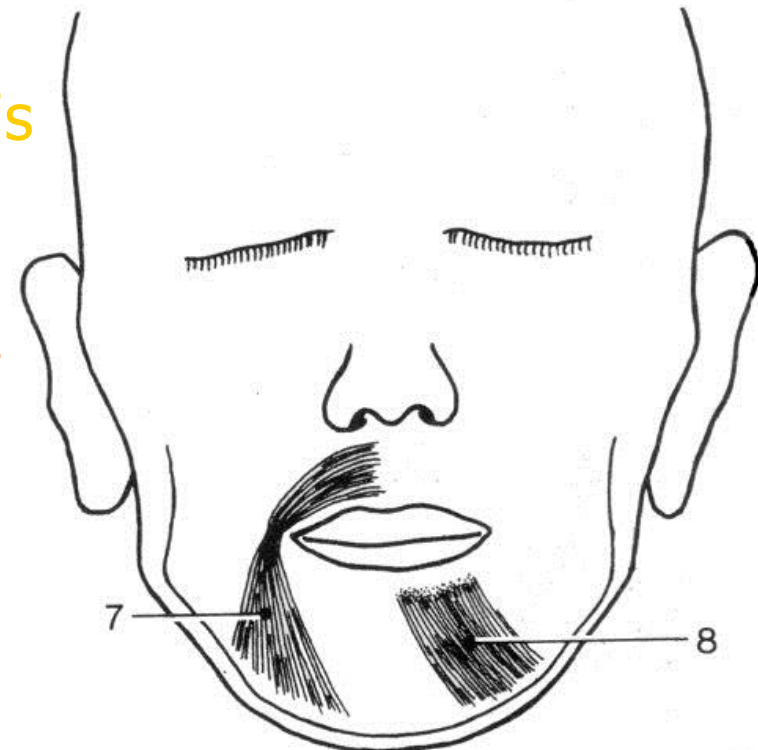


FIG 52



# læbernes muskler..

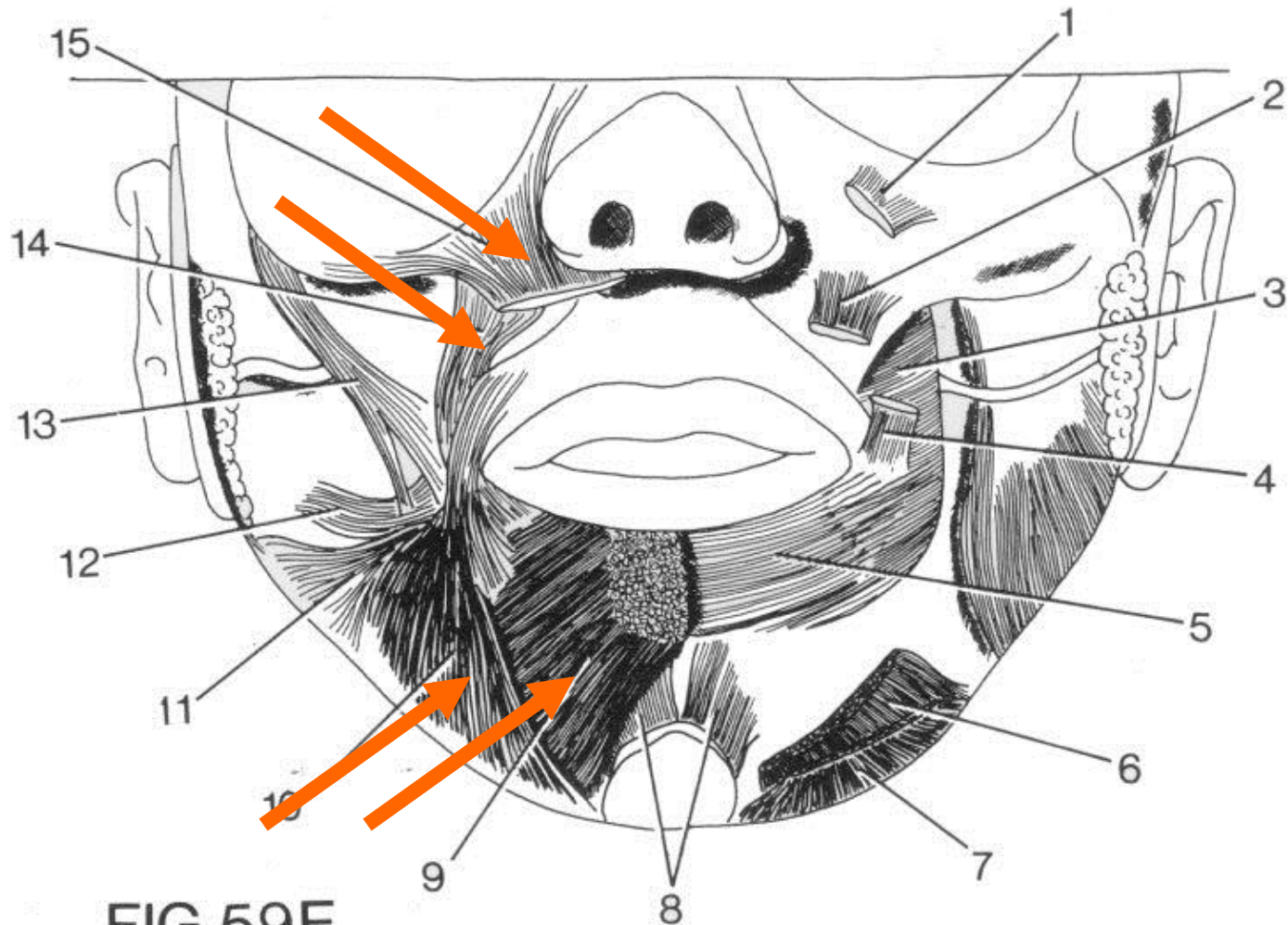


FIG.59E

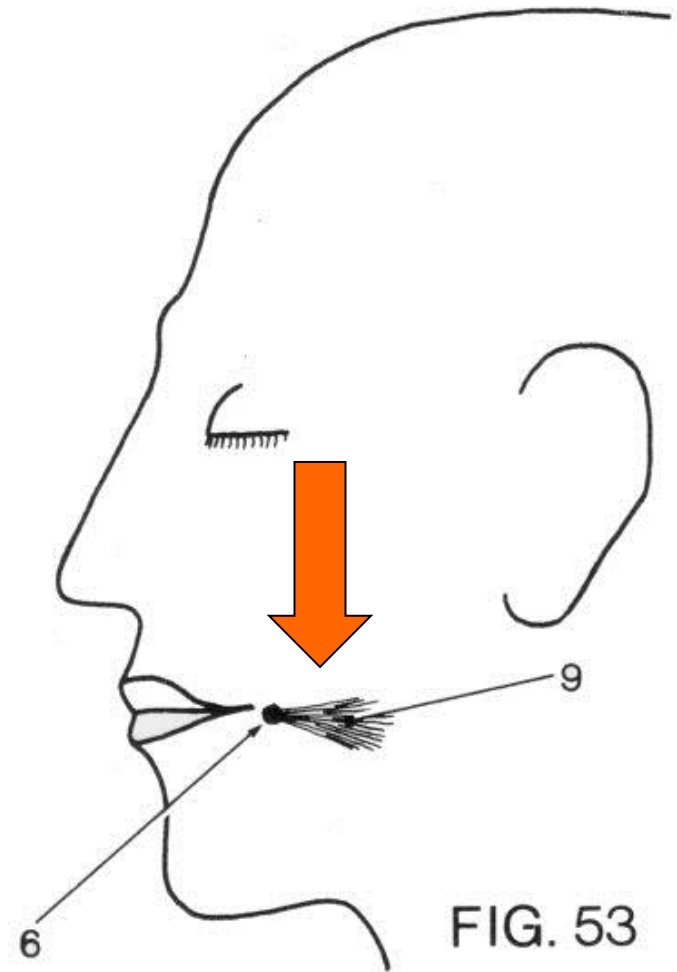
# kindens muskler



- superficielle lag
- profunde lag

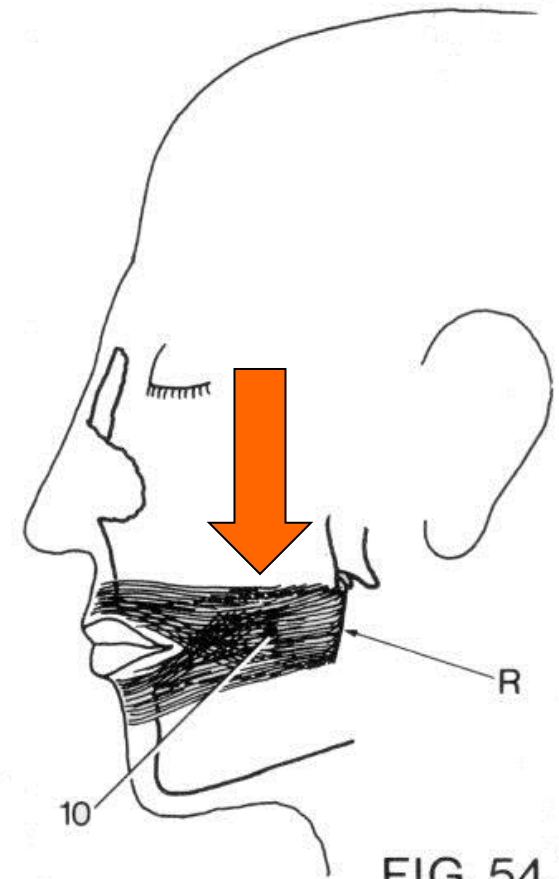
# kindens muskler

- **superficielle lag**
  - m. risorius (lattermusklen)



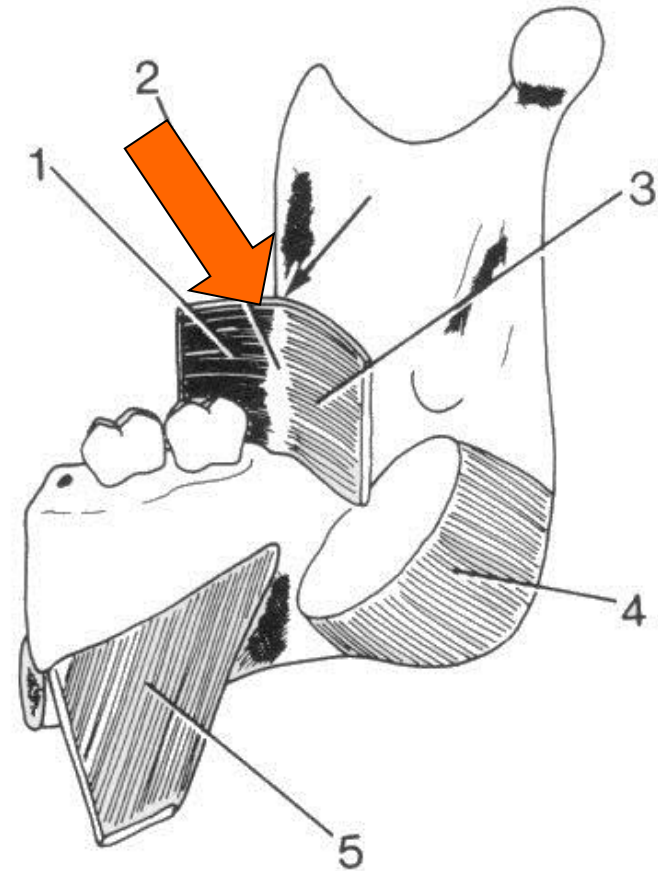
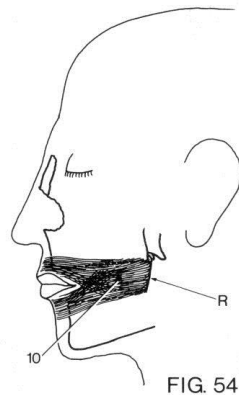
# kindens muskler

- superficielle lag
  - m. risorius (lattermusklen)
- **profunde lag**
  - m. buccinator



# kindens muskler

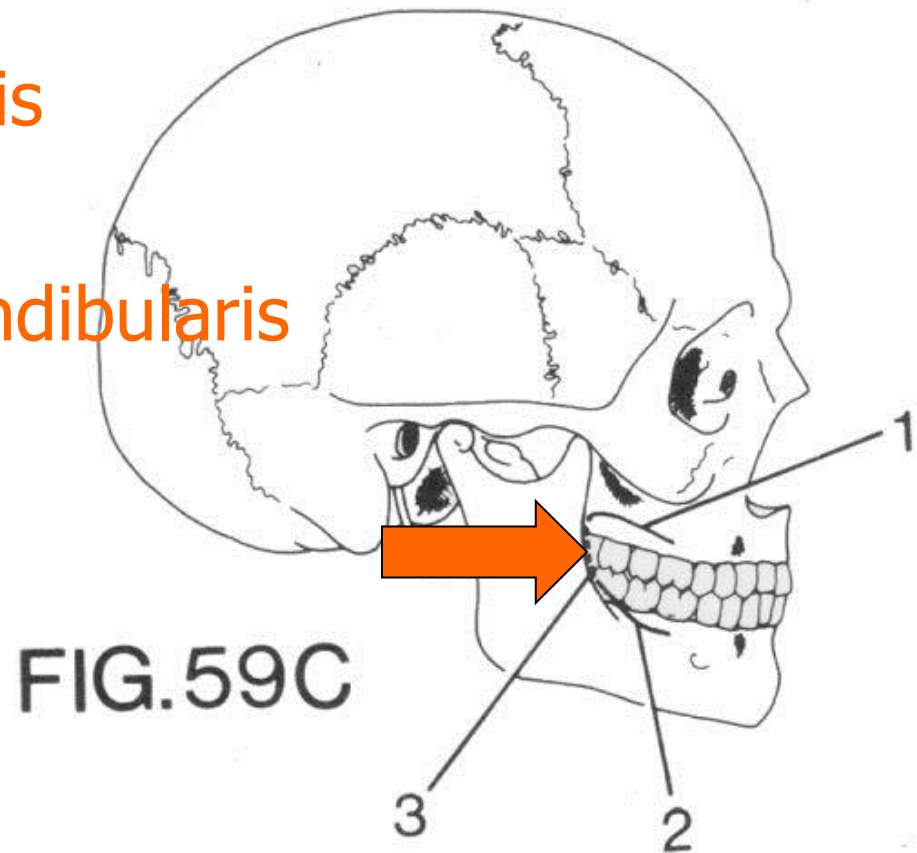
- superficielle lag
  - m. risorius (lattermusklen)
- **profunde lag**
  - m. buccinator



# m. buccinator

## Udspring:

- Processus alveolaris
- Pars alveolaris
- Raphe pterygomandibularis



# raphe pterygomandibularis

mellem knogleområderne:

- hamulus processus pterygoidei
- crista buccinatoria

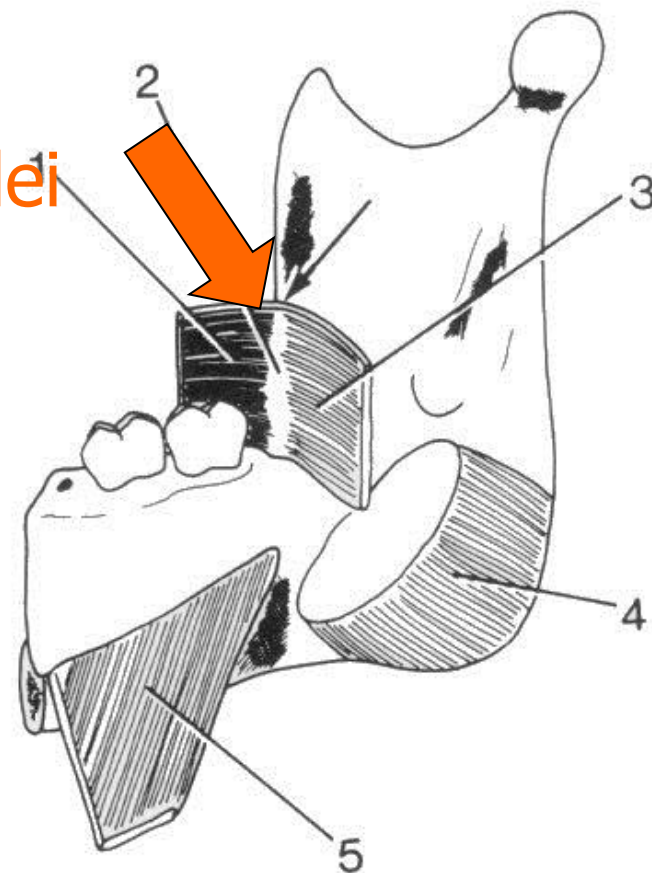
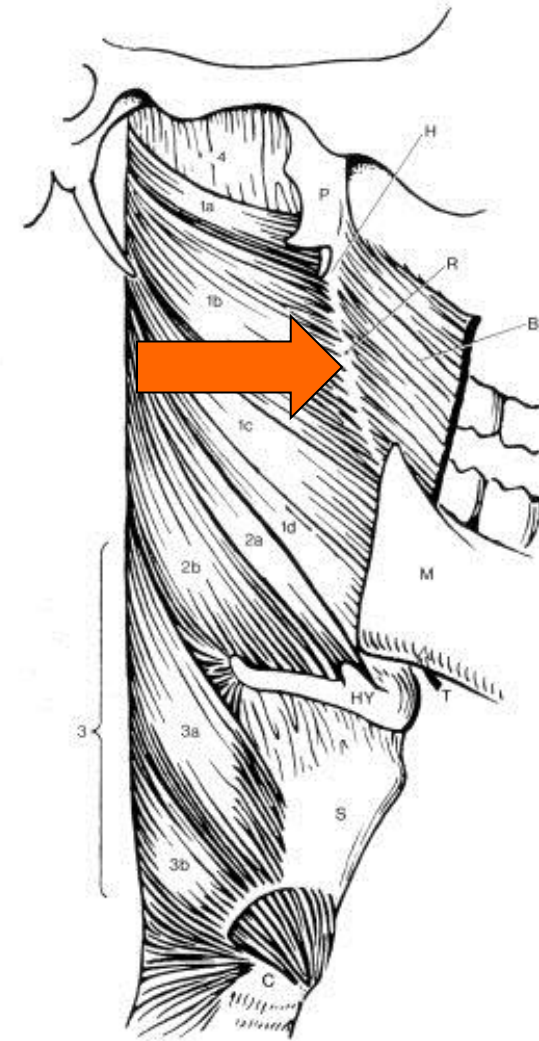


FIG. 59D

# raphe pterygomandibularis

en sene mellem muskler

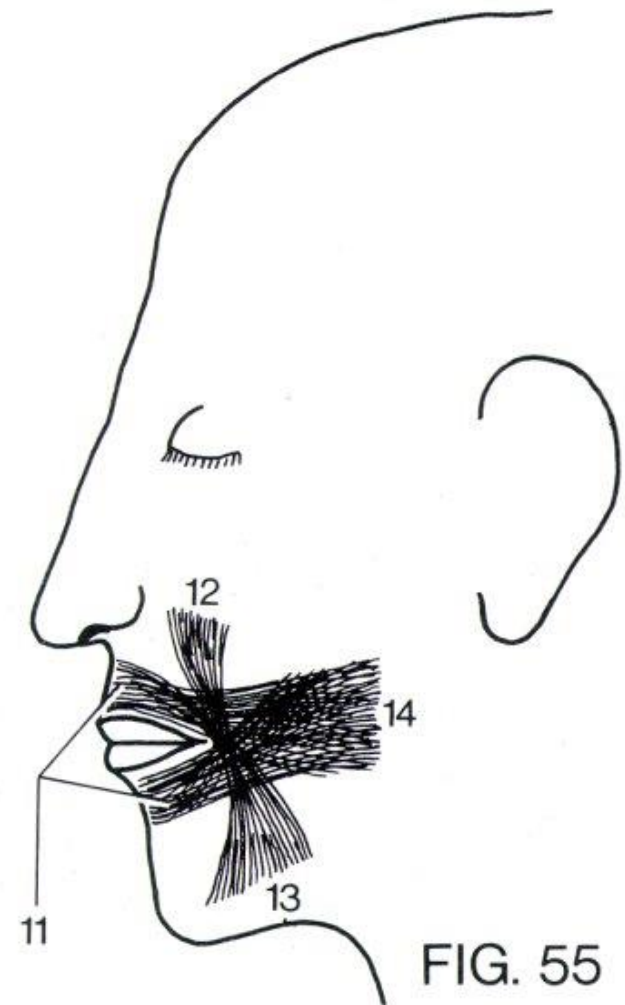
- m. buccinator
- m. buccopharyngeus





# m. orbicularis oris

- får fibre fra 3 muskler:
  - m. buccinator
  - m. levator anguli oris
  - m. depressor anguli oris
- disse muskler hæfter ikke i huden



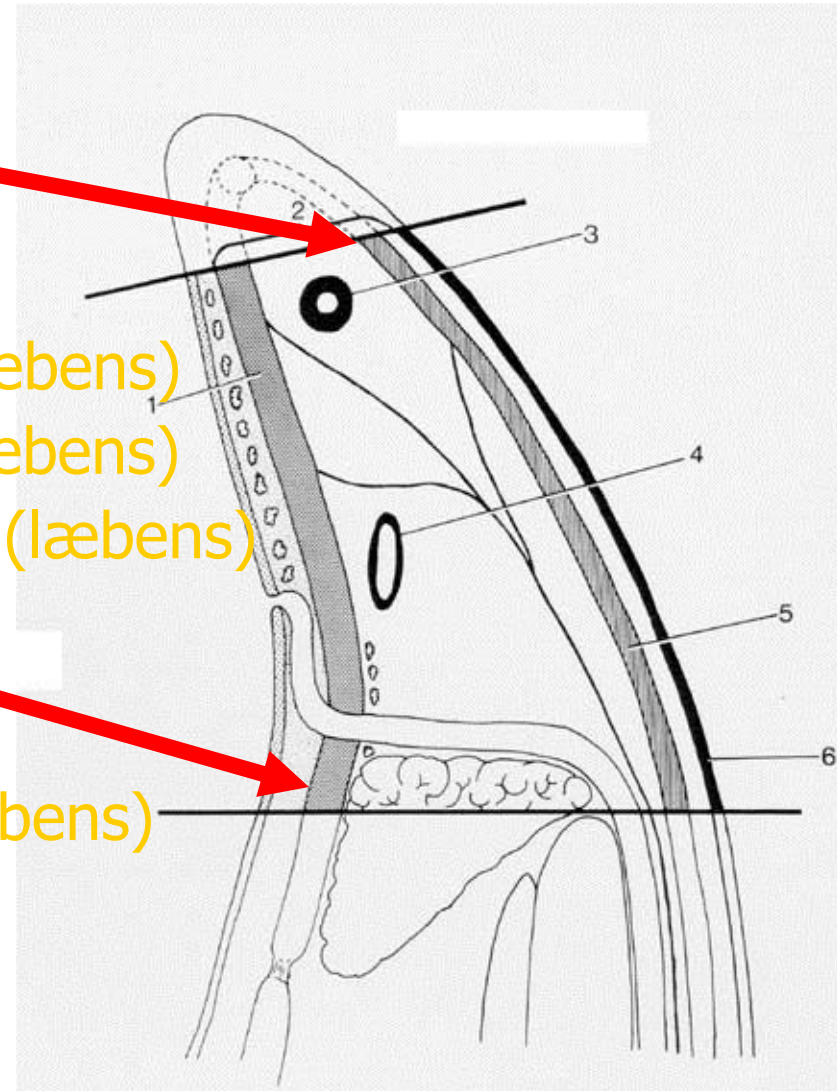
# obs: "kindens muskler"

## • Overfladisk lag

- m. risorius (kindens)
- platysma (halsens)
- m. zygomaticus major (læbens)
- m. zygomaticus minor (læbens)
- m. depressor anguli oris (læbens)

## • Underliggende lag

- m. buccinator (kindens)
- m. levator anguli oris (læbens)



# innervation

- mundens muskler:  
grene fra *n. facialis*

