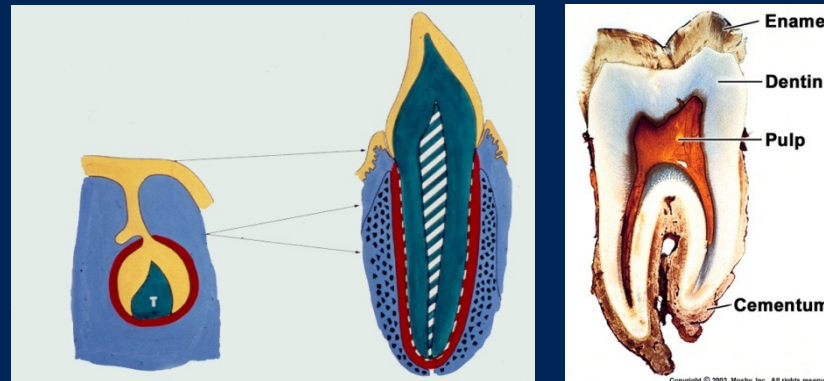


Tandudvikling

Introduktion af tandudvikling



23. sep 2022

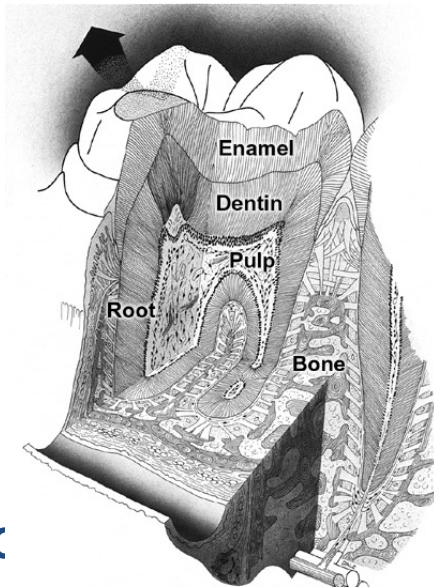


Mælketandsæt med nye tænder på vej

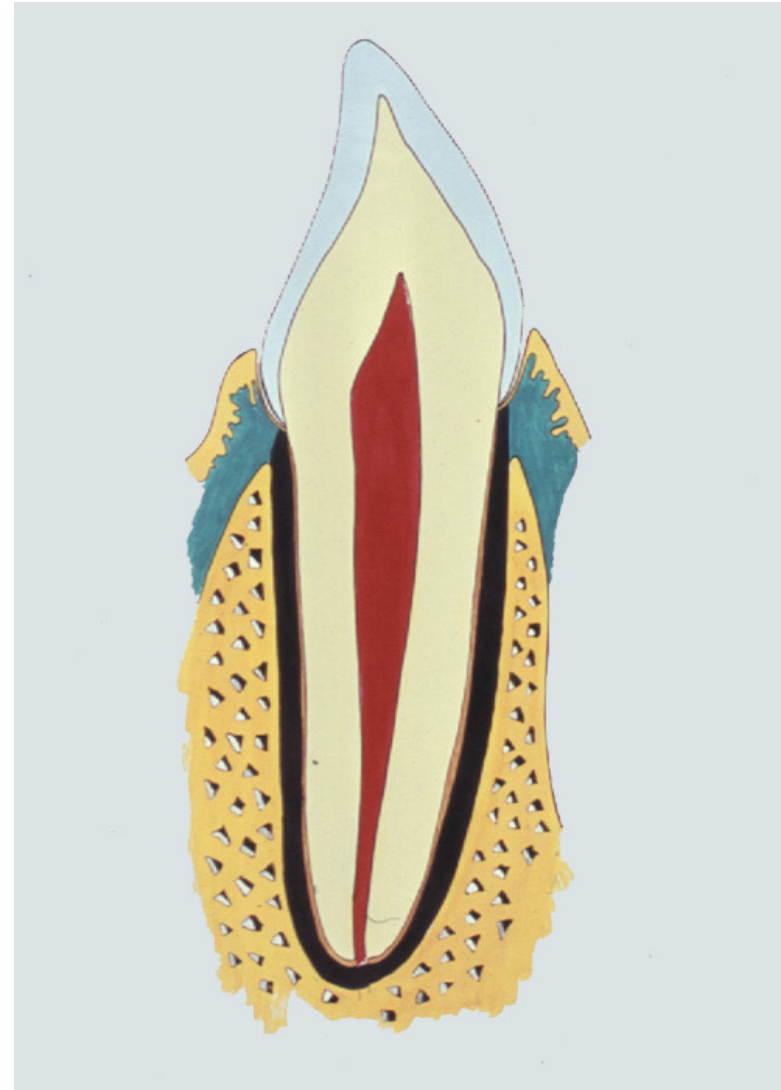
Db-42/9-21-22-23

TANDORGANET

- TANDEN
 - krone
 - rod
- OMGIVENDE VÆV



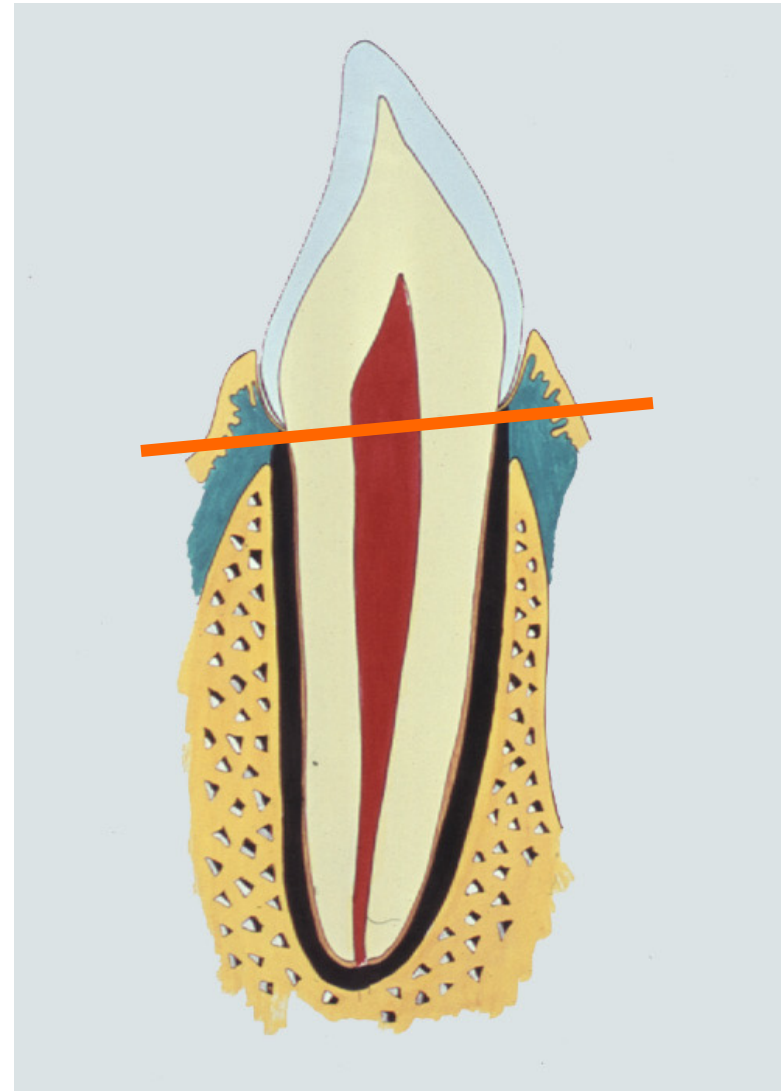
HL, TA, IOC



TANDORGANET

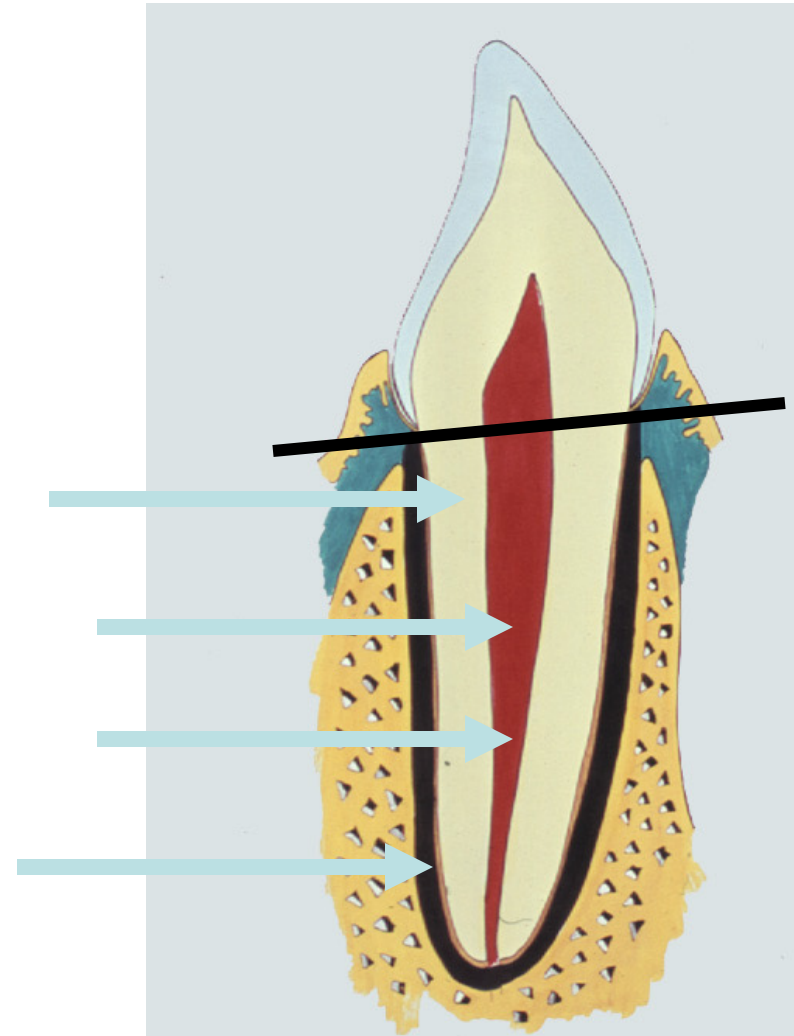
KRONE

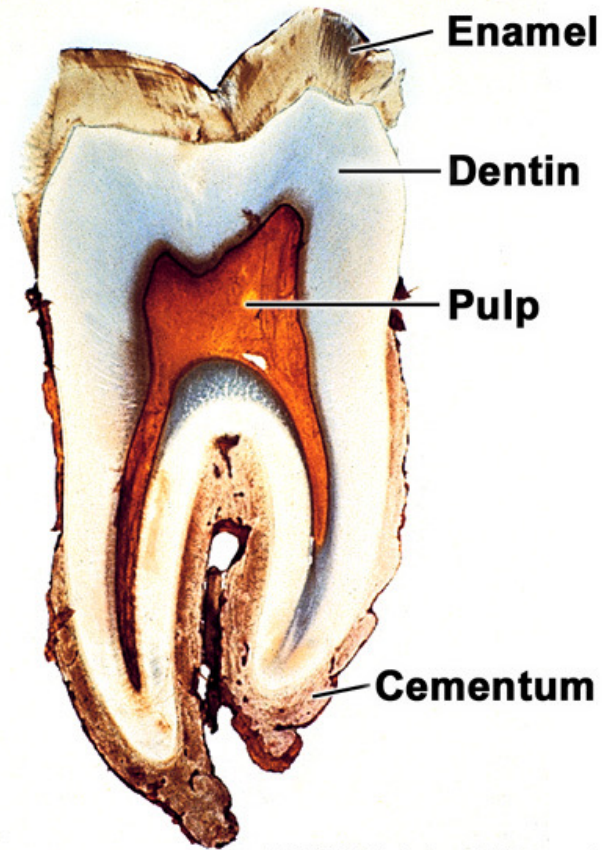
- **emalje**
- **dentin**
"tandben"
- **pulpa**
pulpa dentis
"pulpakammer"
"nerven"
"tandmarven"



TANDORGANET ROD

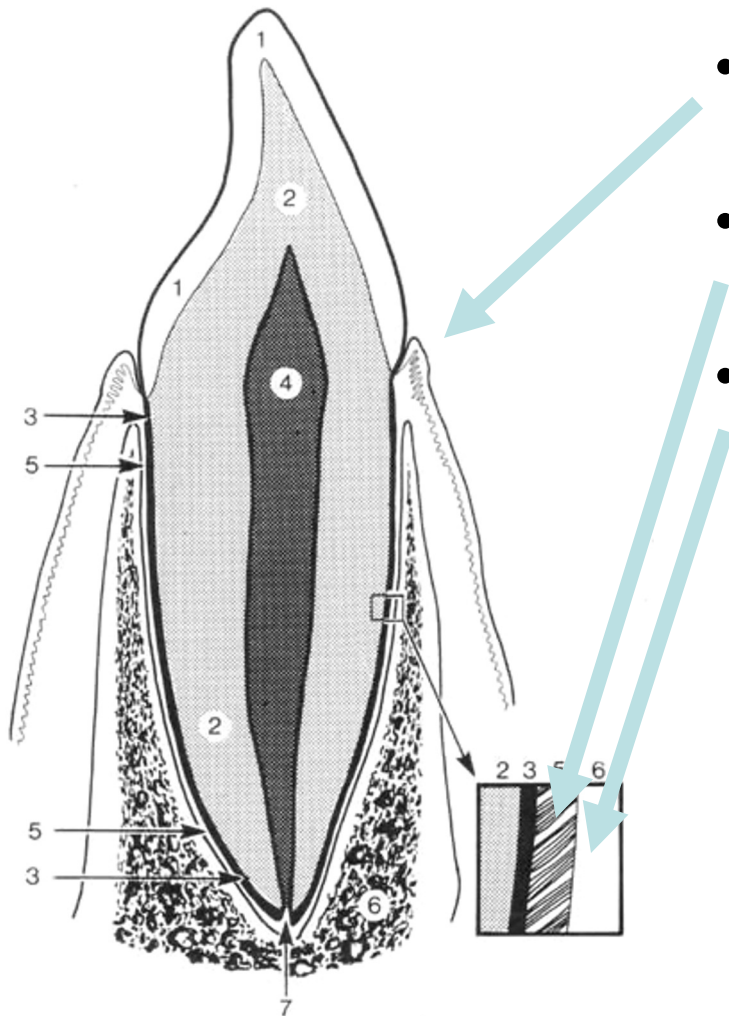
- dentin
- rodkanal
- pulpa dentis
- rodcement





Copyright © 2003, Mosby, Inc., All rights reserved.

TANDORGANET OMGIVENDE VÆV

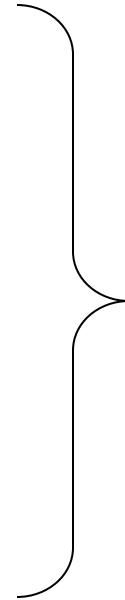

- **marginale gingiva**
 - tandkødskraven
- **rodhinden**
 - membran (kollagene fibriller)
- **processus/pars alveolaris**
 - alveole begrænses af alveolevæg
 - gingiva/slimhinde

UDVIKLING AF TANDORGAN

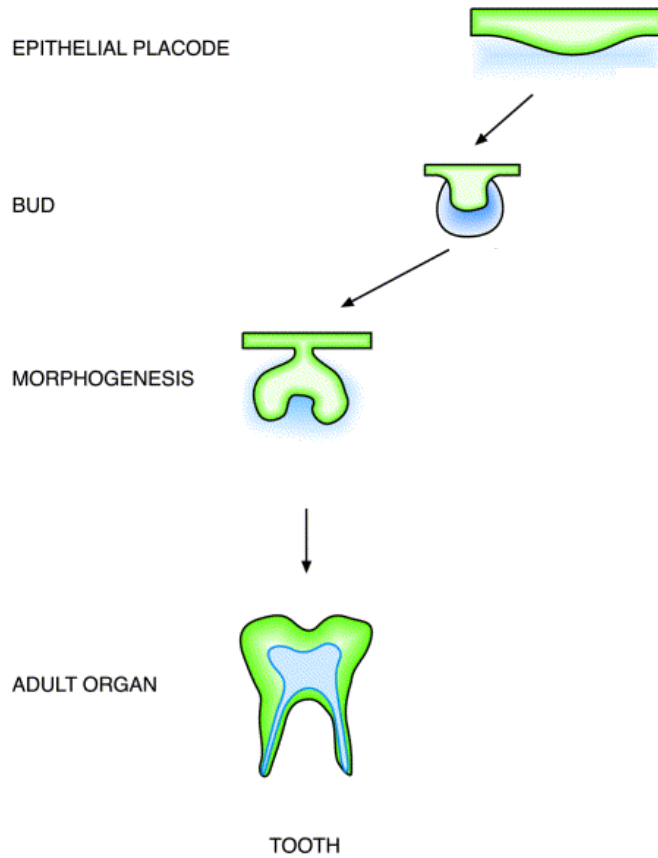
ORALT EPITEL

BINDEVÆV



TANDANLÆG

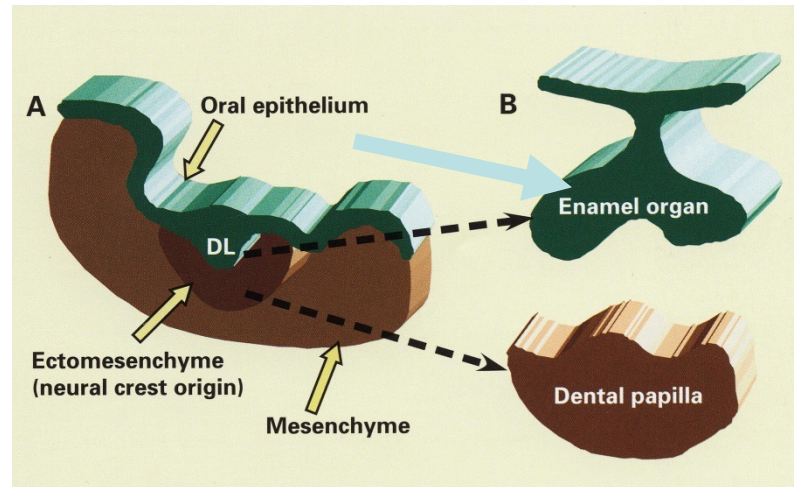
UDVIKLING AF TANDORGAN



TANDORGAN

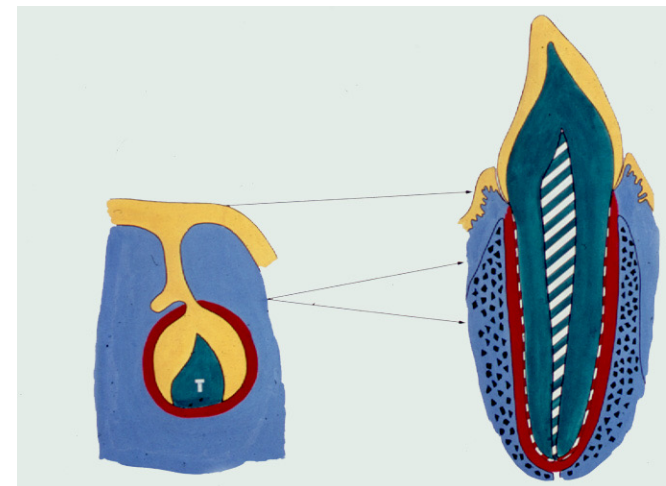
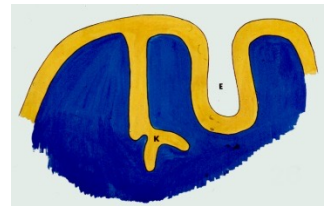

Epitel differenzierer:

- emaljeorgan



Her gennemgås:

1. VESTIBULARLISTE OG TANDLISTE
2. TANDORGAN
3. TANDKRONENS UDVIKLING
4. UDVIKLING AF ROD, RODHINDE OG PULPA
5. ERSTATNINGSTANDLISTER OG TILVÆKSTLISTER
6. MINERALISERING OG FREMBRUD

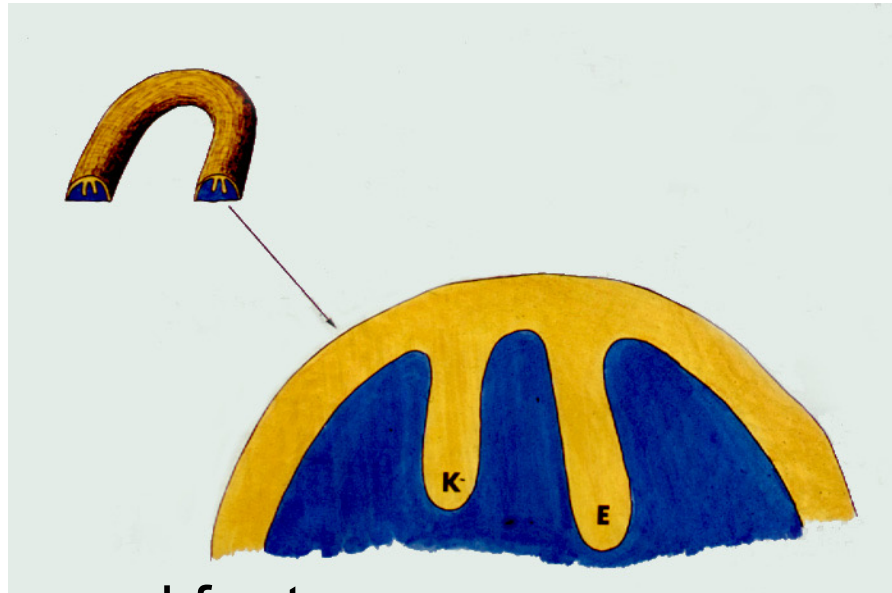


1. VESTIBULARLISTE OG TANDLISTE




- Kæbevold
- Mundhulepitel og bindevæv

1. VESTIBULARLISTE OG TANDLISTE




- Epitel vokser ned fra toppen

VESTIBULARLISTE



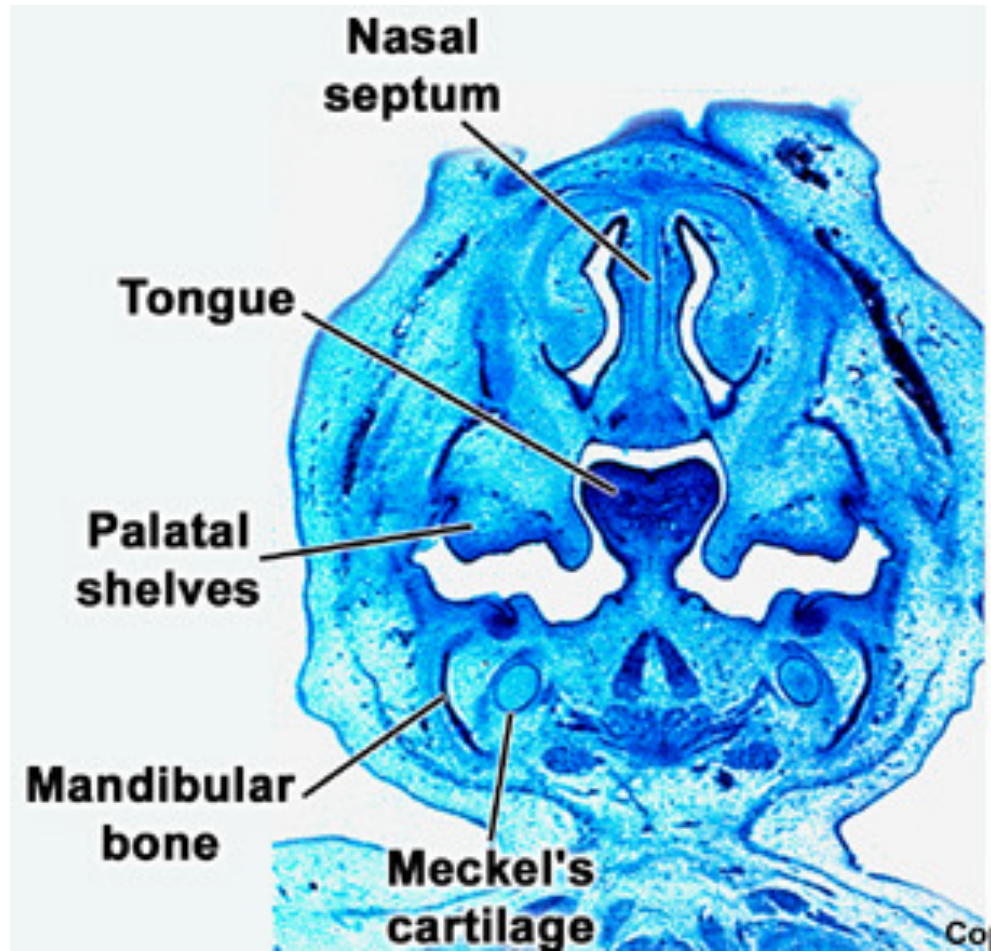
- vestibularlisten bliver til VESTIBULUM ORIS

TANDLISTE



- tandlistens epitel anlægger TANDORGANER

Frontalsnit




TANDLISTE

Tandorganet udvikles over tre stadier:

- **knop-stadiet**
- **kappe-stadiet**
- **klokke-stadiet**

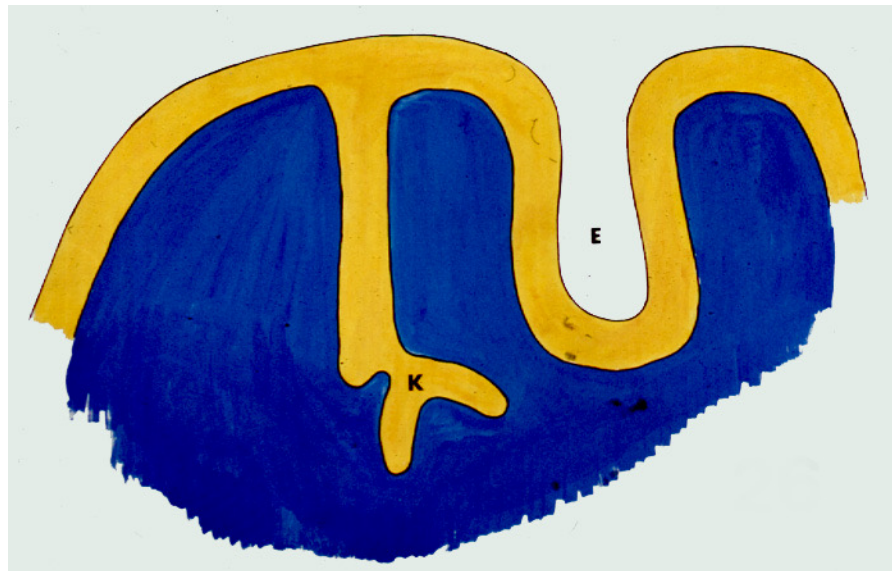
2. TANDORGAN

- .."KNOP"-STADIET



TANDORGAN

- "KAPPE"-STADIET

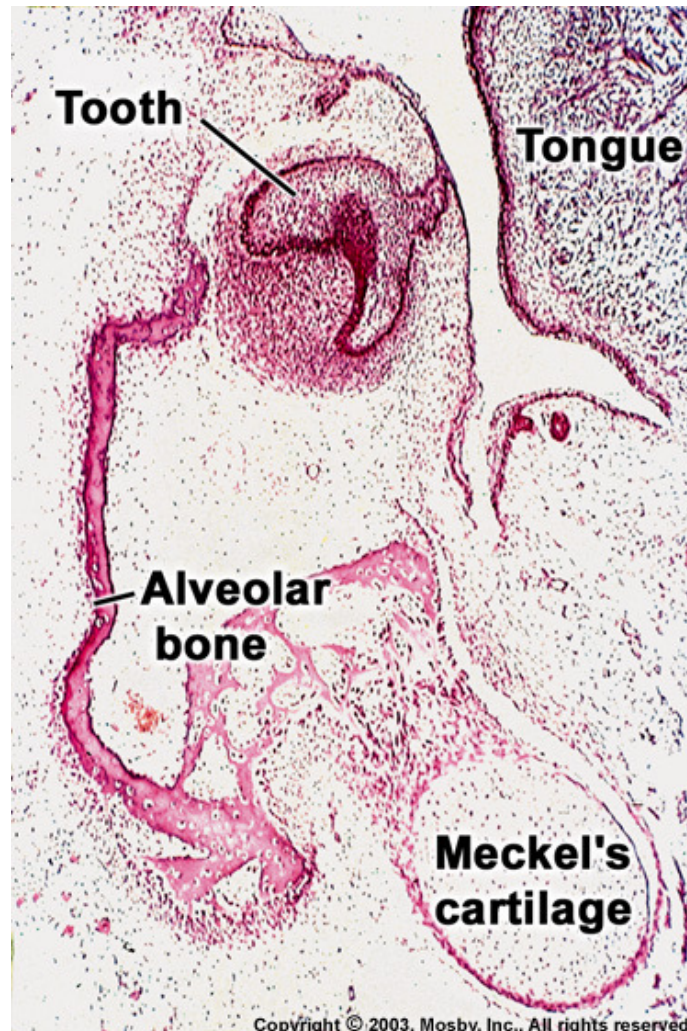


TANDORGAN

- "KLOKKE"-STADIET



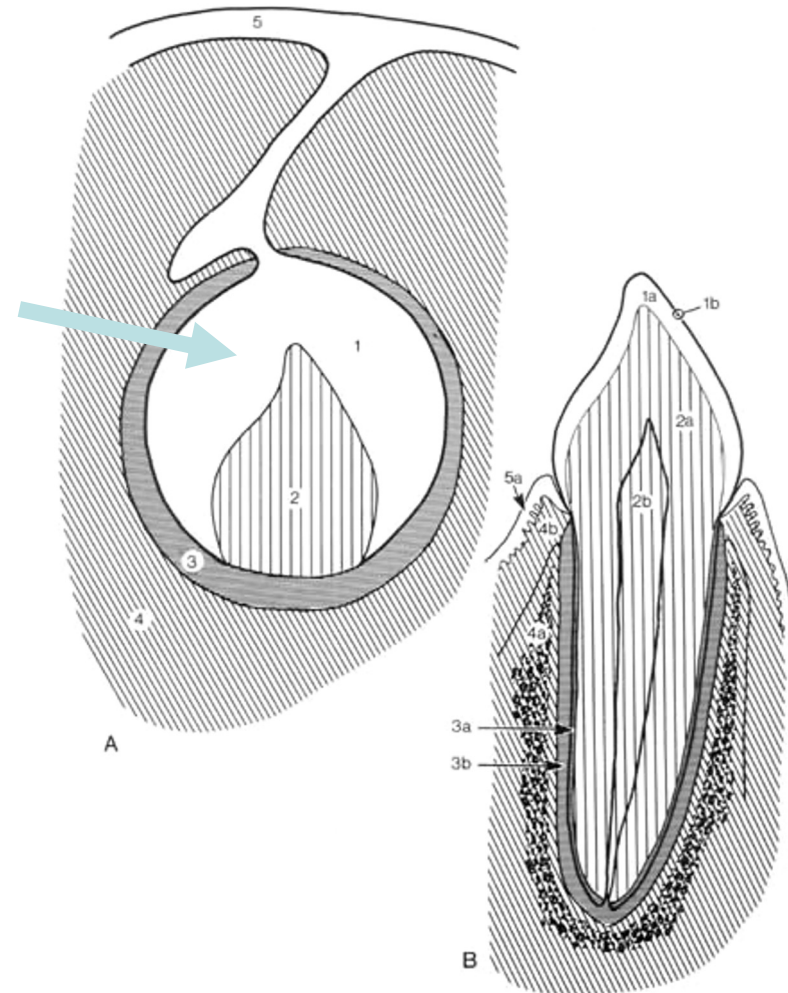
Frontalsnit



TANDORGAN

Epitel differentierer:

- emaljeorgan



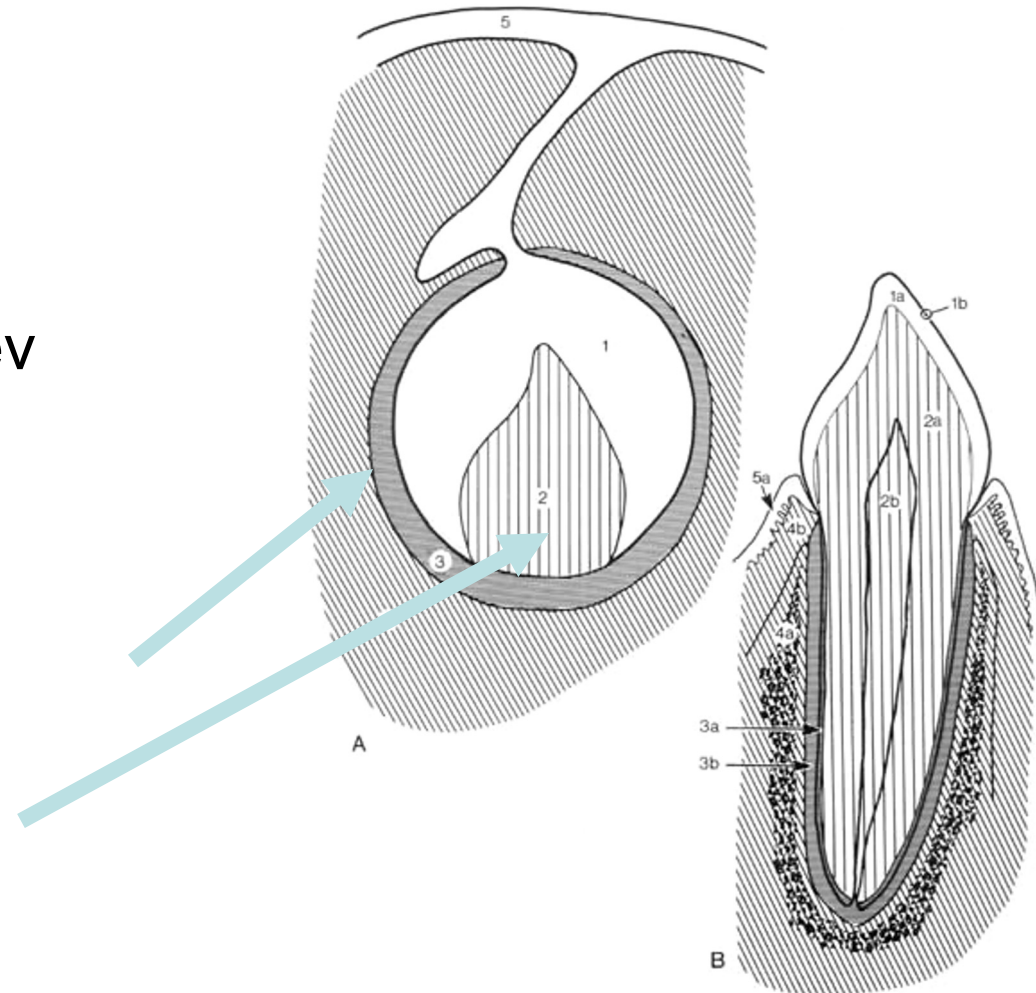
TANDORGAN

Epitel differentierer:

- emaljeorgan

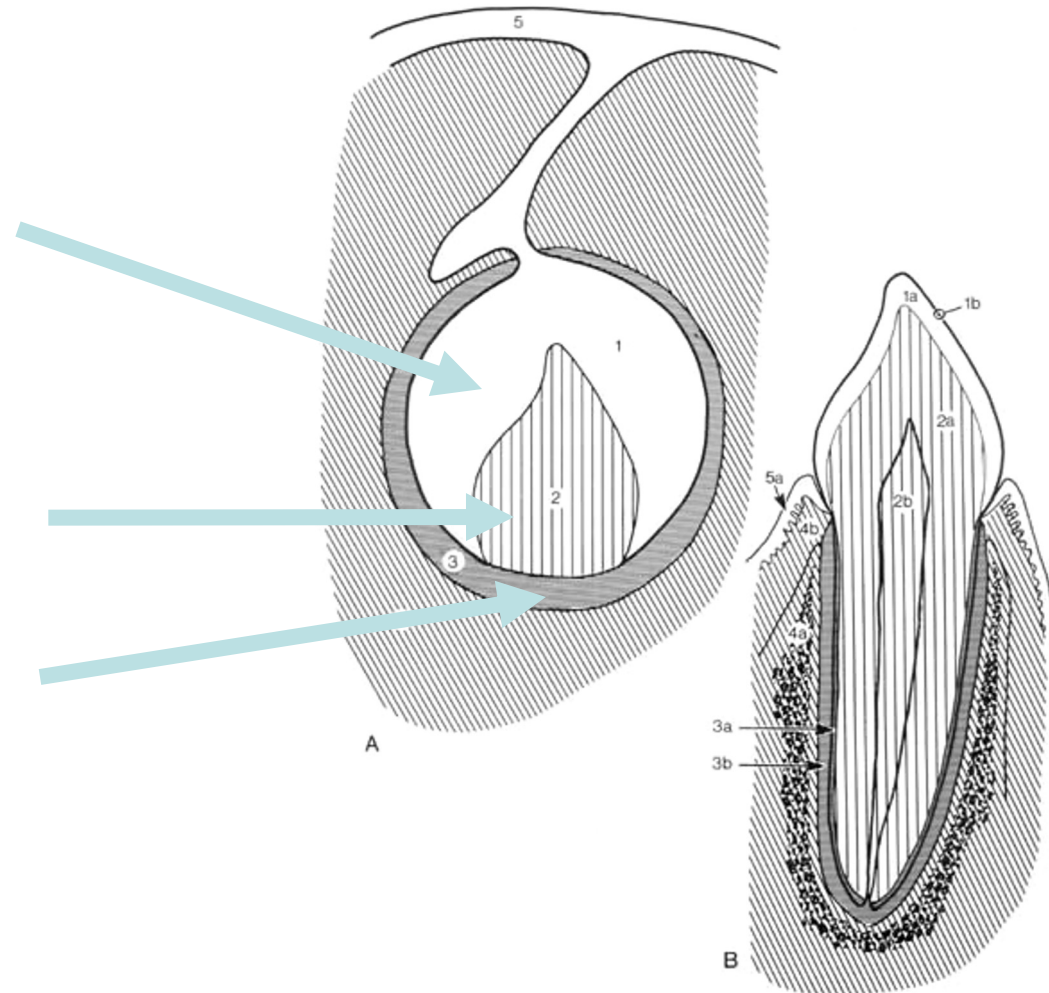
Mesenkymalt bindevæv
differentierer:

- tandsæk (folliklen)
- tandpapil



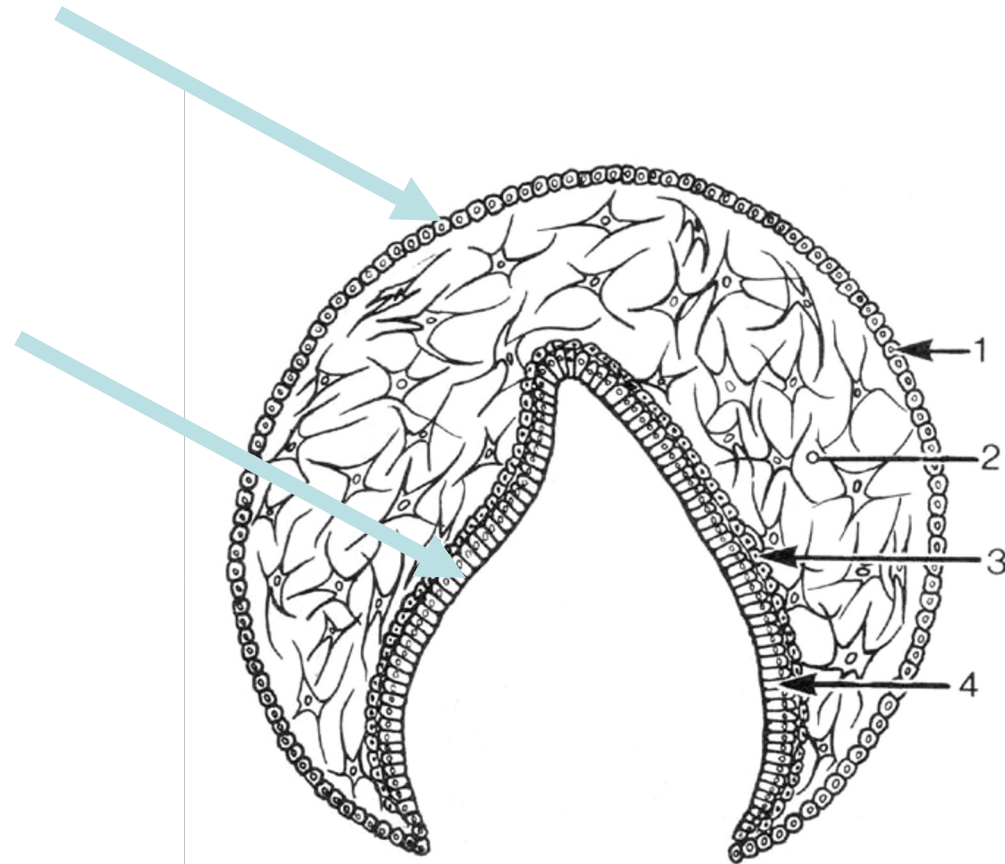
TANDORGAN

- EMALJEORGAN
 - 4 lag celler
 - ikke emalje endnu!
- TANDPAPIL
 - bindevæv indeni
- TANDSÆK
 - bindevæv udenom emaljeorgan



EMALJEORGAN

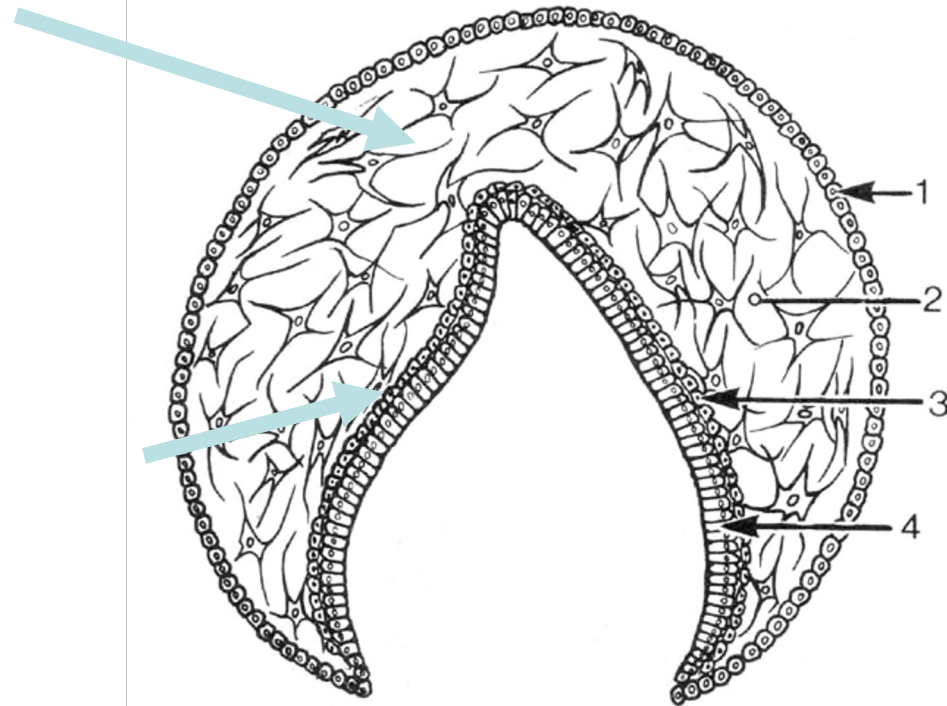
- Ydre emaljeepitel
 - kubiske celler
- Indre emaljeepitel
 - prismatiske celler



EMALJEORGAN

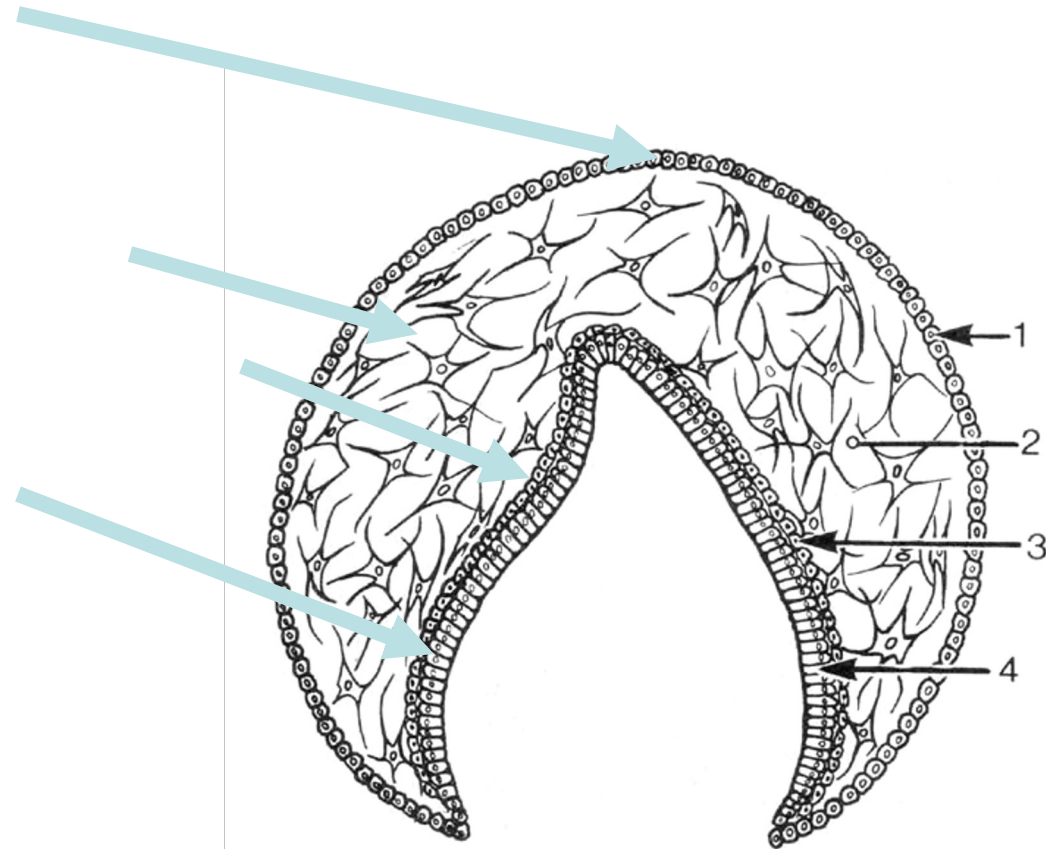
Mellemliggende emaljeepitel:

- Stratum reticulare
 - stjerneformede celler
 - der anastomoserer
 - amorf grundsubstans
- Stratum intermedium
 - tætliggende flade celler



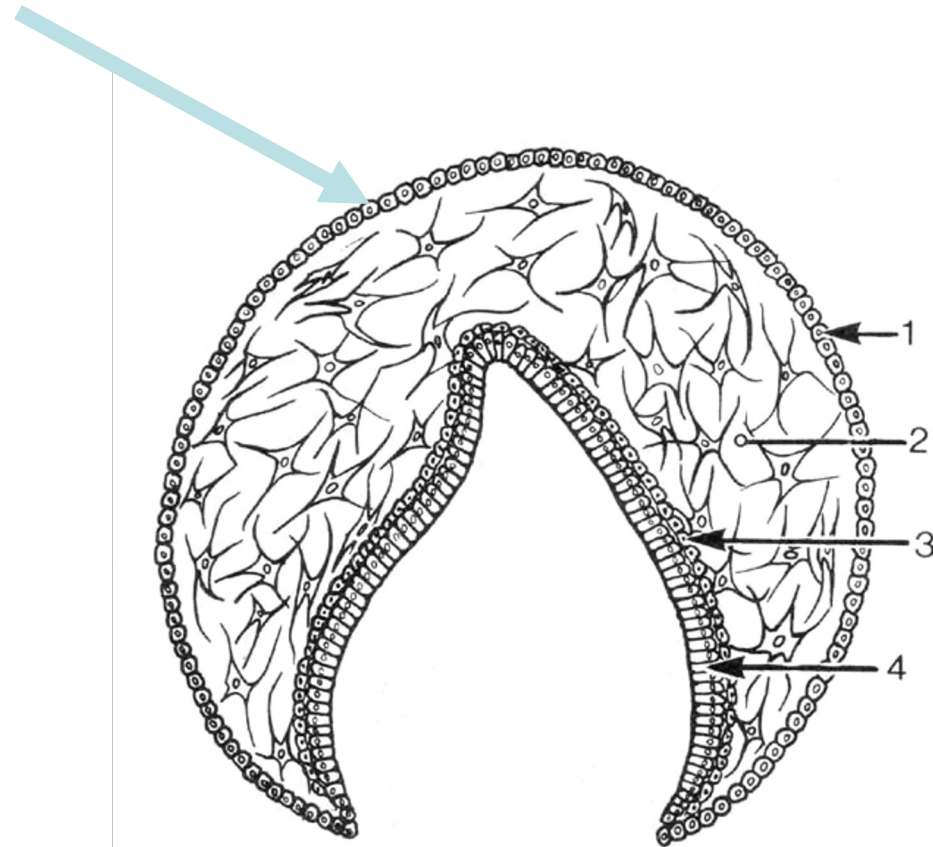
EMALJEORGANETS 4 LAG

- Ydre emaljepitel
- Stratum reticulare
- Stratum intermedium
- Indre emaljepitel



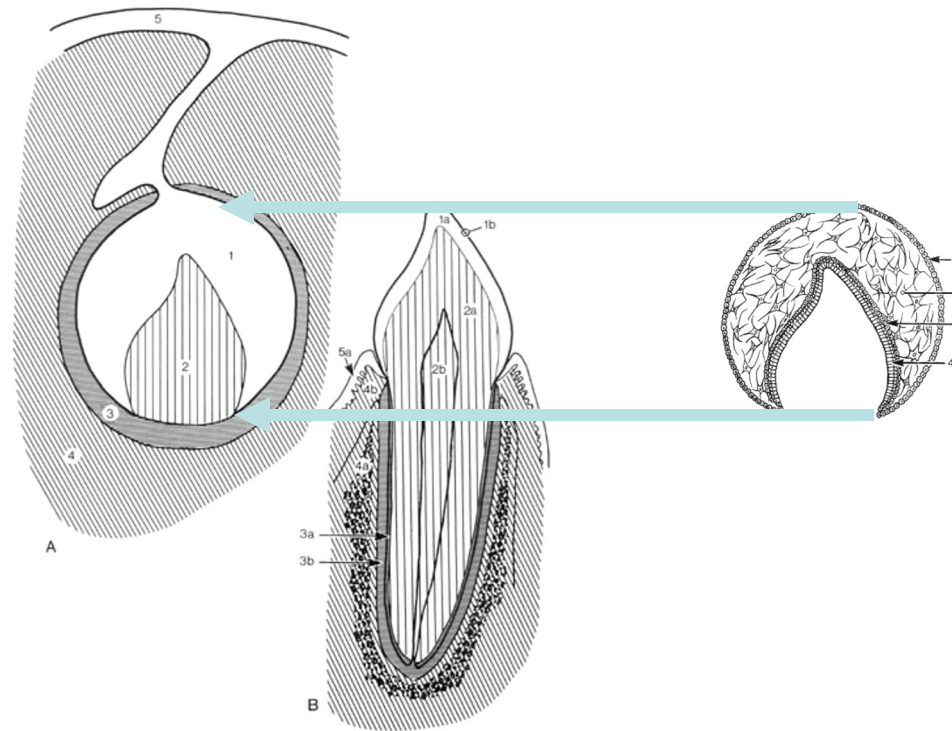
OBS

- Ydre emaljeepitel
bør ikke forveksles
med bindevæv i
tandsækken



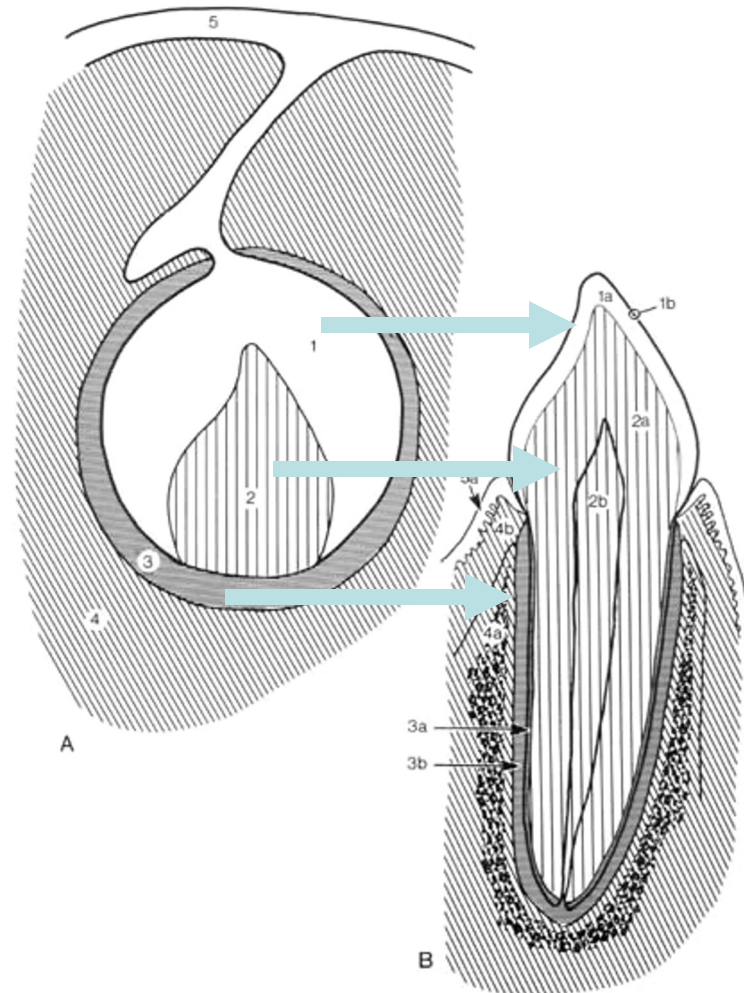
OBS

- Emaljeorganets 4 cellelag (emaljeorganet) er en del af tandorganet



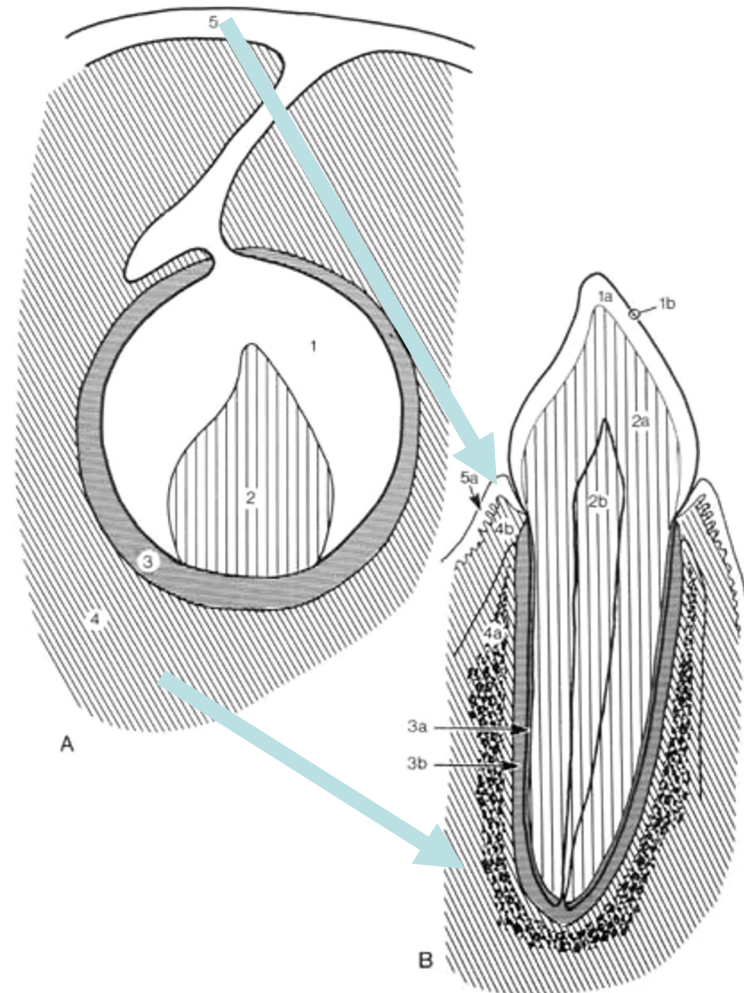
UDVIKLING AF TANDANLÆG

- EMALJEORGAN
 - Emalje
 - Emaljehinde ses på nyerupterede tænder
- TANDPAPIL
 - Dentin
 - Pulpa
- TANDSÆK
 - Cement
 - Rodhinde



OMGIVENDE VÆV

- EPITEL PÅ KÆBEVOLD
 - Gingiva epitel
- BINDEVÆV UDENOM TANDSÆKKEN
 - Alveoleknogle
 - Gingiva's bindevæv



UDVIKLING AF TANDANLÆG

Mundhuleepitel

Emalje

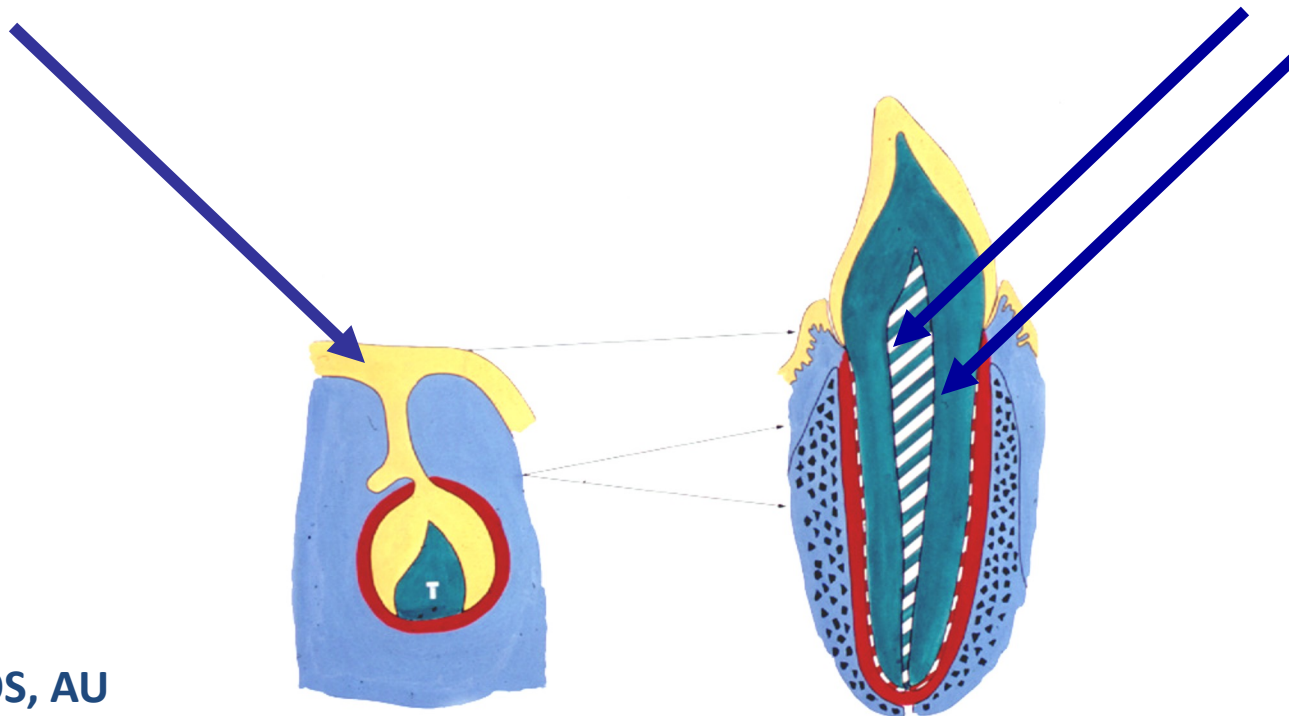
Gingiva

Bindevæv

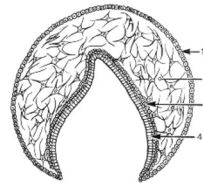
Dentin

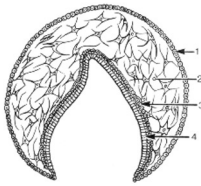
Pulpa

Resten



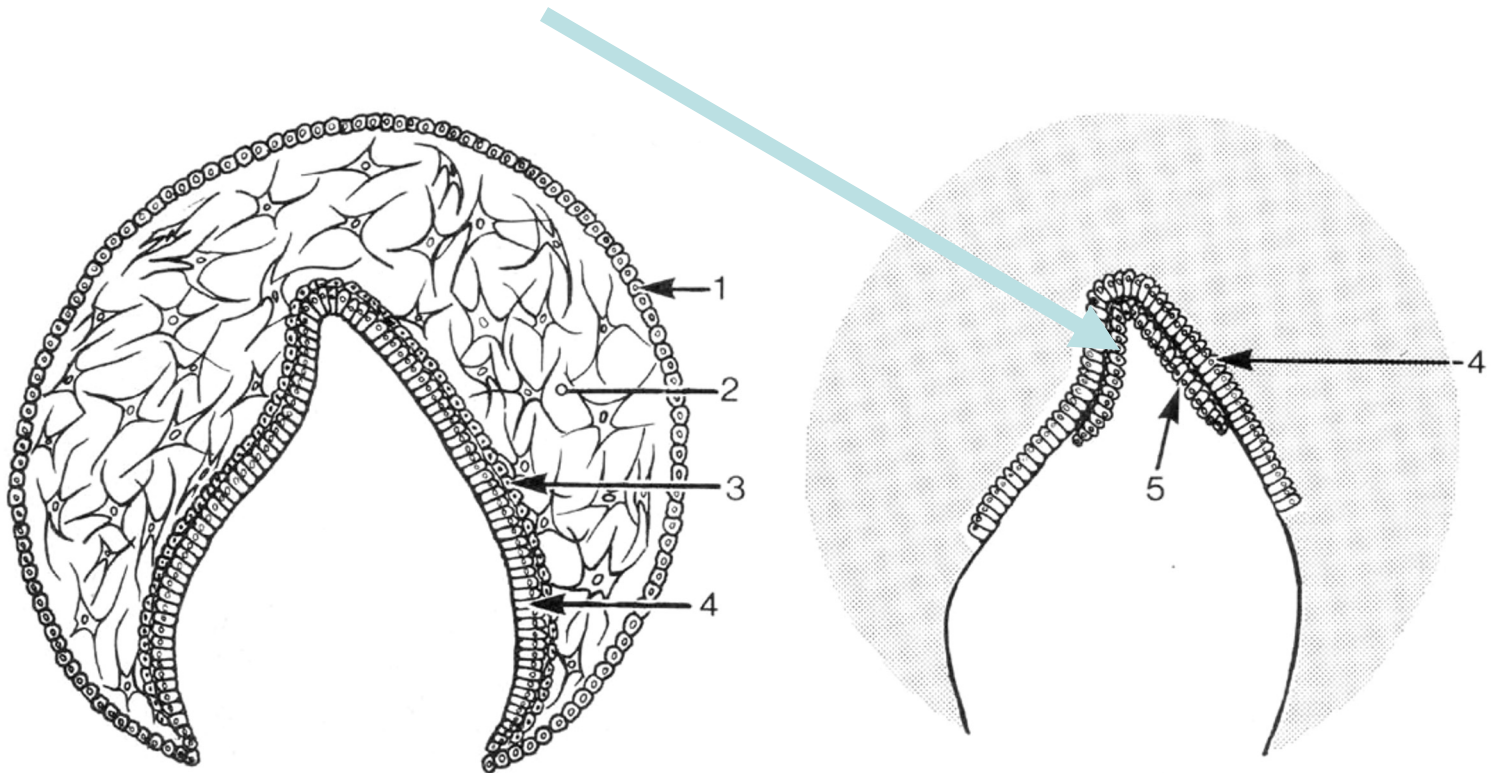
3. TANDKRONENS UDVIKLING

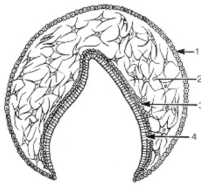




ODONTOBLASTER

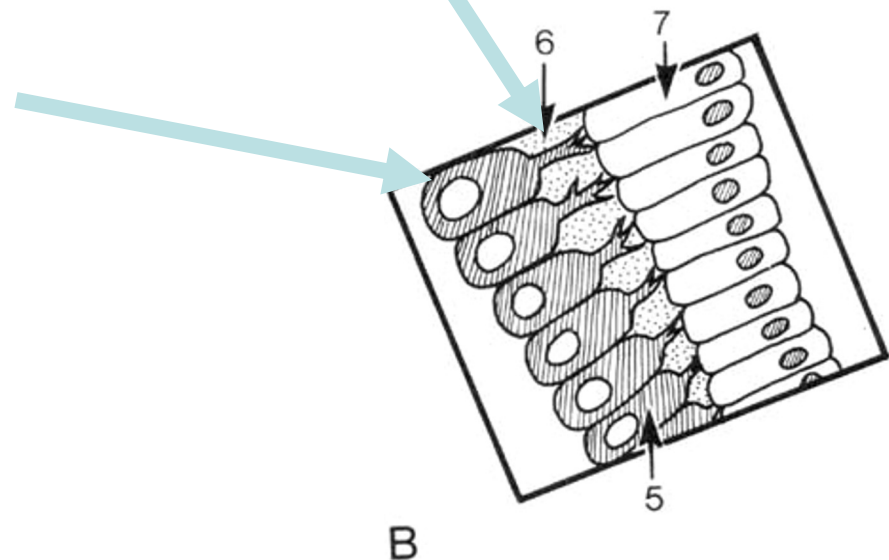
- 'mesenchymale celler' i tandpapillen differentierer til odontoblaster

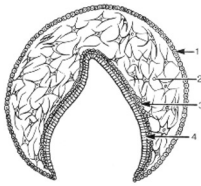




ODONTOBLASTER

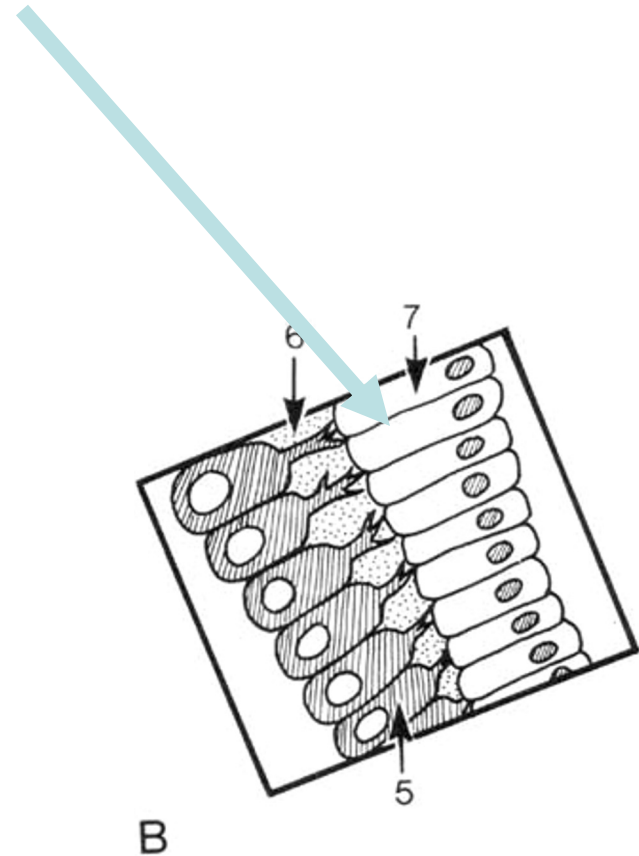
- danner prædentin (umineraliseret)
- odontoblasterne har udløbere

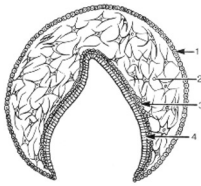




AMELOBLASTER

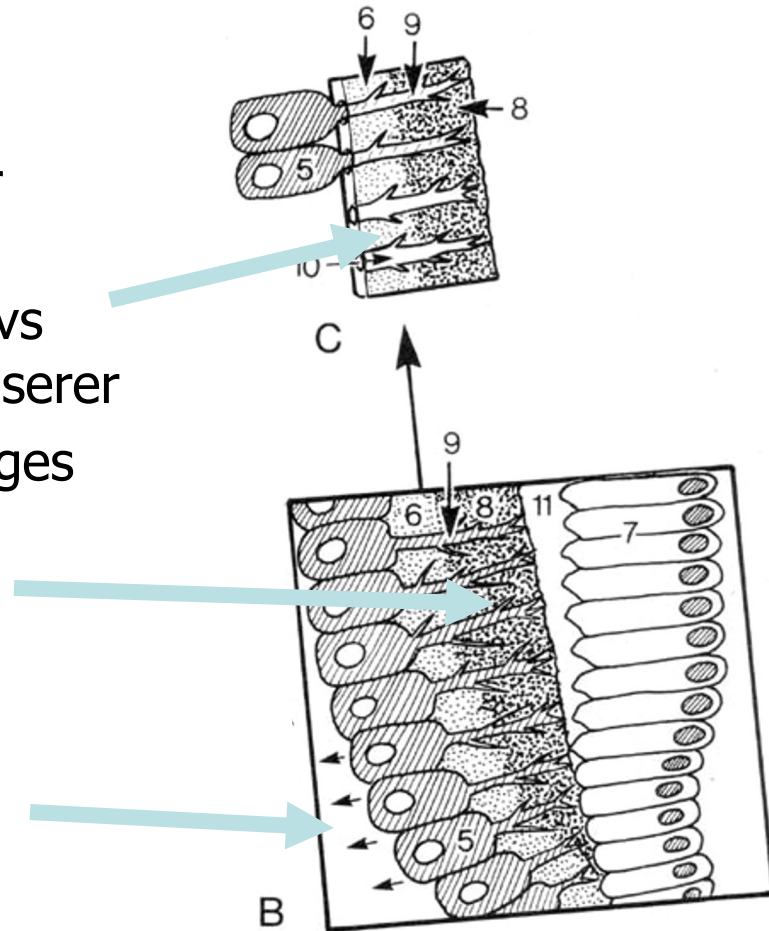
- indre emaljeepitel differentierer til ameloblaster

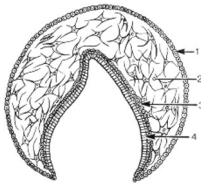




PRÆDENTIN

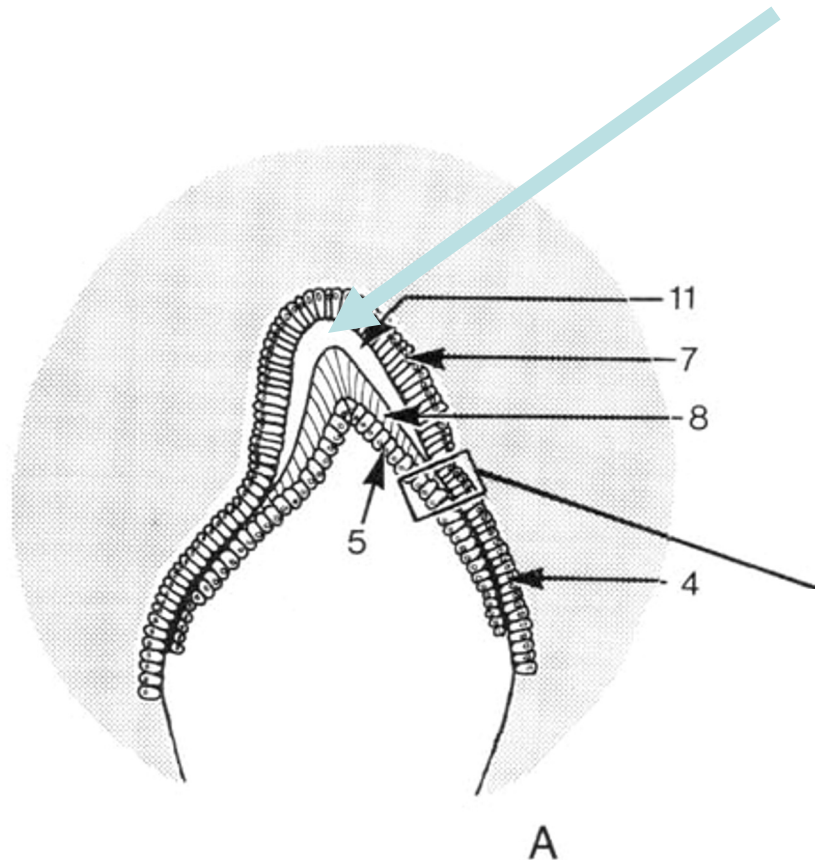
1. odontoblaster danner prædentin
2. krystaller udfældes dvs prædentinen mineraliserer
3. odontoblaster forlænges

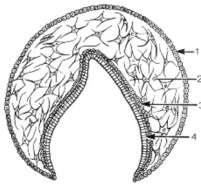




AMELOBLASTER

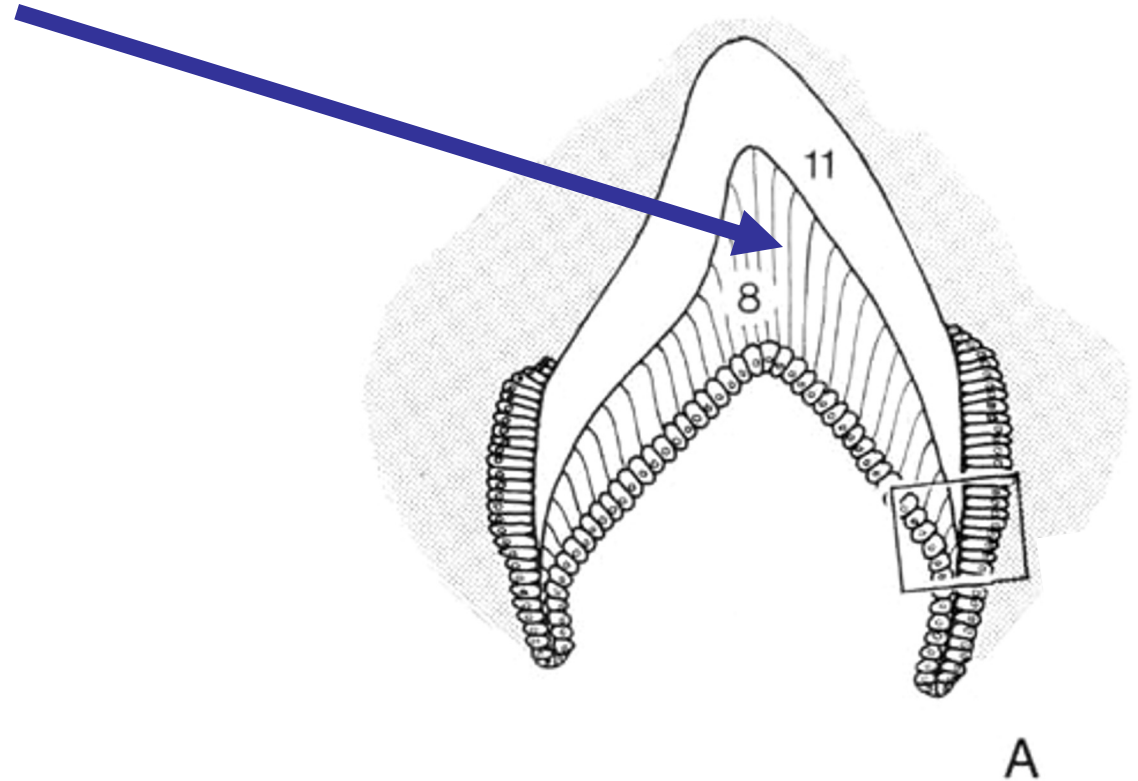
- ameloblasterne danner emalje-grundsubstans (i daglig tale "emalje-matrix")

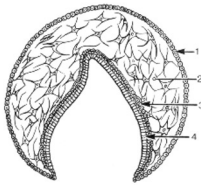




DENTIN

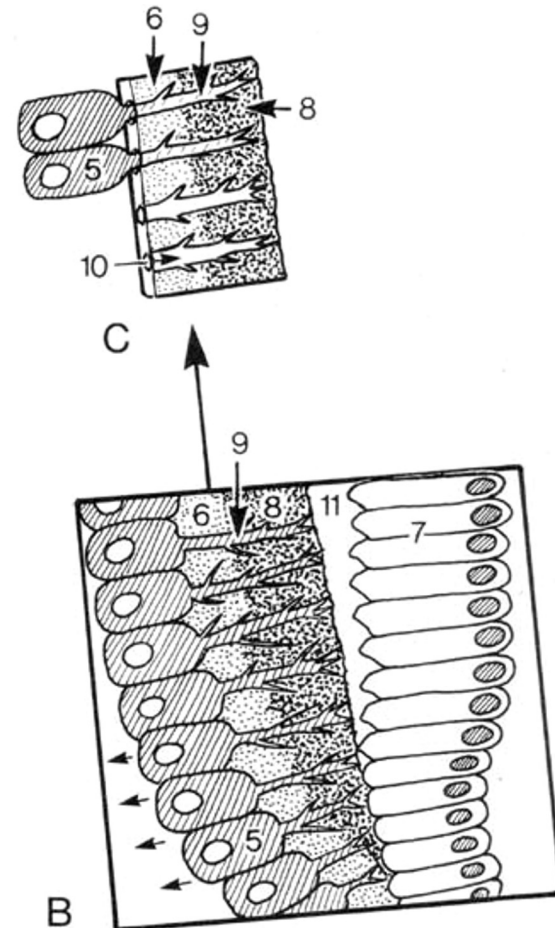
- Dentin
 - Mineraliseret grundsubstans

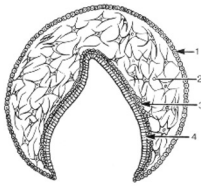




ODONTOBLASTER

- **Odontoblastudløber**
 - Indlejret i dentinkanaler
- **Cellelegeme**
 - Ligger på dentinens inderside
- **Prædentin**
 - Fibriller
 - Amorf grundsubstans
- **Dentin**
 - Mineraliseret grundsubstans (dentin matrix)

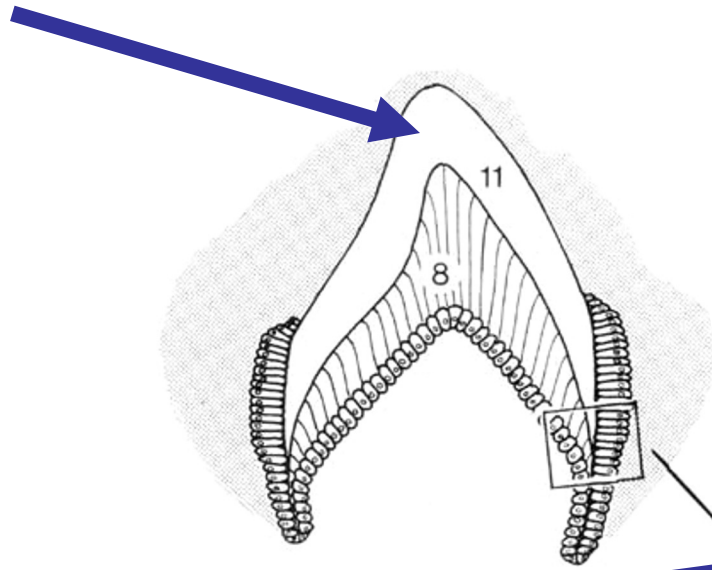




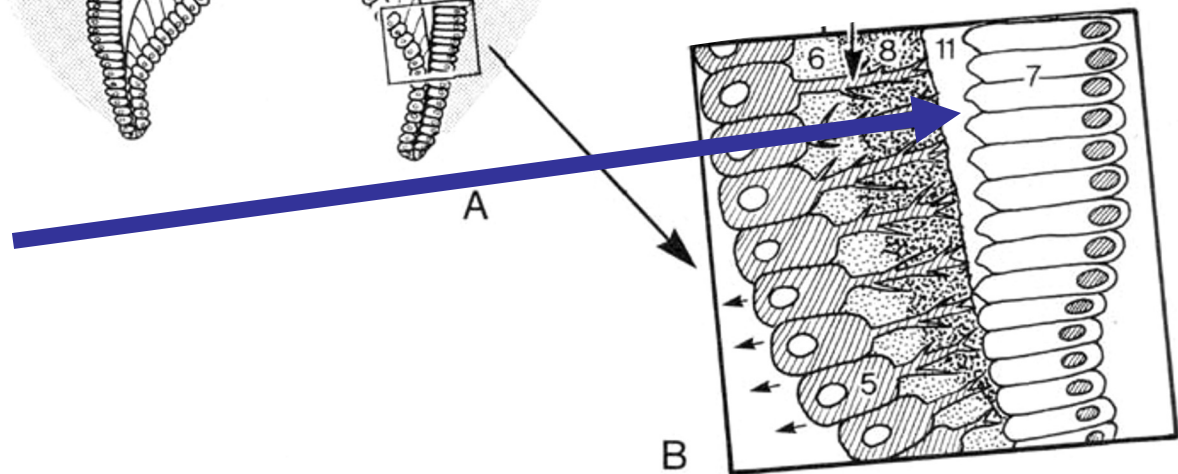
AMELOBLASTER

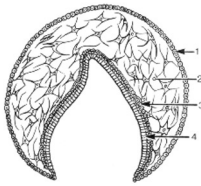
- **Emalje**

- Mineraliseret grundsubstans



- Amorf grundsubstans

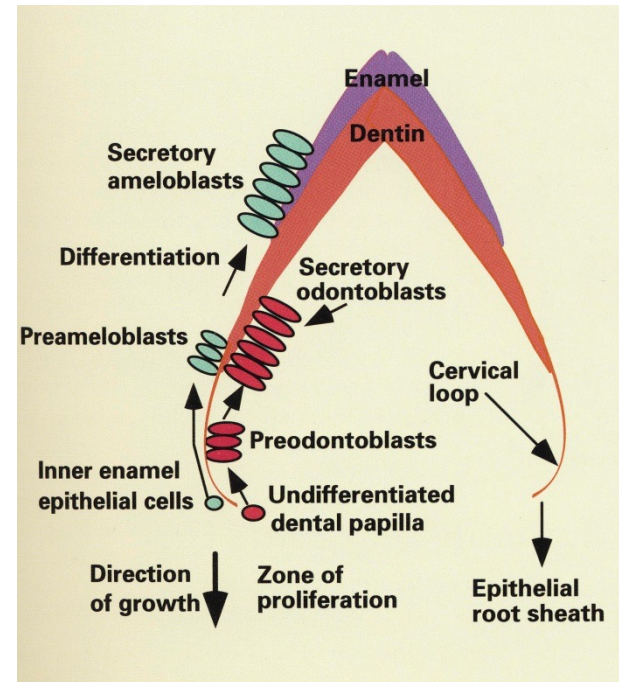


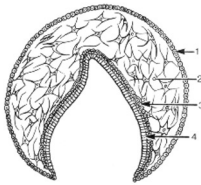


EMALJEDANNELSE

AMELOGENESE (histologer):

- sekretionsfase
- Modningsfase

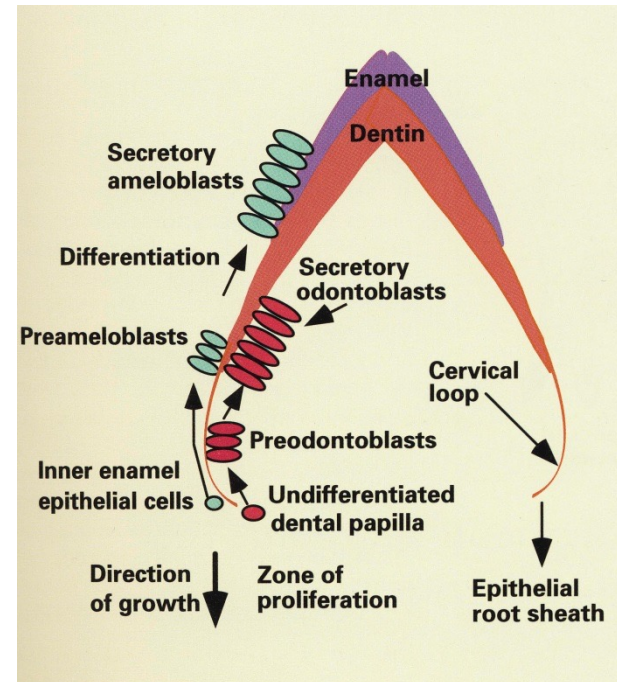


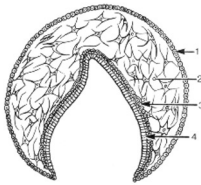


EMALJEDANNELSE

AMELOGENESE (klinikere):

- sekretionsfase
- Mineraliseringsfase
- Modningsfase

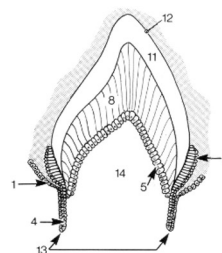




SAMMENFATNING

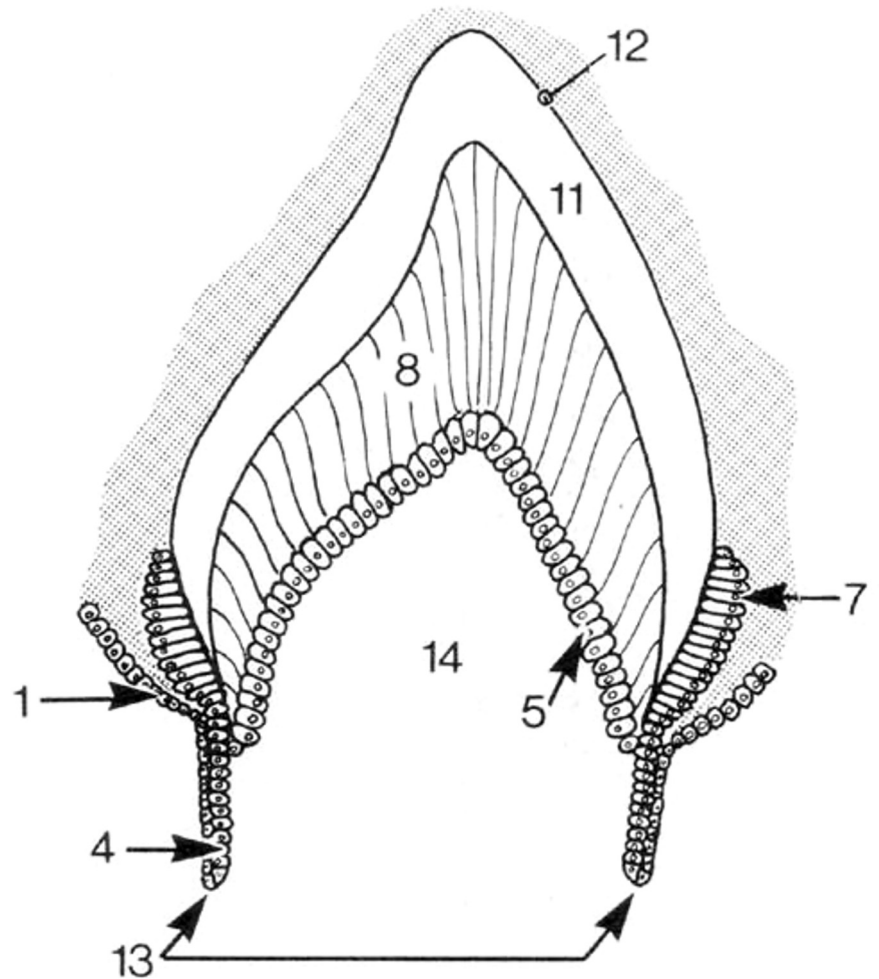
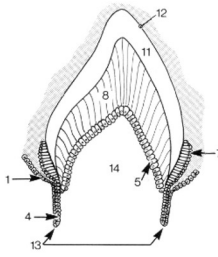
1. epitel danner en knop
2. emaljeepitel inducerer differentiering af mesenchymale celler i bindevævet
3. signal-interaktion mellem epitel og mesenchym
4. mesenchym kondenseres som en lokal fortætning af celler
5. epitelknop vokser videre over kappe og klokke stadierne
6. mesenchymceller i papillen differentierer til odontoblaster
7. odontoblaster danner prædentin som er ikke-mineraliseret
8. indre emaljeepitelceller omdannes til ameloblaster
9. prædentin mineraliserer og bliver til dentin
10. ameloblaster danner emalje-grundsubstans dvs en matrix, der mineraliserer...

4. UDVIKLING AF ROD, RODHINDE OG PULPA

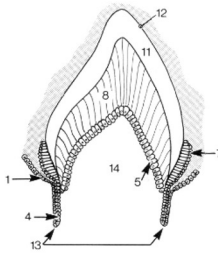


Tandorganets kant

- vokser i dybden
- udstanser roden



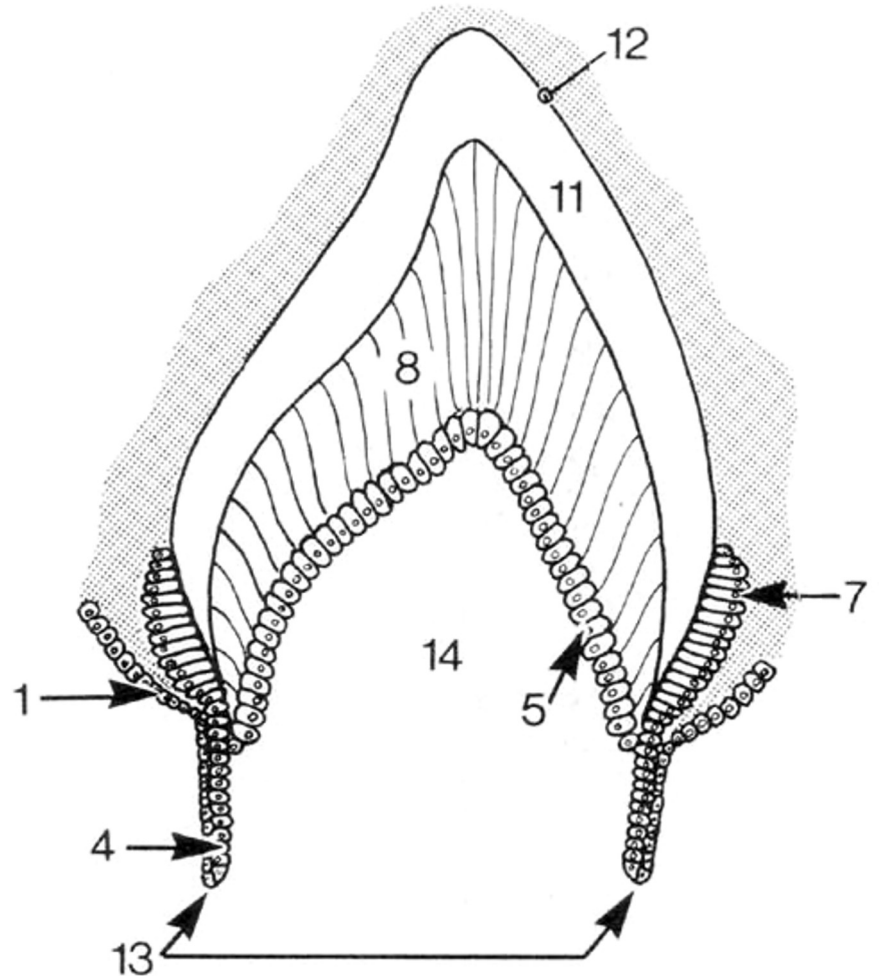
Hertwig's rodepitelskede



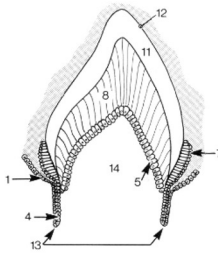
- Dannes ved forlængelse af:

- Ydre emaljeepitel
- Indre emaljeepitel

- NB: stratum reticulare & stratum intermedium mangler

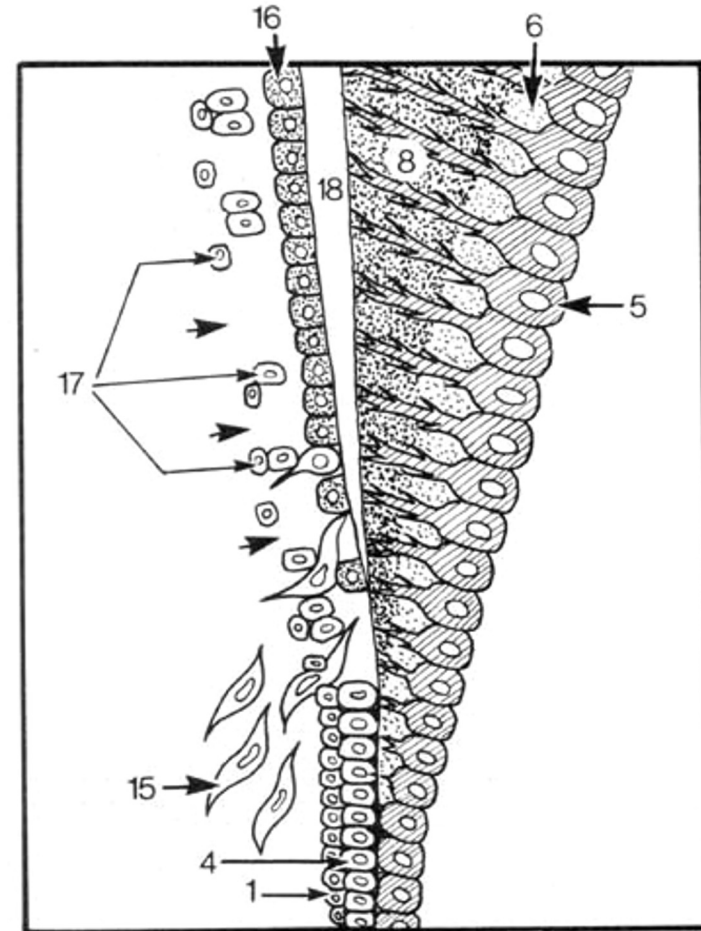


Hertwig's rodepitelskede

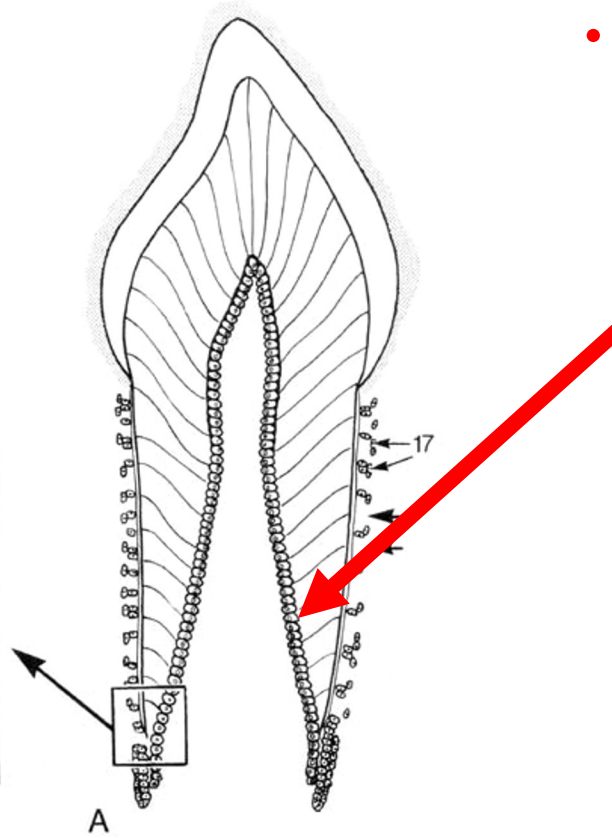
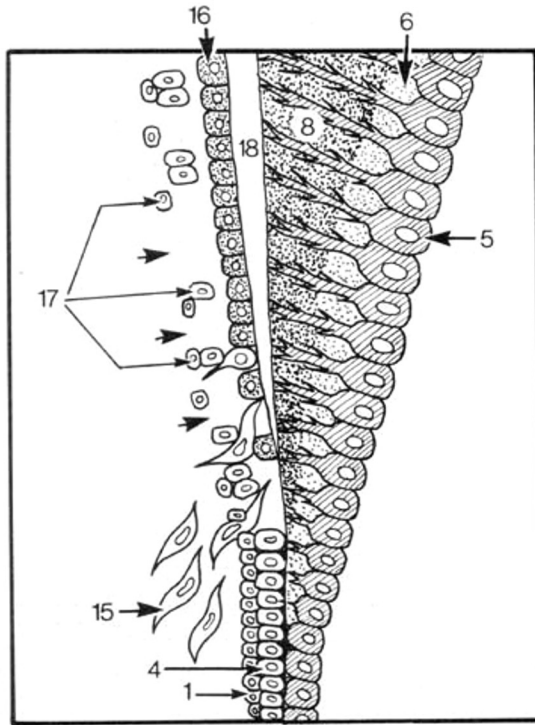
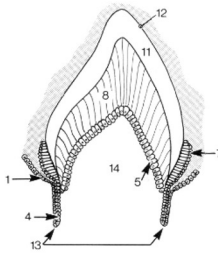


Inducerer:

- differentiering af odontoblaster
- der dannes dentin på inder-siden af skeden

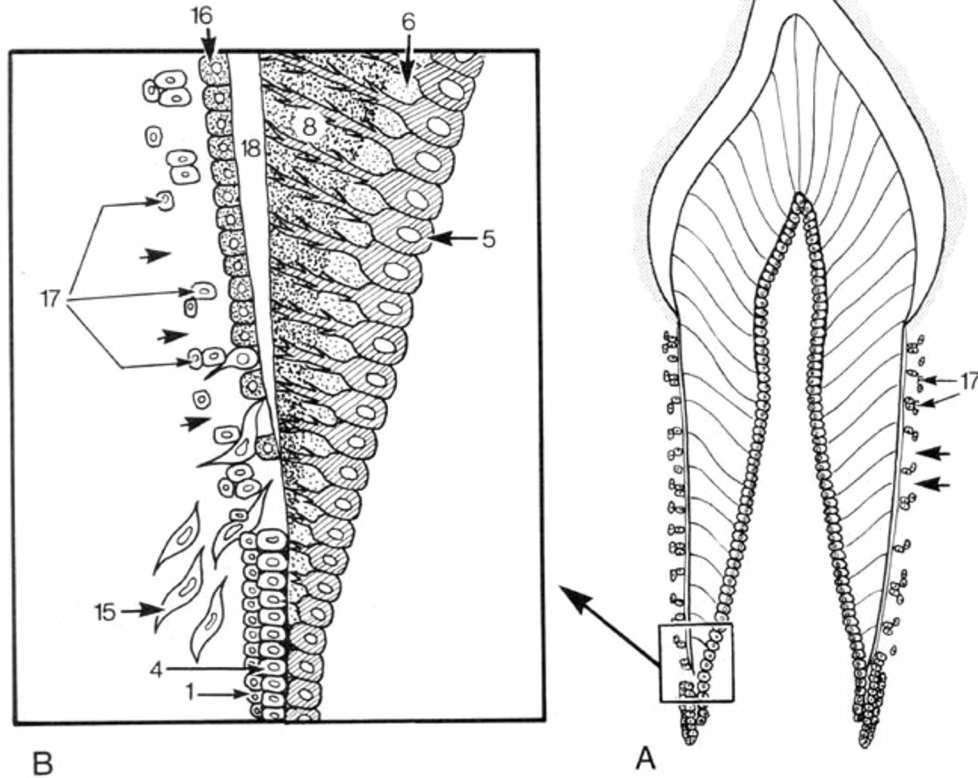
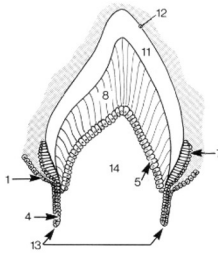


Hertwig's rodepitelskede



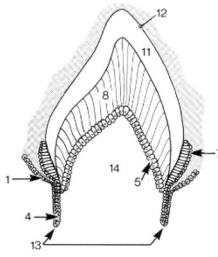
- **dentin, prædentin og odontoblast-laget** forlænges i apikal retning

Hertwig's rodepitelskede

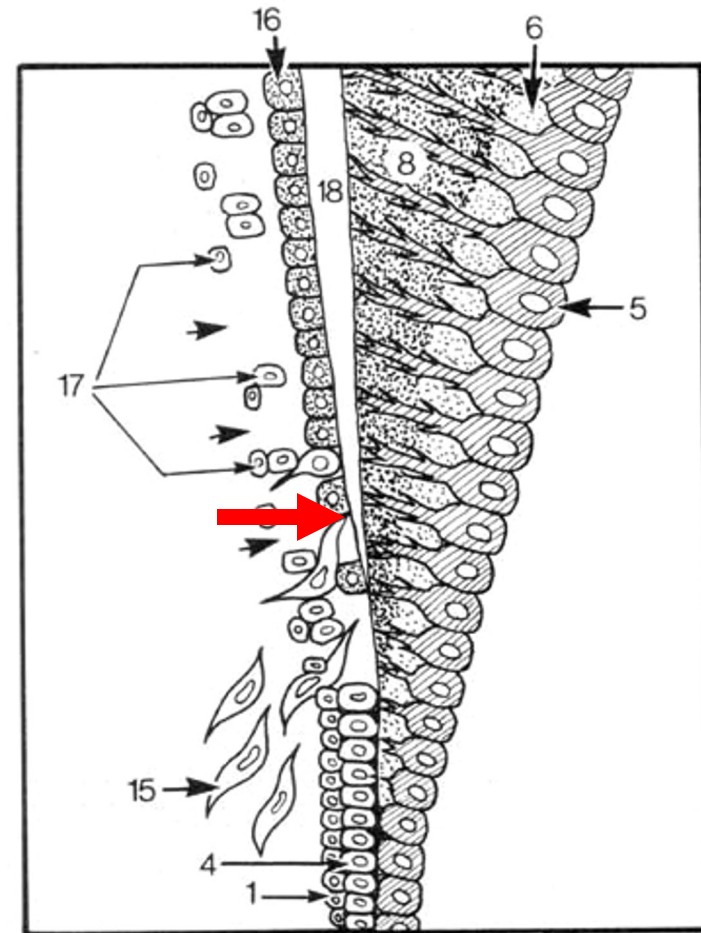


- **bindevævs-celler** er vokset ind fra ydersiden
- ..der hvor der er dannet dentin

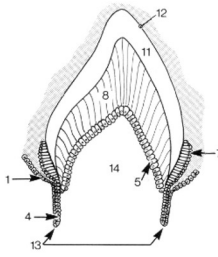
UDVIKLING AF ROD



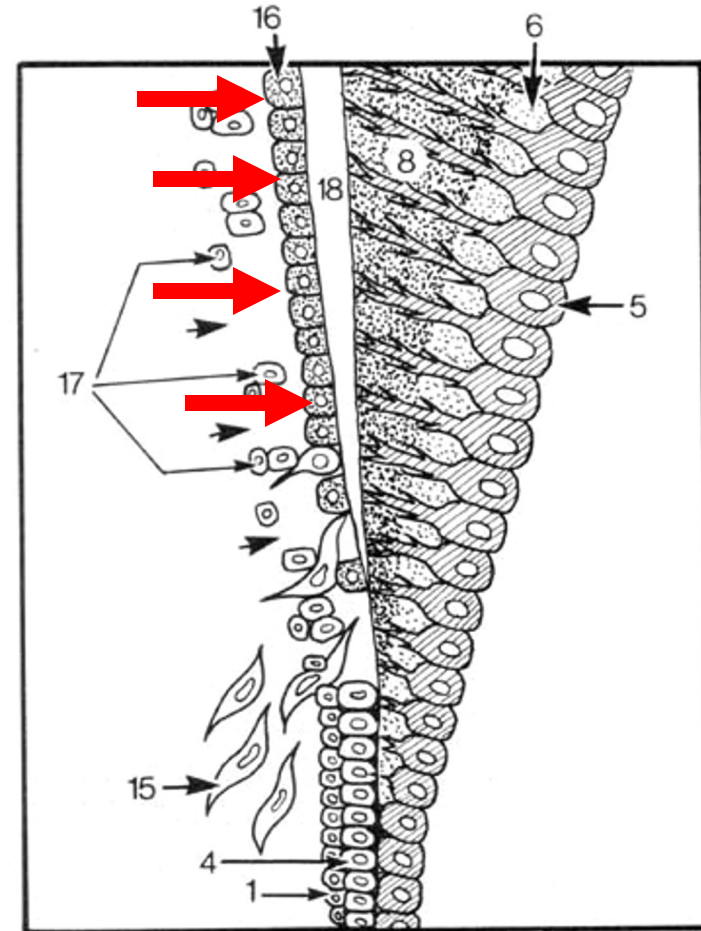
- **bindevæv** fra den omkringliggende tandsæk gennemhuller det ydre og indre emaljeepitel fra ydersiden og når ind til dentinen



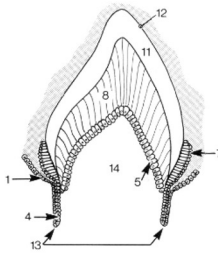
UDVIKLING AF ROD



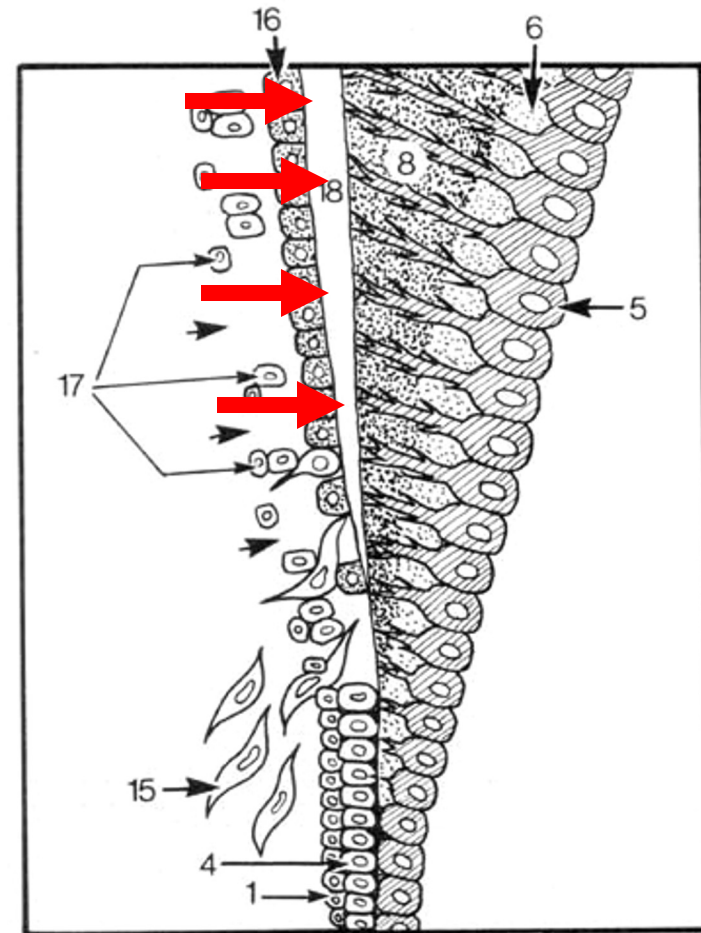
- bindevævs-celler (stamceller/progenitorceller) differentierer til **cementoblaster**, der aflejrer sig på dentinen



CEMENT

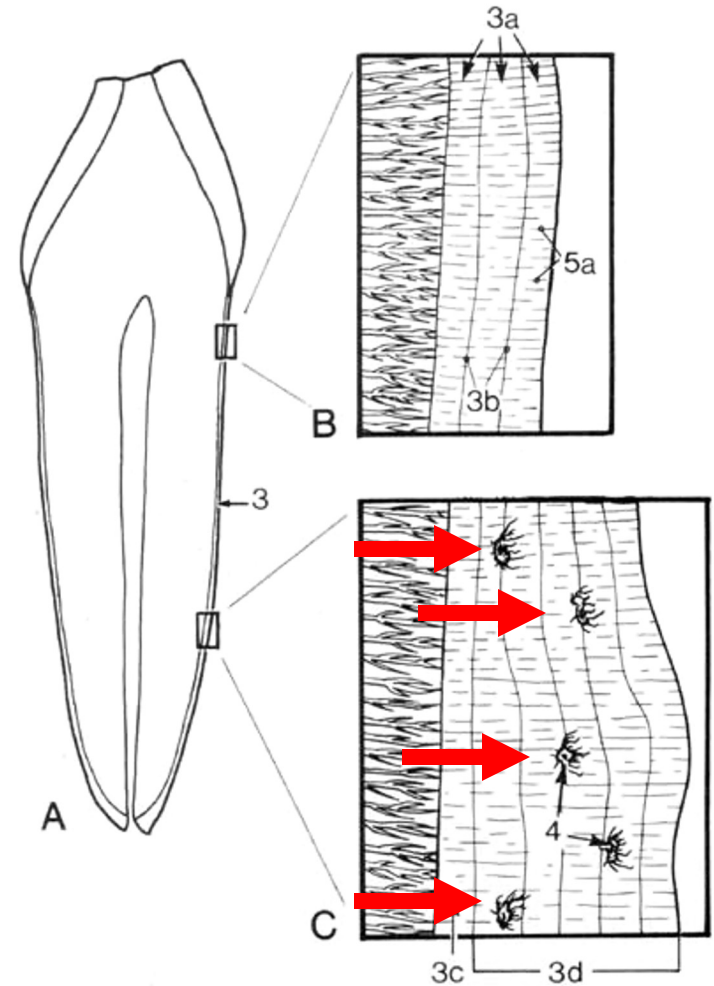
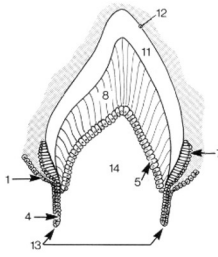


- cementoblaster danner **cement** på overfladen af roddentin



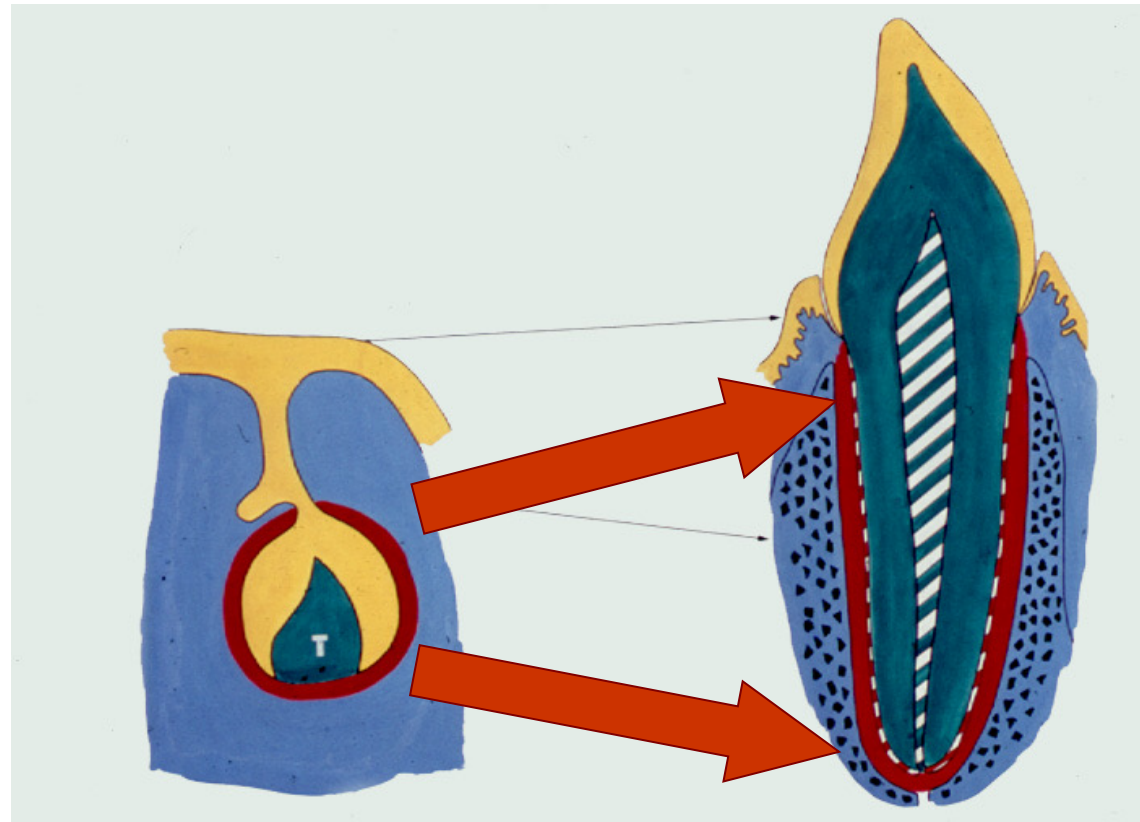
CEMENT

- enkelte celler indlejres i cementlaget og bliver til **cementocytter**



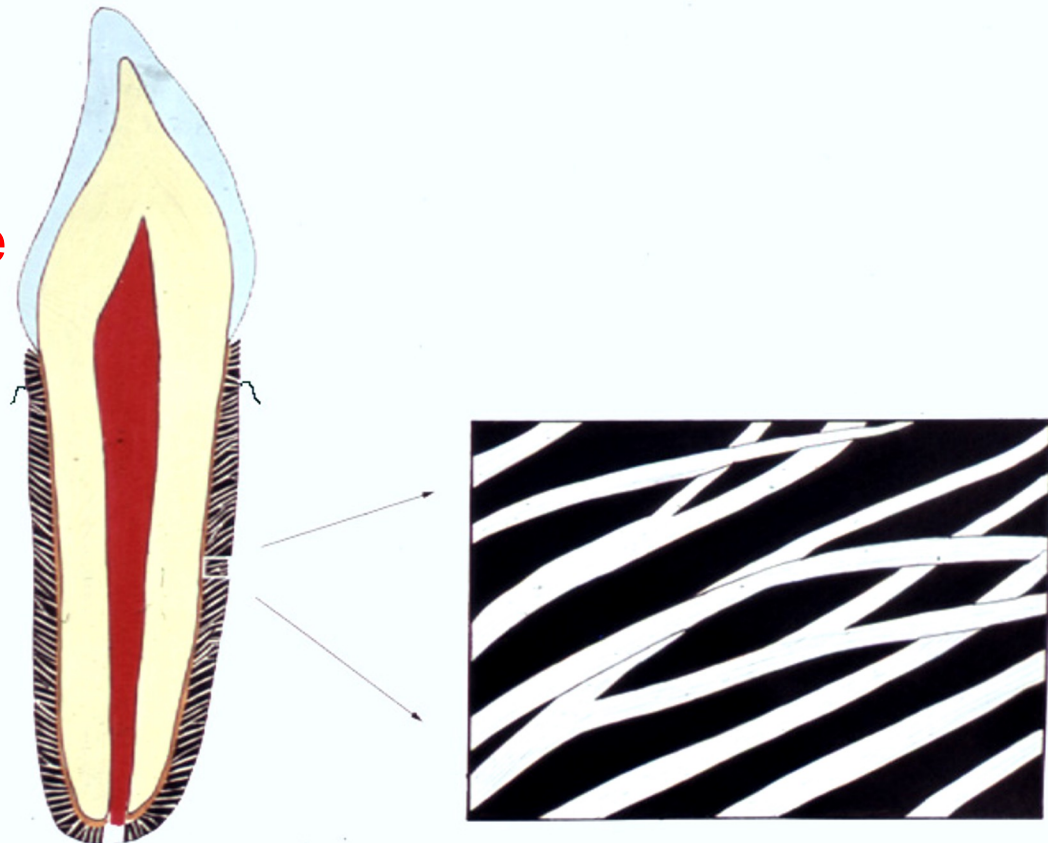
RODHINDEN

- udvikles fra
tandsækken



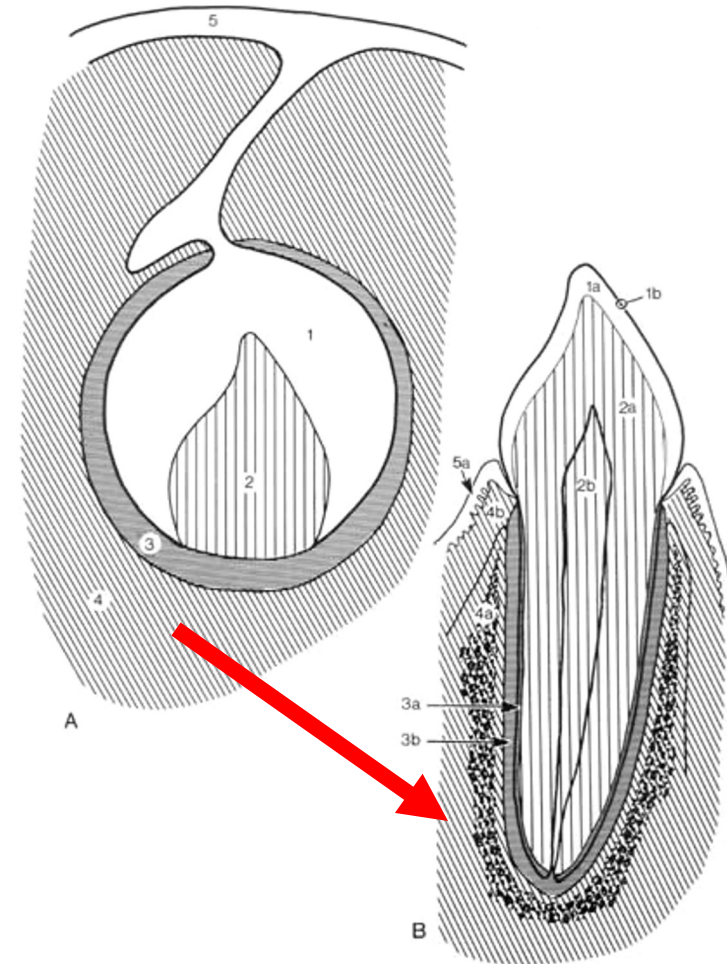
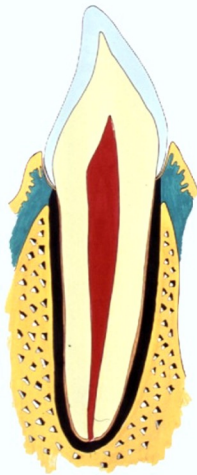RODHINDEN

- udvikles ved om-organisering af bindevæv og heriblandt **kollagene fibriller**



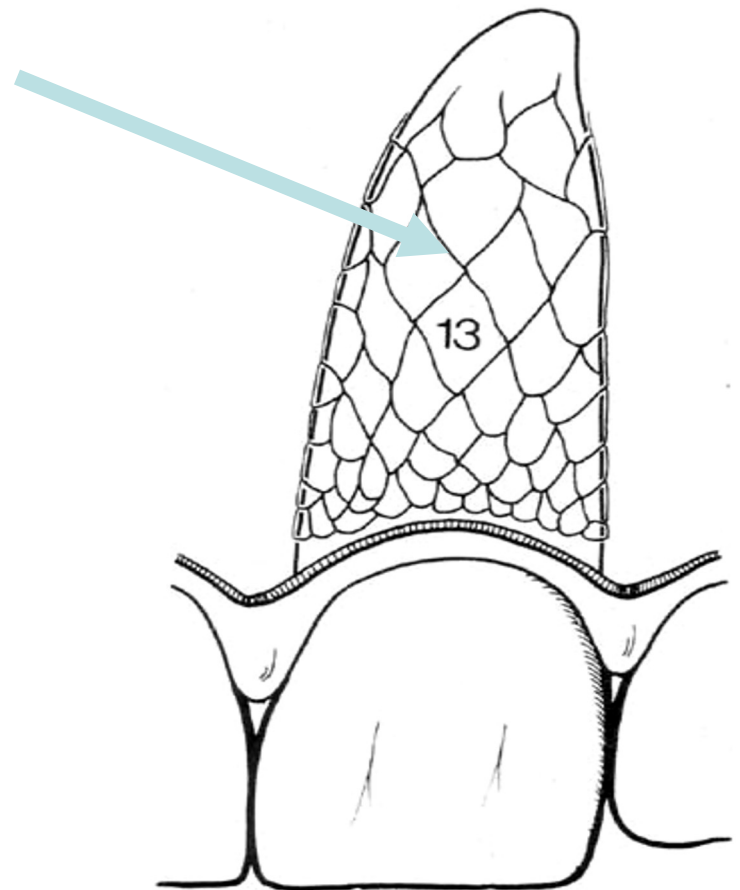
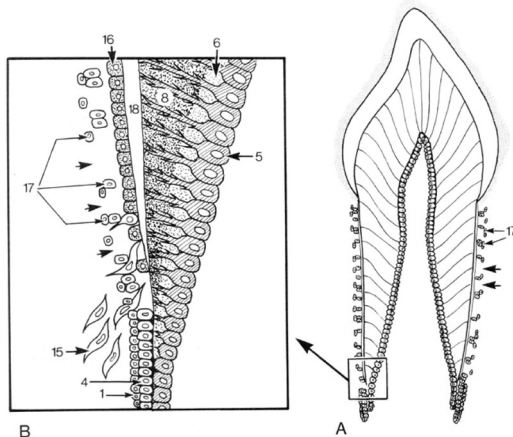
ALVEOLEKNOGLEN

- bindevævs-
præformeret

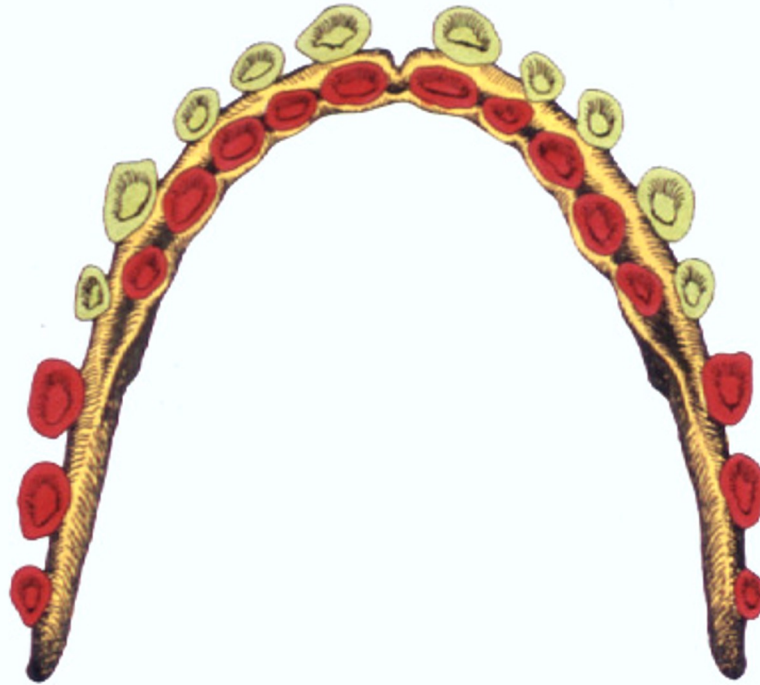


Malassez epiteløer

- er rester fra rodepitelskeden
- ligger i rodhinden



5. ERSTATNINGSTANDLISTER OG TILVÆKSTLISTE



Mælketandsæt med nye tænder på vej

Db-42/9-21-22-23

TANDSÆT

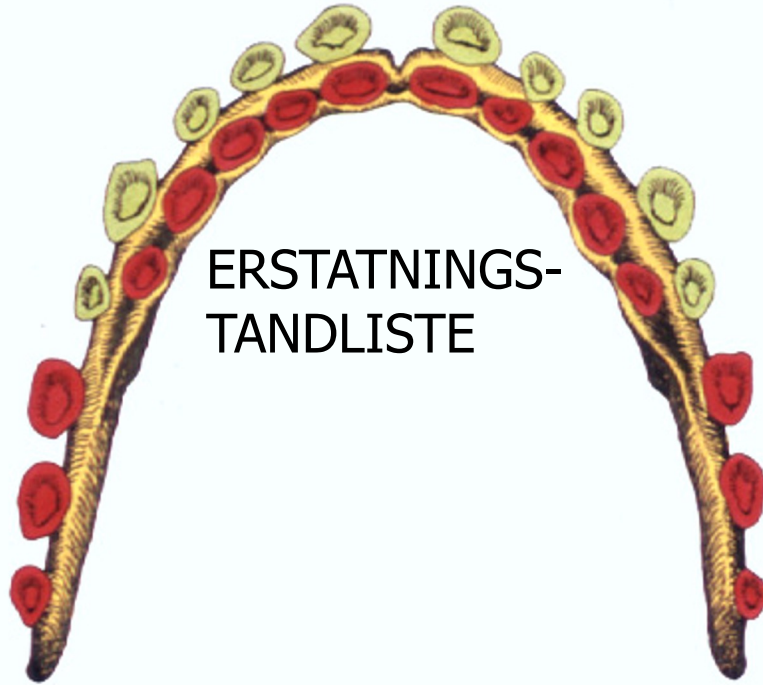
- 20 mælketænder
 - også kaldet ”det temporære tandsæt”
- Ca 32 blivende tænder
 - også kaldet ”det permanente tandsæt”

LISTER

TANDLISTE

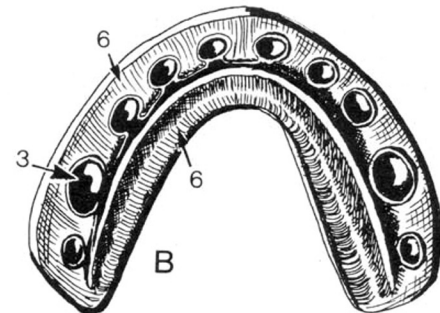
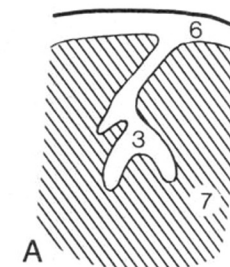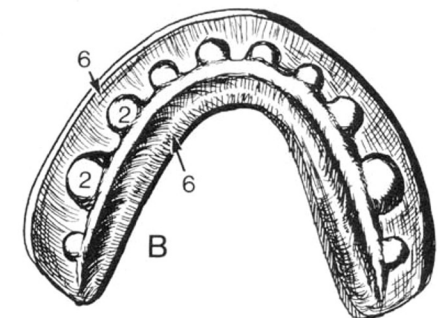
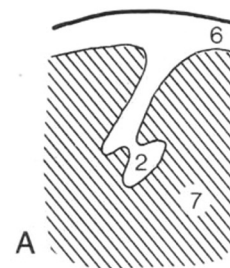
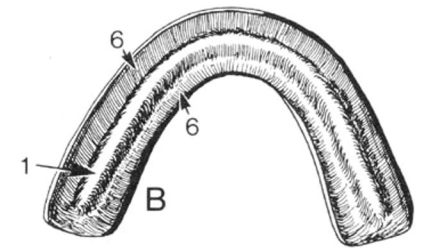
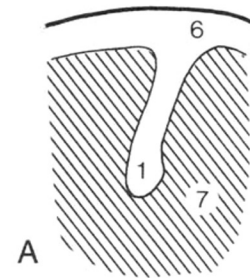
ERSTATNINGS-
TANDLISTE

TILVÆKSTLISTE



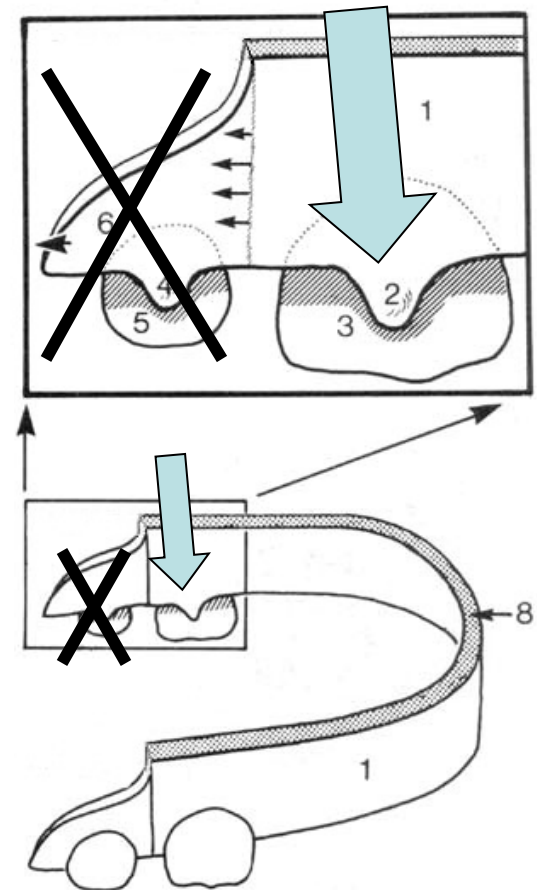
TANDLISTE

- Mælketænder udvikles fra tandlisten
- 10 mælketænder i hver kæbe:
 - 4 mælkefortænder
 - 2 mælkehjørnetænder
 - 4 mælkekindtænder



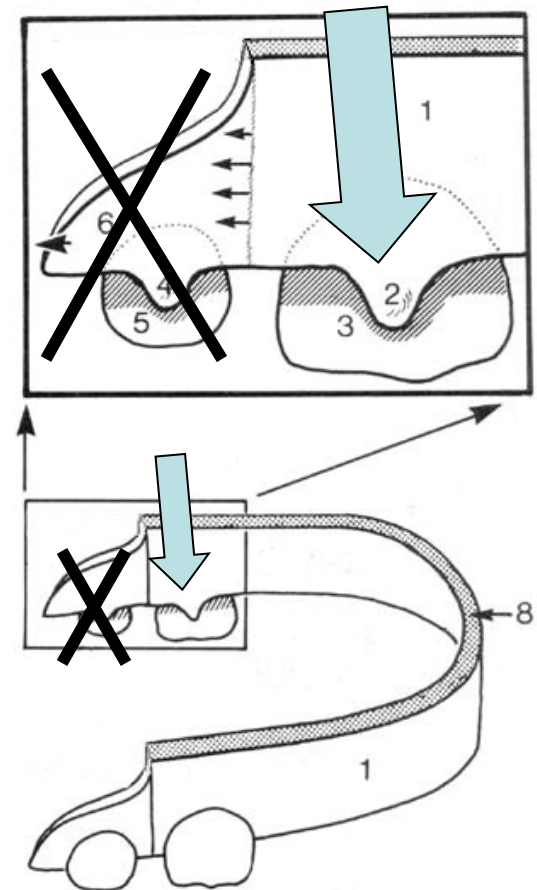
ERSTATNINGSTANDLISTER

- Nogle af de blivende tænder udvikles fra erstatningstandlister



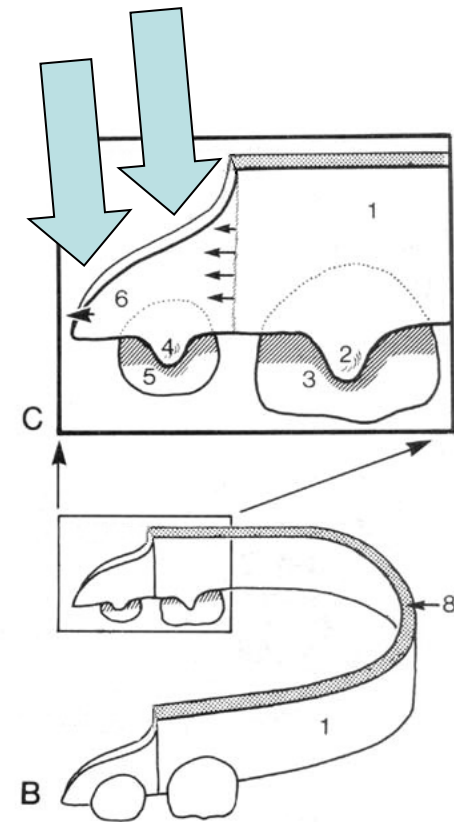
ERSTATNINGSTANDLISTER

- De blivende tænder udvikles fra erstatningstandlister
- ialt 20 blivende tænder udvikles oralt for mælketænderne



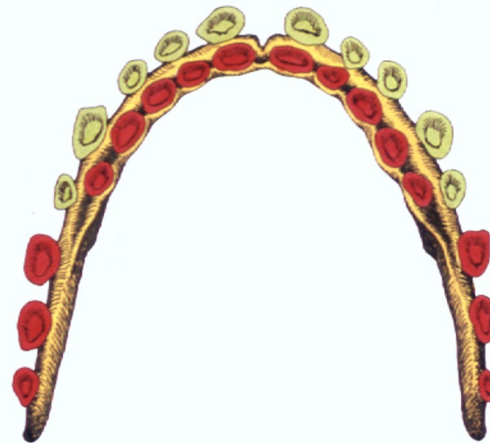
TILVÆKSTLISTE

- Op til 3 permanente kindtænder udvikles fra frie kant i hver kæbehalvdel
- ialt ca op til permante tænder udvikles fra tilvækstlisten (som primære tænder)



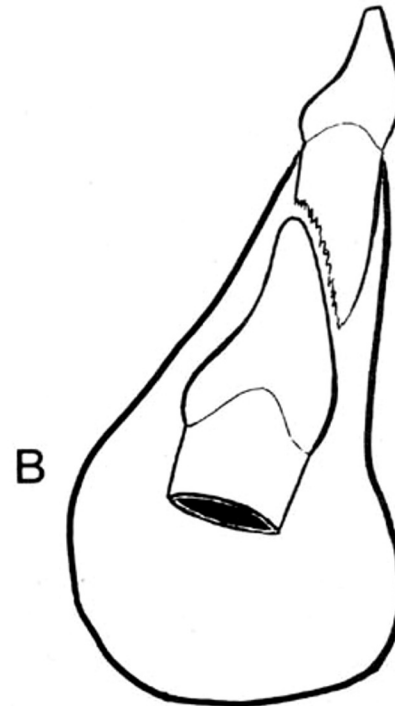
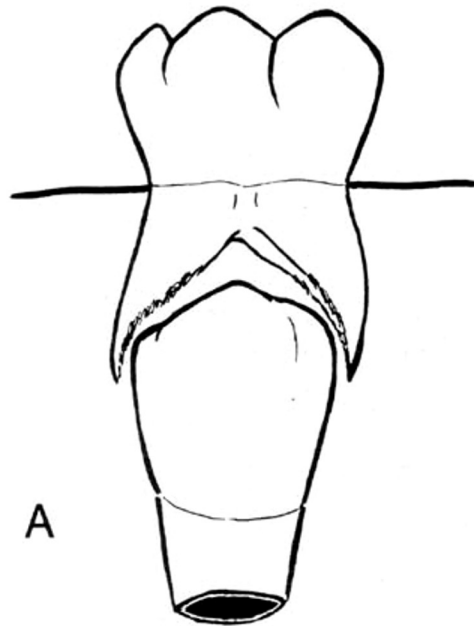
TANDSÆT

- 20 mælketænder
 - 20 primære tænder
- Op til 32 blivende tænder
 - Op til 12 primære tænder
 - 20 sekundære



ERUPTION

- blivende tænder erstatter mælketænder
- resorption af mælketændernes rødder



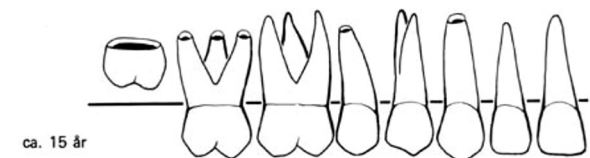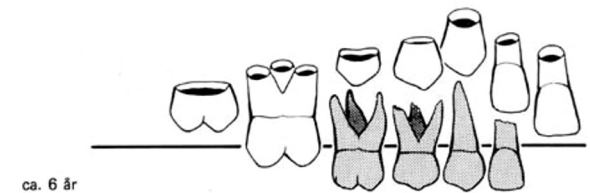
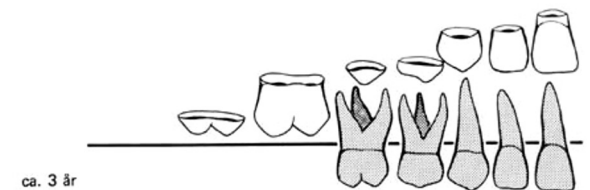
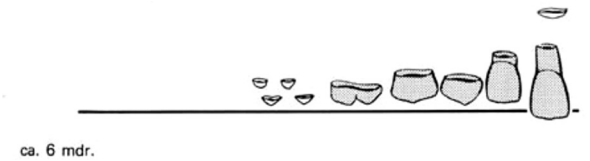
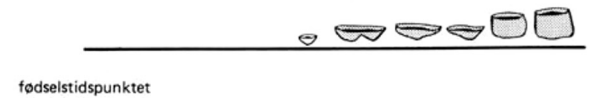
“Serres perler”

- epitel-rester fra tandlisten
- nb: epitel-øer kan udvikle cyster

6. MINERALISERING OG FREMBRUD

FØR FØDSEL

- mælketænder og permanente første molar begynder at mineralisere

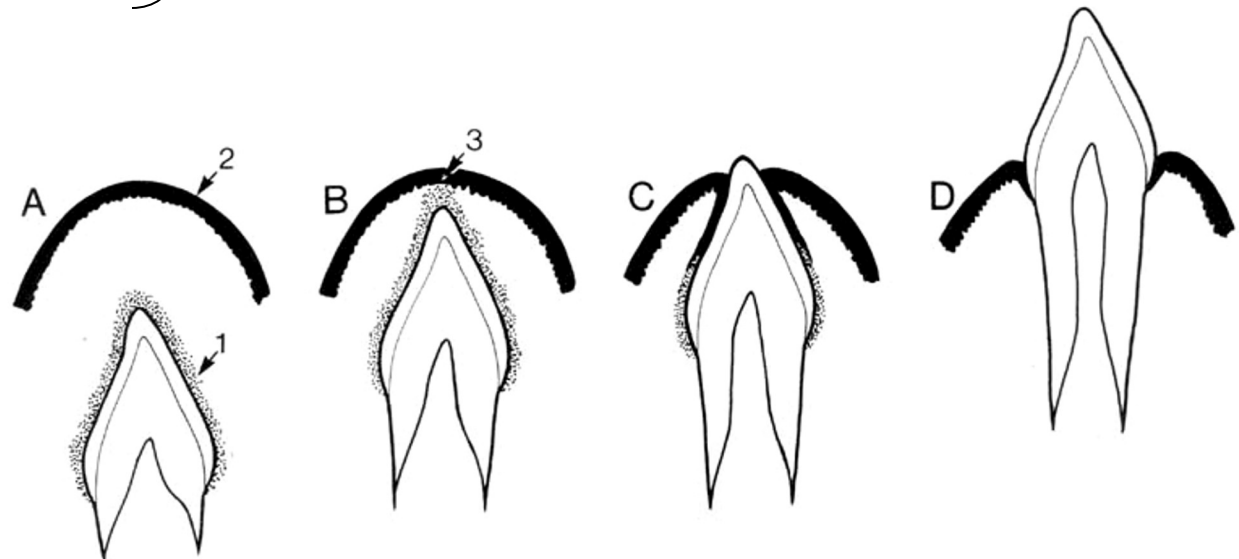


REDUCEREDE EMALJEEPITEL

Emaljeorgan

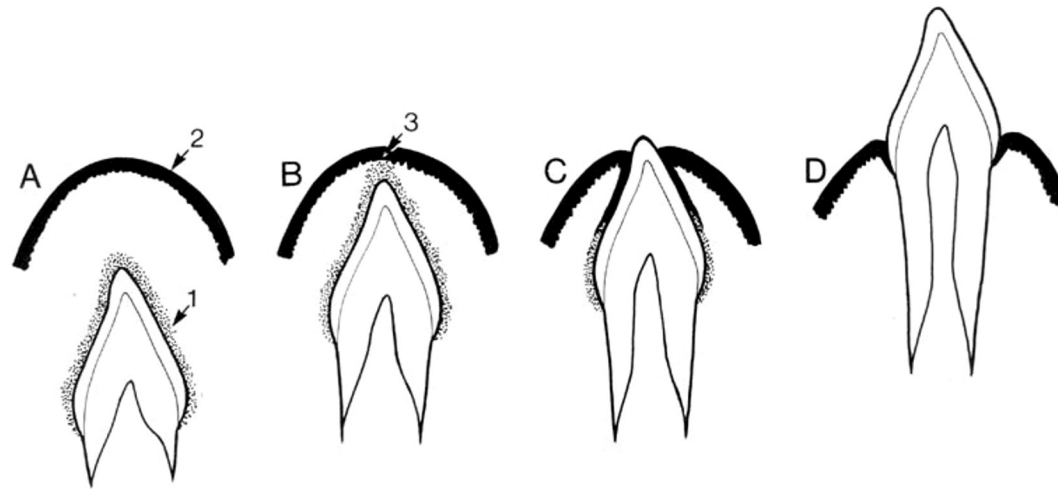
Emaljehinde

Reducerede emaljeepitel



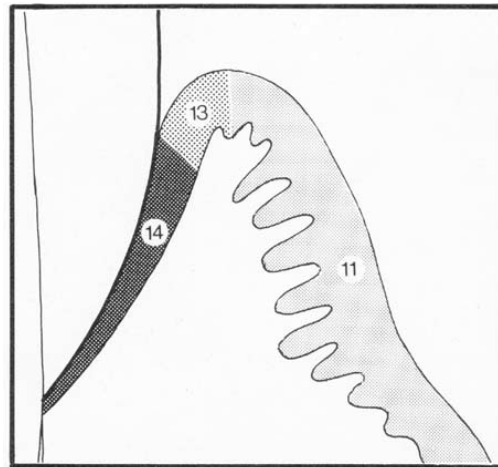
REDUCEREDE EMALJEEPITEL

- smelter sammen med mundhuleepitel



REDUCERED E MALJEEPITEL

- bliver til sulcusepitel og kontaktepitel



Slut



HL, TA, IOOS, AU